

Leading Article

Pathology of gastro-oesophageal reflux disease and its complications

Chandrasoma PT

Normal anatomy

The oesophagus is a tubal structure that extends from the proximal limit of the upper oesophageal (crico-pharyngeal) sphincter to the distal limit of the lower oesophageal (cardiac) sphincter. Its entire length is lined by squamous epithelium. The oesophagus has cervical, mediastinal and abdominal components, traversing the thoracic inlet and the diaphragmatic hiatus. The proximal 2-3 cm of the oesophagus consists of the upper sphincter. The distal 4-5 cm of the oesophagus consists of the lower sphincter, which straddles the diaphragm, having a thoracic and abdominal segment. The entire 2-3 cm of the abdominal oesophagus distal to the diaphragmatic hiatus is the abdominal segment of the lower oesophageal sphincter. The lower sphincter is impossible to identify accurately by gross examination or endoscopy. It is likely that the pressure created is the result of a complex anatomical arrangement of the sling fibers of the muscle that extends distal to the pressure zone into the stomach (1). The oesophagus normally ends at the gastro-oesophageal junction where the normal tubal oesophagus flares to become the sac-like stomach. This point is marked externally by the reflection of the parietal peritoneum from the inferior surface of the diaphragm to the viscera. The stomach is entirely covered by peritoneum. The abdominal oesophagus has a cone shaped mass of connective tissue

that separates it from the peritoneum as it reflects off the diaphragm to the gastro-oesophageal junction. This connective tissue contains the superior and inferior phreno-oesophageal ligaments that fix the oesophagus loosely to the diaphragmatic hiatus (2). The normal gastro-oesophageal junction can be defined anatomically at gross examination by the point at which the tube flares into the sac and the point of the peritoneal reflection. The flare is maximal on the greater curvature where the fundus of the stomach moves sharply upward from the junction to reach the under-surface of the diaphragm, creating the acute angle of His.

Normal physiology

The two sphincters at the upper and lower ends of the oesophagus are normally tonically contracted and maintain a high resting pressure. This prevents air entering the upper oesophagus during breathing and gastric contents refluxing into the lower oesophagus at all times. The lower esophageal sphincter has a mean resting pressure of 15-20 mm Hg, this pressure is maximal in the central part of the sphincter and tails off on either side of the sphincter. The function of the oesophagus is to transmit ingested food (solid and liquid) that has been processed in the mouth by mastication and salivary secretion to the stomach. This is accomplished by an involuntary swallowing reflex that begins when the bolus of

Correspondence: Chandrasoma P, Professor of Pathology, Keck School of Medicine, University of Southern California, Losangeles, California, USA. e-mail: ptchandr@usc.edu

prepared food is pushed voluntarily into the pharynx by the oral cavity and tongue. The swallowing reflex is co-ordinated in the brain stem and effected by the innervations of the pharyngeal and esophageal muscles, largely by the glossopharyngeal and vagal cranial nerves.

The initiation of the swallowing reflex results in the following events, (a) relaxation of the upper oesophageal sphincter, (b) initiation of the peristaltic wave in the oesophageal muscle, and (c) relaxation of the lower esophageal sphincter. The upper sphincter relaxation allows the food bolus to enter the oesophagus. The peristaltic wave propels the food bolus down the oesophagus and through the relaxed lower sphincter into the stomach. A normal swallow clears the food bolus with a single primary peristaltic wave. With a large bolus that does not traverse the whole length of the oesophagus, a secondary peristaltic wave develops to clear the oesophagus. The normal oesophageal peristaltic wave pressure varies in different parts of the oesophagus, but is in the 40-50 mm Hg range. Once the peristaltic wave traverses the distal oesophagus and the bolus of food enters the stomach, the lower sphincter which has remained relaxed from the time of initiation of the swallow, regains its tonic resting pressure, preventing reflux of gastric contents into the oesophagus. Since peristalsis pressurizes the oesophagus throughout the swallow, there is no reflux of gastric contents into the oesophagus during the swallow when the lower sphincter is relaxed.

It is as if the initiation of the swallow by the brain stem converts the lower pharynx, oesophagus and stomach to a sin-

gle open cavity with relaxed sphincters wherein the distal movement of the bolus of food is controlled by the co-ordinated muscular action of peristalsis. As the food bolus passes the sphincters, they regain their tonic pressure converting the oesophagus once again to its resting state where it is a closed compartment, physiologically separated from both pharynx and stomach.

Normal histology and histopathological changes caused by reflux disease

Physicians of all specialties have confused the interpretation of normal histology in this region for six decades. The confusion has prevented an accurate definition of the oesophagus, gastro-oesophageal junction and proximal stomach. It is incredible that in this time where we can identify single codons of single genes with great accuracy, we still do not have agreement as to where the oesophagus ends and the stomach begins. It is encouraging though, that evidence for these definitions have been presented and this review will present that evidence. The medical community is presently in a state of denial and resistance that will need to be overcome for the true definition of the oesophagus, gastro-oesophageal junction and proximal stomach to emerge and be accepted universally.

In 1950, Norman Barrett defined the oesophagus as "that part of the foregut that is lined by squamous epithelium." By this definition, the squamo-columnar junction was the gastroesophageal junction; everything distal to this was gastric (3). The histologists at the time defined this "gastric" mucosa as "cardiac" mucosa which came to line the proximal stomach.

Barrett's attempt at a histological definition of the end of the oesophagus was incorrect. In 1953, Allison and Johnstone disproved Barrett's definition; they provided evidence that, in some patients, the oesophagus extended distal to the squamocolumnar junction and was lined by columnar epithelium (4). This evidence was accepted by Barrett who, in 1957, coined the term columnar lined oesophagus (5). In the 1960s, the medical community recognized that columnar lined oesophagus was a pathological entity caused specifically by gastro-oesophageal reflux disease.

Importantly, the reversal of Barrett's histological definition of the oesophagus meant there was no longer, a way to define the oesophagus histologically. While there was proof, that part of the distal oesophagus could be lined by columnar epithelium, pathologists never shed the idea that some part of this oesophageal columnar epithelium represented proximal stomach or gastric mucosa in the oesophagus. Cardiac mucosa, which was proximal gastric mucosa by Barrett's definition of the oesophagus, continues to be regarded as proximal gastric mucosa today. This is incorrect, it can be shown that cardiac mucosa is metaplastic columnar oesophagus, belonging to the oesophagus. The recognition of this simple fact will lead to a new histological definition of the gastro-oesophageal junction.

From the early 1960s, the medical community recognized that columnar lined oesophagus was an entity caused by reflux disease. The definition of the proximal limit of the columnar lined oesophagus is easy, it is the squamocolumnar junction.

However, the definition of its distal limit, which is the gastro-oesophageal junction has always been, and still continues to be, a source of confusion. The definition of the end of the oesophagus in the past six decades to this day has been by gross examination as the distal limit of the tubal structure and by endoscopy as either the point of flaring of the tubal oesophagus or the proximal limit of gastric rugal folds.

Between 1961 and 1994, 2-3 cm of the distal oesophagus was believed, erroneously, to be lined by columnar epithelium (2). After 1994, when short segment Barrett oesophagus was recognized, it has been recognized that the entire oesophagus is lined by squamous epithelium (6). However, there is no evidence that the present gross (distal limit of the tube) and endoscopic (proximal limit of "gastric" rugal folds) definitions of the end of the oesophagus are accurate. As such, the statement that the "entire oesophagus is lined by squamous epithelium," while accurate, has no meaning because we cannot define the distal limit of the oesophagus accurately. This is a source of confusion that results in significant error.

In 1976, Paull et al reported that three epithelial types were present in columnar lined oesophagus involving the body of the oesophagus proximal to the lower oesophageal sphincter (7). These were "gastric fundic-type," "junctional type" and "specialized" type. We have simplified the criteria and terminology for defining these three epithelial types and define the following three epithelial types (Figure 1) in this region based on the presence of three cell types, mucous, parietal and goblet cells, (a) oxyntocardiac epithe-

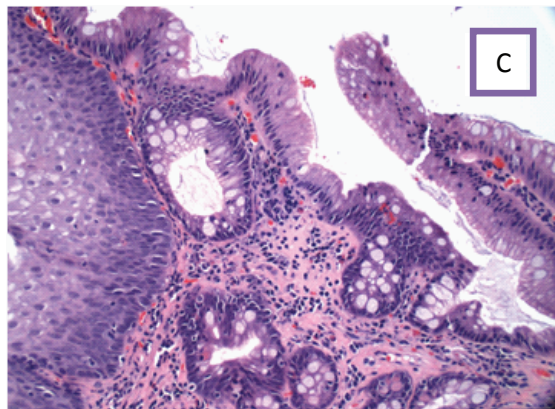
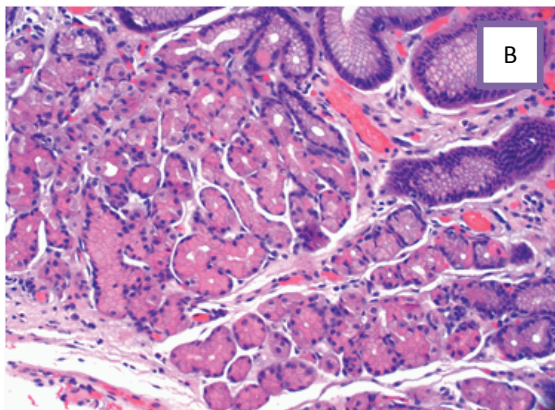
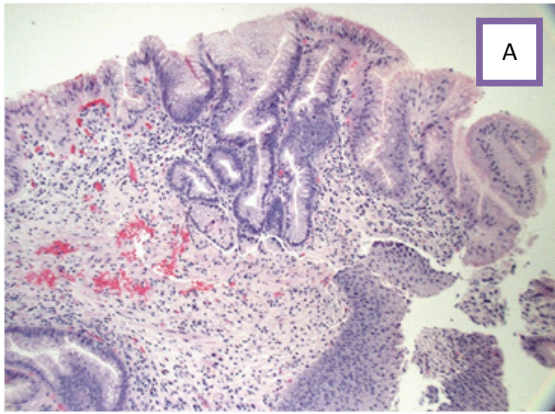


Fig 1. Epithelial types in the squamo-oxyntic gap

- A - Cardiac mucosa - only of mucous cells without parietal or goblet cells
- B - Oxyntocardiac mucosa – a mixture of mucous and parietal cells
- C- Intestinal metaplasia- cardiac mucosa with goblet cells

lium(= “gastric-fundic type”) where the glands contain a mixture of mucous and parietal cells; (b) cardiac epithelium (= “junctional type”), composed only of mucous cells without parietal or goblet cells, and (c) cardiac mucosa with goblet cells (= “specialized type”) which defines intestinal metaplasia of the oesophagus (8). Other cell types such as neuroendocrine cells, chief cells, Paneth cells, pancreatic acinar cells are not relevant in the definition. The definition of these three epithelial types is so simple that it requires very little training for a pathologist to accurately recognize them and there is no significant inter observer variation between pathologists after this initial minimal training. The definition of the epithelial type is applied to a unit of the epithelium which is a single foveolar gland complex. Therefore more than one of these epithelia can be present in one small biopsy piece.

Accurate definition of these three epithelial types in columnar lined oesophagus did not solve the problem of defining the end of the oesophagus histologically. With recognition of short segment Barrett oesophagus in 1994, it was clear that these same three epithelial types involved the region of the tubal oesophagus associated with the lower oesophageal sphincter. With the present gross (distal limit of tube) and endoscopic (proximal limit of rugal folds) definitions of the end of the oesophagus, these same three epithelial types were also seen up to 3 cm distal to these two points in what was and is believed to be the proximal stomach (“gastric cardia”). As such, these histological types could not be used to separate the oesophagus from the proximal stomach.

This is the presently accepted state of the art. The gastro-oesophageal junction is defined at a gross level as the end of the tube and at an endoscopic level as the proximal limit of gastric rugal folds. Based on this, oxyntocardiac epithelium and cardiac epithelium with or without intestinal metaplasia is believed to extend distally from the gastro-oesophageal junction to up to 3 cm in the proximal stomach (the “gastric cardia”). In a patient who has no visible columnar lined oesophagus at gross examination and endoscopy, the presence of these three epithelial types represents “normal gastric cardia” unless there is intestinal metaplasia or adenocarcinoma when it represents “intestinal metaplasia of the gastric cardia” and “adenocarcinoma of the gastric cardia” respectively. While evidence to the contrary exists, the most recent guidelines of the expert panel of the American Gastroenterological Association published recently reiterate this accepted state of the art (9).

In 1990, Tom DeMeester and his oesophageal surgery group joined the Keck School of Medicine at the University of Southern California and we developed a team that investigated oesophageal diseases at a clinical, physiological and pathological level. The basis of this investigation was a complete clinicophysiological evaluation (which included 24-hour pH studies in most patients) correlated with systematic biopsies that were done on every patient undergoing endoscopy, including patients who were endoscopically normal. The biopsy protocol included biopsies of the antrum and body of the stomach, retrograde biopsies at and distal to the proximal limit of rugal folds, and antegrade biopsies from the oesophagus

from the rugal folds to the squamocolumnar junction. When there was a visible columnar lined oesophagus, four quadrant biopsies were taken at 1-2 cm intervals. The biopsy at the squamocolumnar junction straddled the junction so that the transition of squamous epithelium to columnar epithelium was present in one piece (10). Over the past two decades and over 15,000 patients, we have produced a body of evidence that show that presently accepted definitions of the oesophagus, gastro-oesophageal junction, proximal stomach and the interpretation of histological findings in the region are incorrect. The solution to the confusion lies in the use of histology to define anatomic and pathologic entities rather than gross examination and endoscopy.

Histological examination of the oesophagus and proximal stomach in all patients shows the presence of a variable gap between the distal limit of squamous epithelium and the proximal limit of gastric oxyntic mucosa. Gastric oxyntic mucosa is defined as an epithelium characterized by the presence of straight tubular glands composed of parietal and chief cells. There are no mucous cells in the glands under the foveolar neck region. Normal gastric oxyntic mucosa can be differentiated from cardiac mucosa which lacks parietal cells and from oxyntocardiac mucosa by the fact that in the latter, the glands under the foveolar pit are lobulated, disorganized and associated with chronic inflammation and that the glands contain a mixture of mucous and parietal cells. We have designated this gap between squamous epithelium and gastric oxyntic mucosa as the squamo-oxyntic gap (11).

In an abstract presented in 1994 and a paper published in 1997, we showed that the presence of oxyntocardiac +/- cardiac epithelia in a biopsy taken from endoscopically normal patients correlated significantly with the presence of lower esophageal sphincter abnormalities and abnormal gastro-oesophageal reflux as shown by a 24-hour pH test (12). This has been confirmed, Glickman et al showed that 55% of children with a measured cardiac epithelial length greater than 1 mm had more significant reflux than 21% of children with a cardiac epithelial length less than 1 mm (13). These data provide strong evidence that the presence of any oxyntocardiac +/- cardiac epithelia in the squamo-oxyntic gap represents an abnormality caused by reflux disease. These epithelia are neither "normal" nor "gastric."

In 2000, we reported our findings in a "normal" autopsy population ("normal" in the sense that they had no clinical evidence of gastroesophageal reflux disease in their lifetime) (14). We examined the entire circumference of the squamocolumnar junction in 18 patients and showed that the squamo-oxyntic gap in these patients ranged from zero to 0.875 mm. Over half of the patients did not have cardiac mucosa and in half of the patients, at least one part of the circumference of the squamo-columnar junction showed a direct transition of squamous epithelium to gastric oxyntic mucosa. This resulted in the conclusion that the normal state histologically was that the entire oesophagus was lined by squamous epithelium and the entire stomach proximal to the antrum was lined by gastric oxyntic mucosa. Oxyntocardiac and cardiac epithelium with or

without intestinal metaplasia represented metaplastic oesophageal columnar epithelium caused by reflux disease and not normal proximal gastric epithelia.

This conclusion correlated well with the observation that the presence of these epithelia was associated with the presence of clinical evidence of reflux, an abnormal 24-hour pH test and lower oesophageal sphincter abnormalities by manometry (12,15-17). The presence of oxynto cardiac and cardiac mucosa with or without intestinal metaplasia is a pathological state. The autopsy findings also suggested that small amounts of columnar lined oesophagus are almost universally present in patients in Los Angeles, indicating that reflux disease was present at a cellular level in virtually everyone in Los Angeles despite the absence of any symptoms. The situation was similar to atherosclerosis, which was almost universally present in adults undergoing autopsy in Los Angeles. Reflux disease, at least in Los Angeles, is one of the most common human diseases.

These data could now be used to develop histology based definitions that were different than the present definitions based on gross and endoscopic examination (8,18). These new definitions are as follows,

- (a) The oesophagus is that part of the foregut distal to the upper esophageal sphincter that is lined by squamous epithelium and metaplastic oesophageal columnar epithelia. The latter include oxynto cardiac epithelium and cardiac epithelium with or without intestinal metaplasia.
- (b) The stomach is that part of the foregut that is lined by gastric oxyntic mucosa proximally and antral mucosa distally.

(c) The gastro-oesophageal junction is the histological junction between oesophageal epithelium (squamous in normal people and metaplastic columnar epithelium in patients with reflux disease) and gastric oxyntic mucosa. The most accurate definition of the gastro-oesophageal junction is that it is the proximal limit of gastric oxyntic mucosa, defined by histology. The junction cannot be identified by gross or endoscopic examination because in patients with reflux, gastric oxyntic mucosa is not distinguishable from metaplastic columnar epithelia of the esophagus.

(d) Gastro-oesophageal reflux disease is an entity where damage to squamous epithelium by gastric juice has resulted in the development of metaplastic oesophageal columnar epithelium of oxyntocardiac, cardiac or intestinal types. For the first time in history, there is a histological method of recognizing reflux disease in its mildest and earliest stage which is often asymptomatic.

(e) Barrett oesophagus is the presence of intestinal metaplasia in the squamo-oxyntic gap.

It should be recognized that these histological definitions, though proven by evidence, have not yet been accepted by the medical community. While these definitions are closer to acceptance now, it will still take several years for them to become a mainstream concept that is accepted and applied universally in the management of patients. Until such time, the transition from confusion to clarity will occur slowly although inexorably.

The histological squamo-oxyntic gap

Defining reflux disease histologically opens the door to new methods of looking at the disease. Such a cellular understanding of reflux provides more profound insights to causation, progression and the impact of treatment.

(a) Columnar metaplasia of oesophageal squamous epithelium

Squamous epithelium in the oesophagus constantly loses its surface cells and is replenished by the stem cells and proliferative cells in the basal and supra-basal region. Squamous differentiation is dictated by the presence of an activated Wnt genetic signal in the proliferating cells. In an epithelium in balance with a normal rate of surface cell loss, the epithelium is flat with short papillae and a basal layer thickness of less than 20% of the epithelium. With a Ki67 stain, the proliferative zone is 2-3 cell layers thick in the supra basal region. When the squamous epithelium is exposed to gastric juice, the acid in the gastric juice causes damage. Cell loss at the surface increases, the proliferative zone undergoes hyperplasia (basal cell hyperplasia and increased Ki67 expression in the supra-basal region), and the papillae elongate, and become more vascular. Acid also damages tight junctions between cells, causing them to separate (intercellular edema; spongiosis or “dilated intercellular spaces”). Cell damage generates cytokines that attract eosinophils into the epithelium. With severe damage, erosion of the epithelium occurs. An important result of damage to the cell junction is increased permeability of the squamous epithelium. Previously impermeable to luminal molecules, the acid-damaged squamous epithelium now allows the entry

of increasingly large molecules.

With severe damage, these molecules reach the proliferative zone and interact with the membranes of the dividing cells. An unknown molecular interaction between a luminal molecule and a cell surface receptor causes the genetic differentiating signal to change from the Wnt signal that dictates squamous differentiation to one (possibly bone morphogenesis protein 4 – BMP4) that dictates columnar differentiation. This causes columnar metaplasia of the squamous epithelium. The first epithelium to result from metaplasia is one without differentiated cells consisting only of mucous cells. This is cardiac epithelium.

(b) The length of the squamo-oxyntic Gap

In a person who has mild asymptomatic reflux disease, the squamo-oxyntic gap is what is seen at autopsy. It ranges from zero to less than 1 cm in length. In over half of the patients, it consists of only oxyntocardiac mucosa. Intestinal metaplasia is rare. In over half of the patients, some part of the circumference of the squamo-columnar junction shows a direct transition from squamous epithelium to gastri oxyntic mucosa. The length of the gap increases with age. This is the baseline.

In patients who have clinical reflux disease, the squamo-oxyntic gap lengthens progressively depending on the severity of reflux disease. In maximal disease, the entire oesophagus up to the upper oesophageal sphincter can convert to columnar epithelium. While this is rare, it is not uncommon for columnar lined oesophagus to extend to the mid-oesophagus for total lengths of 10-15 cm.

There is evidence that the length of columnar lined oesophagus has decreased in the past 50 years in the reflux population, probably because of the widespread availability of potent acid suppressive drugs which limit acid-induced columnar metaplasia of the squamous epithelium. The length of columnar lined oesophagus is the best indicator of the cumulative damage resulting from reflux disease through the patient's lifetime. Progression of reflux disease during a person's lifetime is best assessed by increasing length of the squamo-oxyntic gap. However, the impact of treatment with acid suppressive drugs prevents utilization of this criterion. In treated patients, the best assessment of progression is by increasing damage to the lower esophageal sphincter.

The length of the squamo-oxyntic gap progressively increases, usually beginning in childhood, from zero to its length at the time of discovery or, in a patient without clinical disease, to the time of death. If discovered during life and the patient is treated for reflux with acid suppressive drugs, the squamo-oxyntic gap tends to remain constant in length with neither significant elongation nor regression. This static length is probably the result of acid suppressive treatment which both prevents further acid-induced columnar metaplasia of squamous epithelium and does not reverse existing columnar metaplasia. It should be recognized, however, that while the length of the squamo-oxyntic gap does not change, there can be dramatic changes in the relative amounts of the three epithelial types within the squamo-oxyntic gap. Because these are identical at gross and

endoscopic examination, any such change can be seen only by histology.

(c) Temporal evolution of cardiac epithelium

The first epithelium to develop when squamous epithelium undergoes columnar metaplasia is one with only mucous cells and devoid of any differentiated cells. With time, and under the influence of exposure to gastric juice bombarding this epithelium intermittently during reflux episodes, the cardiac mucosa develops new genetic differentiating signals that result in a variety of differentiated cells appearing in it. These include, in various people, parietal cells, chief cells, goblet cells, Paneth cells, neuroendocrine cells, and ciliated cells (rarely). Of these, parietal cells and goblet cells have recognized significance and are used for defining columnar epithelial types. The development of parietal cells in cardiac epithelium results in oxyntocardiac epithelium. This is most likely the result of an interaction between a luminal molecule in the refluxate and a receptor on the cardiac epithelial stem cell membrane that causes activation of Sonic Hedgehog gene. This is an important embryonic signaling gene that is responsible for normal gastric epithelial differentiation and is powerfully expressed in normal stomach.

Development of goblet cells in cardiac epithelium results in intestinal epithelium. This is most likely the result of an interaction between a luminal molecule in the refluxate and a receptor on the cardiac epithelial stem cell membrane that causes activation of the homeobox CDX-2 gene. This is an important embryonic sign-

aling gene that is responsible for normal colonic epithelial differentiation and is powerfully expressed in normal colon.

Expression of these differentiated cell types is not uniform through the squamo-oxyntic gap, rather, it occurs in different regions. In some patients with a very short squamo-oxyntic gap, all three epithelial types can sometimes be seen in a single biopsy sample with intestinal epithelium in some foveolar complexes and parietal cells in others with some having only mucous cells. It is extremely unusual for a single foveolar complex to contain both parietal and goblet cells, i.e. oxyntocardiac mucosa almost never undergoes intestinal metaplasia.

(d) Distribution of epithelial types in the squamo-oxyntic gap

The three epithelia are distributed in the squamo-oxyntic gap in a highly ordered and non-random manner. All patients will have oxyntocardiac epithelium immediately proximal to gastric oxyntic mucosa. When the gap is very short as in the autopsy population, oxyntocardiac epithelium is frequently the only epithelium found. In patients with a gap length exceeding 1 cm, cardiac mucosa is almost always present. Intestinal metaplasia is present in a minority of patients and increases in prevalence as the gap length increases.

Intestinal metaplasia almost always occurs first in the most proximal region of the gap adjacent to the squamous epithelium. From this point it extends distally in the gap to a variable extent, usually without skip areas. The extent of intestinal metaplasia varies considerably among patients who have intestinal metaplasia in the gap.

Since Barrett oesophagus is defined by intestinal metaplasia, the amount of intestinal metaplasia within a segment of Barrett's oesophagus of given length can vary from a patient with one goblet cell to a patient in whom almost the entire length of the gap is intestinalized. Without histological mapping, such a difference between patients with Barrett esophagus will not be apparent.

(e) Prevalence of intestinal metaplasia in the squamo-oxyntic gap (Figure 2)

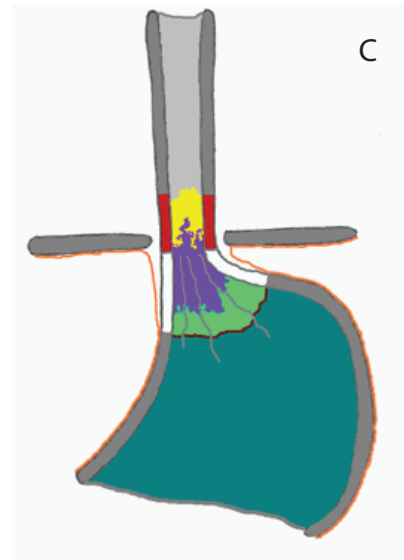
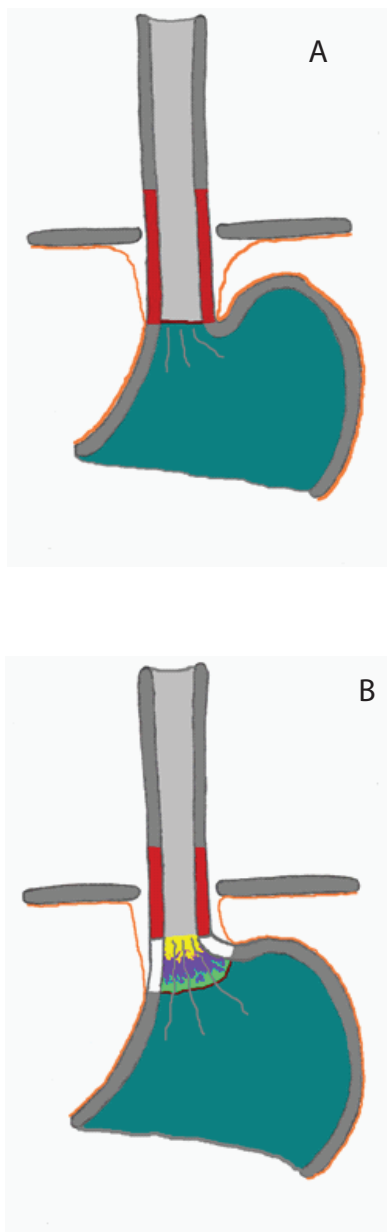


Fig 2. Gastro-oesophageal junctional region without reflux damage (A) and with squamo-oxyntic gaps of varying lengths (B and C). The normal part of the lower oesophageal sphincter is marked with red and the damaged part with white; the gastro-oesophageal junction is marked with a maroon line; gastric oxyntic mucosa is blue-green; squamous epithelium is grey. The metaplastic columnar epithelial types in the squamo-oxyntic gap are indicated as follows: oxyntocardiac mucosa is green, cardiac mucosa is purple and intestinal metaplasia is yellow. The peritoneal lining is marked with an orange line and rugal folds with grey lines.

a. A normal gastro-oesophageal junction with no squamo-oxyntic gap – no reflux damage. The oesophageal squamous epithelium directly transit into gastric oxyntic mucosa at the gastro-oesophageal junction marked by the peritoneal reflection, end of the tubular oesophagus and proximal ends of gastric rugal folds.

b. Gastro-oesophageal junction with short

squamo-oxyntic gap - early/mild reflux damage. The distal part of the lower oesophageal sphincter is damaged (white) and therefore, the distal oesophagus is dilated. The squamo-oxyntic gap is composed mainly of dilated distal oesophagus. The gastro-oesophageal junction here is the junction between oxyntocardiac mucosa and oxyntic mucosa (maroon line). The end of the tubular oesophagus and proximal limits of the gastric rugal folds no longer indicate the gastro-oesophageal junction. This stage is endoscopically normal.

c. Gastro-oesophageal junction with long squamo-oxyntic gap - late/severe reflux damage. The lower oesophageal sphincter is further damaged and the metaplastic epithelia have spread to the tubular oesophagus. The squamo-oxyntic gap is composed of dilated distal oesophagus + columnar lined part of the tubular oesophagus. Endoscopically, this stage is seen as having a columnar lined oesophagus. Note that the effective length of the lower oesophageal sphincter has become shortened from B to C.

Note that the histologic squamo-oxyntic gap has the same distribution of the three epithelial types irrespective of its length.

Intestinal metaplasia in the gap is the definition of Barrett oesophagus, Intestinal metaplasia was uncommon in the 1950s and has progressively increased in prevalence in the past six decades. In Los Angeles, virtually all patients with a gap length exceeding 5 cm had intestinal metaplasia in 2003 (19). Mapping studies in

2007 showed that intestinal metaplasia extended to the most distal regions of the gap. This is very different than the distribution of intestinal metaplasia reported from England (another high prevalence region of the world for Barrett oesophagus today) in the 1950s and in the Eastern USA in 1976. It is likely that the reason for the increase in prevalence and extent of intestinal metaplasia within the gap is a function of the increased use of acid suppression in patients with reflux disease. We have suggested that alkalinization of gastric juice promotes CDX-2 activation in cardiac mucosa and thereby drives intestinal metaplasia.

(f) Progression in the reflux-to adenocarcinoma sequence

The only proven premalignant epithelium in the squamo-oxyntic gap is intestinal metaplasia. The reflux to adenocarcinoma sequence can therefore be divided into the following stages: (1) Metaplasia of squamous epithelium to cardiac epithelium; (2) Development of intestinal metaplasia in cardiac epithelium; (3) Carcinogenesis in intestinalized epithelium, which can be recognized as sequentially increasing grades of dysplasia to adenocarcinoma (20-22). The rate of progression of intestinal metaplasia through low and high grade dysplasia to adenocarcinoma is variable, but the presence of increasing dysplasia confers increasing risk of cancer.

Carcinogenesis in reflux disease is by luminal carcinogenesis. The carcinogen which is an unknown molecule in gastric juice, probably related to bile salt metabolites, is delivered to the oesophagus by reflux. The oesophagus is at risk only when it contains the target cell for the carcinogen.

The target cell is marked by the presence of intestinal metaplasia. The carcinogen concentration is highest in the distal oesophagus and the likelihood of cancer increases as the intestinal metaplasia in the oesophagus involves the more distal region of the oesophagus. In general, the maximum site of origin of esophageal adenocarcinoma is at the most distal point in the oesophagus that contains intestinal metaplasia. As the extent of intestinal metaplasia in the oesophagus has increased from 1950 to 2011, the most common location of adenocarcinoma has moved from the mid-oesophagus to the distal oesophagus.

(g) Regression or cure of reflux disease

If one views reflux disease by its cancer risk, regression of the disease can be defined as: (a) reversal of intestinal metaplasia to cardiac or squamous epithelium; (b) conversion of any columnar epithelium to oxyntocardiac epithelium which does not develop intestinal metaplasia and does not progress to adenocarcinoma.

Acid suppressive drug therapy does not cause regression of reflux disease in these terms. Intestinal metaplasia within the squamo-oxyntic gap is actually favored by the alkalization of gastric juice. Ablation of columnar epithelium, if coupled with effective acid suppression, causes replacement of the columnar epithelium with neo-squamous epithelium. Ablation is presently recommended only for high grade dysplasia and the long term success of ablative treatment is not established. Surgical repair of the lower esophageal sphincter, if successful, can stop reflux and prevent carcinogen from gaining access to

the target cell in the oesophagus. Surgical repair of the sphincter can be done endoscopically as well as by laparoscopic surgery. Endoscopic methods have generally proved ineffective. Laparoscopic Nissen fundoplication, when performed with skill, is highly successful in preventing reflux. However, significant variation among surgeons in the success of this procedure has resulted in contradictory results. It is probably true, however, that a well done surgical fundoplication will prevent progression to cancer. Recently, the insertion of a magnetic ring ("LINX") around the distal esophagus by laparoscopy has proved effective in augmenting the sphincter, decreasing reflux and improving quality of life in patients.

Correlation of histology and anatomy

Irrespective of the length of the gap, the distribution of the three epithelia is constant (11). This is strong evidence that the entire histological gap represents columnar lined oesophagus. The belief that part of the distal region of this gap represents proximal stomach ("gastric cardia") is no longer tenable. In the normal patient without a squamo-oxyntic gap, the entire proximal region of the stomach is lined by gastric oxyntic mucosa. If cardiac or oxynto cardiac epithelium is present in this area, it represents columnar lined oesophagus in what must be a dilated segment of reflux-damaged oesophagus that resembles proximal stomach. We have designated this as the dilated distal oesophagus (23).

There is proof for this, when full thickness sections from this region are examined in oesophagectomy specimens, submucosal glands are present in this region. The distance to which the submuco

sal glands extend into the sac coincides exactly with the length of the squamo-oxyntic gap distal to the end of the tubal oesophagus (18).

The understanding that the squamo-oxyntic gap is equivalent to the columnar lined oesophagus allows us to define anatomy from the standpoint of histology rather than the reverse. The squamo-oxyntic gap, when it is long, consists of visible columnar metaplasia in the tubal part of the oesophagus with its distal region extending to the proximal region of the sac that appears to be the stomach. This is an illusion created by a severely damaged distal oesophagus that has completely lost sphincter pressure and ceased to be part of the functional oesophagus (end stage oesophagus). Without its resting sphincter pressure, the oesophagus dilates under the positive luminal pressure and becomes part of the gastric reservoir. As with any reservoir that dilates and empties, this part of the columnar lined oesophagus develops rugal folds. If the rugal folds are used to define stomach, the dilated distal oesophagus will be mistakenly included as the proximal stomach (23).

In patients with a short squamo-oxyntic gap, the entire gap is in the dilated distal oesophagus (23). With the present criteria, this gap is missed completely because it appears to be normal stomach by endoscopy. The present guidelines recommend that patients with normal endoscopy should not undergo biopsy. If biopsies are taken, one of the following findings are possible: (a) There is only squamous epithelium and gastric oxyntic mucosa; this

is normal; (b) There is only oxyntocardiac mucosa in addition to squamous and oxyntic; these patients have mild reflux disease without risk of cancer because oxyntocardiac mucosa does not progress to intestinal metaplasia. We call these patients “compensated reflux.” (c) There is cardiac mucosa without intestinal metaplasia. Cardiac mucosa shows chronic inflammation and reactive foveolar hyperplasia. At present, this finding is called “normal gastric cardiac mucosa.” This is incorrect if cardiac mucosa represent the oesophagus. We call this “reflux carditis” because it is a highly specific diagnostic criterion of reflux disease. Patients with reflux carditis have no risk of cancer but can progress to intestinal metaplasia, progressing in the reflux to adenocarcinoma sequence. (d) There is cardiac mucosa with intestinal metaplasia. At present this is called “intestinal metaplasia of the gastric cardiac”. Again, this is incorrect. We call this “intestinal metaplasia in dilated distal oesophagus”. This is the precursor lesion for adenocarcinoma of the gastric cardia. There is no literature that defines the of risk rate of cancer in patients with intestinal metaplasia of the dilated distal oesophagus.

Adenocarcinoma of the “gastric cardia” is similarly adenocarcinoma of the dilated distal oesophagus (24,25). It has long been known that this entity has an epidemiology that is similar to esophageal adenocarcinoma and different than gastric adenocarcinoma. It is also associated with gastro-oesophageal reflux disease. These tumors have previously been classified as gastric carcinomas, resulting in an underestimation of the incidence of reflux-induced adenocarcinoma. The most recent seventh

edition of the AJCC staging guidelines have corrected this error. Adenocarcinomas in this region are now to be classified as esophageal and not gastric cancers.

Pathology of early/mild gastro-oesophageal reflux disease

The primary cause of reflux disease is gastric over-distension. When the stomach is over-distended, either experimentally by air insufflation or in the post-prandial phase following a heavy meal, the associated increased intra-gastric pressure overcomes the resting pressure of the distal region of the lower oesophageal sphincter. This causes the effective sphincter length to shorten and the distal oesophagus to be “taken up” into the contour of the stomach in a manner that is similar to the “taking-up” of the uterine cervix during the first stage of labor. The squamous epithelium is now exposed to gastric juice. It is relevant that an acid pocket develops in this region in the post-prandial period, resulting in an exaggeration of acid induced damage to the squamous epithelium during this period. The squamous epithelial damage by this mechanism is greatest when such exposure is repeated by constant intake of heavy meals and when the meal has a high fat content which delays gastric emptying.

With repeated damage, columnar metaplasia occurs in squamous epithelium. This is associated with permanent loss of the lower oesophageal sphincter. The squamo-oxyntic gap begins and correlates with the destruction of the sphincter. The segment of oesophagus that loses sphincter pressure dilates permanently. The dilated lower oesophageal sphincter is exactly the

same length as the squamo-oxyntic gap distal to the tubal oesophagus.

This is early reflux disease. It is characterized by either mild or no symptoms of reflux and pathologic changes are limited to the distal part of the destroyed lower oesophageal sphincter (intra-sphincteric reflux disease). The disease progresses in two ways: (a) The amount of squamous epithelial damage progressively increases, resulting in an increasing length of the squamo-oxyntic gap and an increased length of dilated distal oesophagus. (b) Progression of the columnar epithelium in the reflux-to-adenocarcinoma sequence with cardiac epithelium undergoing intestinal metaplasia and progressing to increasing grades of dysplasia and adenocarcinoma. It is important to recognize that many patients with adenocarcinoma occurring in a squamo-oxyntic gap limited to the dilated distal oesophagus are asymptomatic. They will be missed with definitions of reflux that are based on the presence of symptoms. Their premalignant state can only be detected by appropriate biopsy.

Early reflux disease characterized by a squamo-oxyntic gap limited to the dilated distal oesophagus is the pathology of the majority of patients with reflux disease. These patients have symptoms of reflux with a normal endoscopy by present criteria; these patients are designated as having non-erosive reflux disease (NERD). If appropriate biopsies are taken in these patients, their disease can be categorized based on the types of columnar epithelia that are present into normal (very uncommon), compensated reflux, reflux carditis and intestinal metaplasia of the dilated distal oesophagus.

It is likely that geographic regions where reflux disease is uncommon have predominantly mild, early stage reflux disease. In populations where *Helicobacter pylori* infection is very common, such as Korea, part of the reason for the rarity of reflux disease is that gastritis occurring in early life results in hypochlorhydria. This acts as a “natural” acid suppressant that protects the squamous epithelium. In these populations, eradication of *Helicobacter pylori* may result in the emergence of reflux disease and its complications. In other Asian countries, the diet that has a low fat and high spice content may cause rapid gastric emptying, preventing gastric over-distension and protecting the sphincter. In such populations, the infiltration of a western style high fat diet may lead to emergence of reflux disease and its complications.

Sri Lanka is likely to be a country with a population having a low prevalence of severe reflux disease as defined by the prevalence of symptomatic reflux. However, the prevalence of asymptomatic and mild reflux is unknown. Research into evaluation of the prevalence of early reflux disease in Sri Lanka is likely to provide fascinating differences with the well studied population in Los Angeles. This information may provide valuable insights into the pathology and science of reflux disease and is strongly recommended. This is particularly true because such studies are not undertaken in other areas because of the lack of understanding of the disease which extends to the most recent guidelines issued by the American Gastroenterological Association.

Pathology of late reflux disease

With increasing destruction of the lower oesophageal sphincter, the ability of the sphincter to prevent reflux of gastric contents into the body of the oesophagus disappears. The shortening of the sphincter is associated with free reflux episodes into the oesophagus with increasing frequency and severity. This is initially maximal in the post prandial period where gastric distension further shortens the stomach. With increasing permanent damage to the sphincter, reflux occurs at times between meals and nocturnally when the patient is supine. This results in severe and frequent heartburn, regurgitation and extra oesophageal reflux disease due to entry of refluxate into the pharynx, larynx and airways. Even this late stage of reflux disease is treated empirically with acid suppressive drugs, which, when taken long term, are effective in the majority of patients in controlling symptoms, albeit incompletely. Patients live without pain but with fear of eating normally lest this precipitates symptoms. Even when treatment controls pain, these drugs do not prevent either progressive sphincter damage or progression to cancer. In over 85% of patients who develop reflux-induced adenocarcinoma in the USA, less than 15% have had an endoscopy before they present with symptoms of advanced cancer. Advanced oesophageal cancer has a mortality of over 90%. In 2011, it is expected that over 20,00 patients will die of oesophageal adenocarcinoma in the USA.

This late stage of reflux disease frequently produces visible abnormality at endoscopy.

It results in erosions in the squamous epithelium and visible columnar lined oesophagus. Biopsies are recommended in patients with visible columnar lined oesophagus. When intestinal metaplasia is present, a diagnosis of Barrett oesophagus is made and the patient is placed on surveillance. The objective of surveillance is to detect high grade dysplasia at which time ablative therapy, either with an endoscopic technique that utilizes radio-frequency to ablate the surface epithelium or with ablative surgery (endoscopic mucosal resection or oesophagectomy).

It is unlikely that many patients in Sri Lanka will show these late features of reflux disease. Barrett oesophagus in visible segments of columnar lined oesophagus and adenocarcinoma in the distal oesophagus are both likely to be rare. However, it is possible that many low prevalence Asian countries are at the point of this disease in the USA in 1950, when not a single case of oesophageal adenocarcinoma had been reported or in 1975 when the incidence of cancer was very low, probably similar to that today in Sri Lanka. It is sobering to know that the incidence increased ten-fold in the next 30 years in the USA and continues to increase. A suggestion would be that Sri Lankan physicians have an opportunity to establish a baseline at a cellular level as it has never been established anywhere and then follow the progression of cellular events in case the epidemic of adenocarcinoma descends on Sri Lanka. Many authorities predict that Asian countries with low prevalence of reflux are at the beginning stage of a possible epidemic. To get in front

of this epidemic, a level of understanding at the cellular level will be an enormous contribution to science.

References

1. Stein HJ, Liebermann-Meffert D, DeMeester TR, Siewert RJ. Three-dimensional pressure image and muscular structure of the human lower oesophageal sphincter. *Surgery* 1995; 117: 692-698.
2. Hayward J. The lower end of the oesophagus. *Thorax* 1961; 16: 36-41.
3. Barrett NR. Chronic peptic ulcer of the oesophagus and "oesophagitis". *British Journal of Surgery* 1950; 38: 175-182.
4. Allison PR, Johnstone AS. The oesophagus lined with gastric mucous membrane. *Thorax* 1953; 8: 87-101.
5. Barrett NR. The lower oesophagus lined by columnar epithelium. *Surgery* 1957; 41: 881-894.
6. Spechler SJ, Zeroogian JM, Antonioli DA, et al. Prevalence of metaplasia at the gastroesophageal junction. *Lancet* 1994; 344: 1533 - 1536.
7. Paull A, Trier JS, Dalton MD, et al. The histologic spectrum of Barrett's esophagus. *New England Journal of Medicine*. 1976; 295: 476-480.
8. Chandrasoma PT: Histologic definition and diagnosis of epithelial types in the oesophagus and stomach. In: Chandrasoma PT (auth) *Diagnostic atlas of Gastro-oesophageal Reflux disease*. San Diego: Academic Press. 2007; 61-111.
9. Spechler SJ, Sharma P, Souza RF, Inadomi JM, Shaheen NJ, Brill JV, Pruitt RV, Kahrilas PJ, Nix K, Montgomery EA, American Gastroentero

logical Association Medical Position Statement on the Management of Barrett's Esophagus. *Gastroenterology* 2011; 140: 1084–1091.

10. Chandrasoma PT, DeMeester TR. GERD: Reflux to Esophageal Adenocarcinoma. San Diego: Academic Press; 2006.

11. Chandrasoma PT, Wijetunge S, DeMeester SR et al. The Histologic Squamo-oxyntic Gap: An Accurate and Reproducible Diagnostic Marker of Gastroesophageal Reflux Disease. *American Journal of Surgical Pathology* 2010; 34: 1574-1581.

12. Oberg S, Peters JH, DeMeester TR, Chandrasoma P, Hagen JA, Ireland AP, Ritter MP, Mason RJ, Crookes P, Bremner CG. Inflammation and specialized intestinal metaplasia of cardia mucosa is a manifestation of gastro-oesophageal reflux disease. *Annals of Surgery* 1997; 226: 522-532.

13. Glickman JN, Fox V, Antonioli DA, Wang HH, Odze RD. Morphology of the cardia and significance of carditis in pediatric patients. *American Journal of Surgical Pathology* 2002; 26: 1032-9.

14. Chandrasoma PT, Der R, Ma Y, Dalton P, Taira M. Histology of the gastro-oesophageal junction: an autopsy study. *American Journal of Surgical Pathology* 2000; 24: 402–409.

15. Chandrasoma PT, Der R, Dalton P, Kobeyashi G, Ma Y, Peters J, DeMeester T. Distribution and significance of epithelial types in columnar-lined esophagus. *American Journal of Surgical Pathology* 2001; 25(9): 1188–93.

16. Chandrasoma PT, Lokuhetty DM, DeMeester TR, Brenner CG, Peters JH, Oberg S, Groshen S. Definition of histopathologic changes in gastroesophageal reflux disease. *American Journal of Surgical Pathology* 2000; 24(3): 344–351.

17. Der R, Tsao-Wei DD, DeMeester T, Peters J, Groshen S, Lord RVN, Chandrasoma P. Carditis – A manifestation of gastroesophageal reflux disease. *American Journal of Surgical Pathology* 2001; 25(2): 245–252.

18. Chandrasoma P, Makarewicz K, Wickramasinghe K, Ma Y, Demeester T. A proposal for a new validated histological definition of the gastro-oesophageal junction. *Human Pathology* 2006; 37: 40–47.

19. Chandrasoma PT, Der R, Ma Y, Peters J, DeMeester T. Histologic classification of patients based on mapping biopsies of the gastroesophageal junction. *American Journal of Surgical pathology* 2003; 27: 929–36.

20. Haggitt R, Barrett's esophagus, dysplasia, and adenocarcinoma, *Human Pathology* 1994; 25: 982-993.

21. Chandrasoma P, Wickramasinghe K, Ma Y, DeMeester T. Is intestinal metaplasia a necessary precursor lesion for adenocarcinoma of the distal esophagus, gastro-oesophageal junction and gastric cardia? *Diseases of the Esophagus* 2007; 20: 36–41.

22. Chandrasoma P, Wijetunge S, DeMeester S, Ma Y, Hagen J, MD, Zamis L, DeMeester T. Columnar-lined oesophagus without intestinal metaplasia has no proven risk of adenocarcinoma. *American Journal of Surgical Pathology* 2012; 36 (1): 1–7.

23. Chandrasoma P, Wijetunge S, Ma Y, DeMeester, S, Hagen J, DeMeester T. The Dilated Distal Esophagus: A New Entity That Is the Pathologic Basis of Early Gastroesophageal Reflux Disease. *American Journal of Surgical Pathology* 2011; 35 (12); 1873-1881.

24. Chandrasoma P, Wickramasinghe K, Ma Y, DeMeester T. Adenocarcinoma of distal esophagus

and “gastric cardia” are predominantly oesophageal carcinoma. American Journal of Surgical Pathology 2007; 31: 569-575.

25. Wijetunge S, Ma Y, Hagen J, DeMeester S, DeMeester T, Chandrasoma PT. Association of adenocarcinoma of the oesophagus, “gastro-oesophageal junction” and “gastric cardia” with gastric pathology. American Journal of Surgical Pathology. 2010; 34: 1521-1527.