Journal of the Postgraduate Institute of Medicine 2026; 13(1): E302 1-3

https://doi.org/10.4038/jpgim.8633

Case Report

Internal hernia from sigmoid epiploic appendage resulting in closed-loop small bowel obstruction: A rare case report

Vivian Suthakaran[1,2], Jeepara Peethambaram, Mithushan Jesuthasan

[1]Postgraduate Institute of Medicine, University of Colombo, [2]Teaching Hospital, Batticaloa

Key words: Epiploic Appendage, Internal Hernia, Small Bowel Obstruction, Closed Loop Obstruction, Bowel Ischemia

Corresponding Author: Vivian Suthakaran, E-mail< trishan4567@gmail.com >

https://orcid.org/0009-0004-0126-8102

Received: 05 Mar 2026, Accepted revised version: 03 Aug 2026, Published: 26 Nov 2026

Competing Interests: Authors have declared that no competing interests exist

© Authors. This is an open-access article distributed under a Creative Commons Attribution-Share Alike 4.0 International License (CC BY-SA 4.0), which permits unrestricted use, distribution, and reproduction in any medium, provided the original author and source are attributed and materials are shared under the same license.

Introduction

Epiploic appendages are pedunculated, fat-filled peritoneal projections that arise from the external surface of the colon, first described in the surgical literature several decades ago [1]. Their tenuous blood supply and mobility make them prone to torsion, venous congestion, and infarction [1,2]. Epiploic appendagitis is common, but obstruction from appendage pathology is rare.

Internal hernias themselves account for less than 1% of small-bowel obstructions and represent an important but frequently overlooked cause of strangulation in patients without prior abdominal surgery [3]. Small-bowel obstruction caused by appendices epiploicae is rare. Reported mechanisms include adhesion between two appendices epiploicae, which may form a fibrous band or an abnormal aperture through which small bowel can herniate, resulting in closed-loop obstruction [5].
We report a rare closed-loop obstruction from a sigmoid epiploic appendage, requiring early surgical intervention.

Case Presentation

A 42-year-old woman with no prior medical illness or abdominal surgery presented with a three-day history of worsening colicky abdominal pain and persistent vomiting, with no bowel opening. Examination revealed mild dehydration and generalised abdominal tenderness without peritonism.

https://doi.org/10.4038/jpgim.8633

Initial inflammatory markers were normal; serum lactate was 3 mmol/L. Abdominal radiographs showed dilated central small-bowel loops with multiple air–fluid levels, consistent with small-bowel obstruction. CECT was unavailable at the time in the hospital. She was managed conservatively with nasogastric decompression and intravenous resuscitation.

Despite treatment, her pain intensified, vomiting persisted, and lactate increased to 6 mmol/L, raising concern for ischemia. Urgent exploratory laparotomy was performed. Intraoperatively, a segment of distal ileum was found entrapped beneath a tight band formed by sigmoid epiploic appendages, creating an internal hernia and closed-loop obstruction. The bowel was congested with an area of transmural necrosis. The band was divided, and segmental small-bowel resection with primary end-to-end anastomosis was performed. No additional pathology was identified.

Postoperatively, she was managed with early recovery principles, remained nil per oral for 24 hours, and had oral intake gradually reintroduced. Recovery was uncomplicated, and she was discharged on postoperative day 10. Histology of the resected bowel confirmed full-thickness ischemic necrosis without inflammatory or neoplastic pathology.

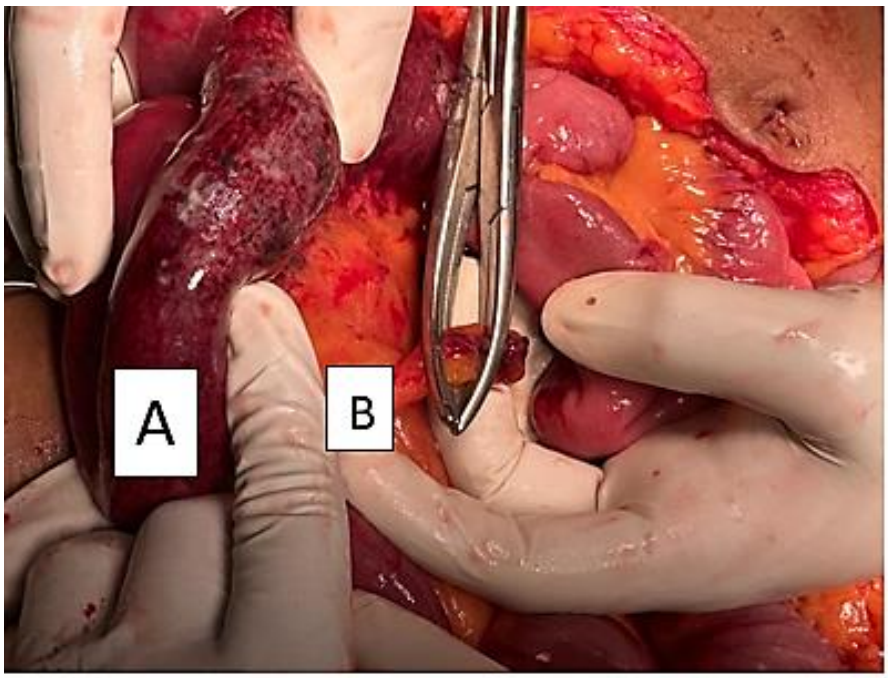

Figure 1: A- Intraoperative findings of the closed-loop small bowel obstruction due to sigmoid epiploic appendage. B - clamped sigmoid epiploic appendage causing obstruction

Discussion

Epiploic appendages are usually benign but are prone to torsion, thrombosis, inflammation, and infarction [1,2]. They usually cause localised pain; mechanical

obstruction is uncommon [4]. Although uncommon, internal hernias have a greater risk of strangulation than adhesive causes [3]. Internal herniation through the appendices epiploicae has been reported only in a few cases [6].

A sigmoid epiploic appendage formed a tight aperture, causing closed-loop obstruction with ischemia. Such cases are rare and typically diagnosed only at exploration due to nonspecific presentation [6].

Although not confirmed with CECT, rising lactate indicated evolving ischemia and warranted early surgery. Prompt exploration prevents irreversible necrosis and reduces morbidity. Early recovery protocols contributed to an uncomplicated outcome.
This case reinforces epiploic appendage–related internal hernia as a rare cause of obstruction in patients without previous surgery.

Conclusion

Internal herniation beneath a sigmoid epiploic appendage is an exceptionally rare cause of small-bowel obstruction. This case highlights the need for early operative intervention when clinical or biochemical features suggest possible ischemia in limited resource centres. Prompt surgical management can prevent catastrophic bowel necrosis and contributes to favourable outcomes. Increased awareness of this rare entity may aid intraoperative recognition and appropriate management.

References

1. Thomas JH, Rosato FE, Patterson LT. Epiploic appendagitis. Surg Gynecol Obstet. 1974;138:23-25.
2. Osadchy A, Shapiro-Feinberg M, Zissin R. Strangulated small bowel obstruction related to chronic torsion of an epiploic appendix. Br J Radiol. 2001;74:1062-1064. https://doi.org/10.1259/bjr.74.887.741062
3. Ghahremani GG. Internal abdominal hernias. Surg Clin North Am. 1984;64:393-406. https://doi.org/10.1016/S0039-6109(16)43293-7
4. Nemoto H, Yoshizawa Y, Hibi K, et al. Strangulation caused by a small bowel epiploic appendage: case report. Case Rep Gastroenterol. 2008;2:214-218. https://doi.org/10.1159/000135609
5. Zabihi F, Mohsenian N, Khodabakhsh M, et al. Internal hernia through a foramen formed by appendices epiploicae: case report and review. Clin Case Rep. 2023;11:e6119.
6. Srivastava KN. Internal herniation through appendices epiploicae causing intestinal obstruction: a case report. J Surg Case Rep. 2018;9:rjy239. https://doi.org/10.1093/jscr/rjy239