Journal of the Postgraduate Institute of Medicine 2026; 13(1): E303 1-3

https://doi.org/10.4038/jpgim.8641

Case Report

Leukaemoid reaction mimicking neonatal leukaemia in an extremely preterm neonate

Nimesha Chamidani Gamhewage

University of Sri Jayewardenepura

Key words: extremely preterm, leukaemoid reaction, neonatal leukaemia

Corresponding Author: Nimesha Chamidani Gamhewage, E-mail< nimeshagamhewage@sjp.ac.lk >

https://orcid.org/0000-0001-5129-4158

Received: 19 Jun 2026, Accepted: 07 Jul 2026, Published: 26 Nov 2026

Competing Interests: Author has declared that no competing interests exist

© Author. This is an open-access article distributed under a Creative Commons Attribution-Share Alike 4.0 International License (CC BY-SA 4.0), which permits unrestricted use, distribution, and reproduction in any medium, provided the original author and source are attributed and materials are shared under the same license.

Introduction

Leukaemoid reaction in neonates is defined as leukocytosis exceeding 50,000/mm³, representing a response to stress or infection [1]. However, it can closely mimic congenital leukaemia [2]. The differentiation is important as neonatal leukaemia has a grave prognosis, whereas leukaemoid reactions are transient [5]. The incidence of neonatal leukaemoid reaction varies from 1.3 to 15%[1,2].

Antenatal maternal administration of steroids, neonatal sepsis, Down syndrome, maternal chorioamnionitis, prolonged rupture of membranes (PROM) and maternal sepsis [2,3] are known causes.

Case presentation

This case describes a neonate born at 26 weeks of gestation, with a birth weight of 840 g who developed a leukaemoid reaction in the second day of life. Mother presented with PROM and her high vaginal swab revealed *Candida* species. Mother did not have chorioamnionitis or sepsis. An emergency caesarian section was performed due to fetal distress. Baby's Apgar scores were 1 **[3]**, 5 **[7]**, and 10 **[8]** and she required resuscitation at birth followed by mechanical ventilation and surfactant therapy for respiratory distress syndrome.

Journal of the Postgraduate Institute of Medicine 2026; 13(1): E303 1-3

https://doi.org/10.4038/jpgim.8641

From the first day of life, she exhibited leukocytosis, peaking at 95 ×10⁹/L on day six, with a predominant neutrophilic response and leucoerythroblastic blood picture. This raised suspicion of neonatal leukaemia. However, features suggestive of malignancy, such as hepatosplenomegaly, skin infiltrations, or progressive cytopaenia were absent.

Further evaluation demonstrated <1% blasts on peripheral blood flow cytometry, rendering leukaemia unlikely. CD18 expression was normal, ruling out leukocyte adhesion deficiency. Serial counts showed a gradual decline in leucocytosis [Figure 1]. Bone marrow aspiration for cytology was not required as the leucocytosis resolved spontaneously by day 15.

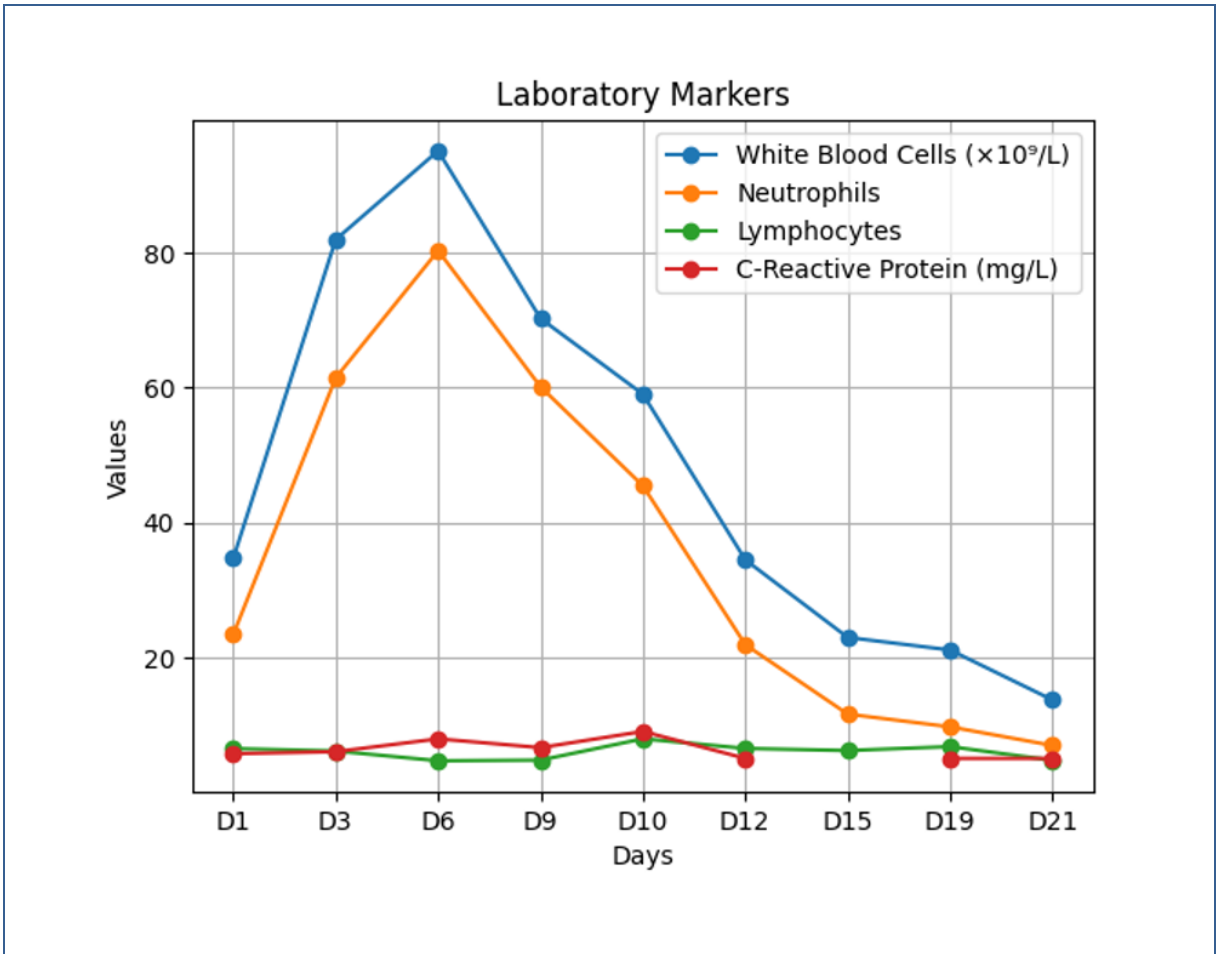

Figure 1: Laboratory markers\

Empirical antibiotics were initiated at birth. Early septic workup, including blood cultures and inflammatory markers, was unremarkable. During the third week of life, she developed necrotizing enterocolitis (NEC) (Bells stage 2A). Concurrently, she developed ventilator-associated pneumonia (VAP) due to *Acinetobacter* species. Although she recovered from NEC and VAP, her clinical course was complicated with chronic lung disease (CLD). She required oxygen therapy until day 122. The baby was discharged home, on air on 125th day of life. There was no element of retinopathy of prematurity (ROP).

Discussion

This case is notable for the timing and magnitude of leukocytosis, occurring within the first 72 hours of life, prior to any confirmed infection. Extreme prematurity likely played a central role. Immature hematopoietic regulation, combined with perinatal stress and hypoxia, may result in release of cytokines, catecholamines and corticosteroids resulting in marrow stimulation [1,4]. The subsequent development of NEC and CLD in this infant is noteworthy as leukaemoid reactions in preterm neonates have been associated with increased risk of similar outcomes [1].

The challenge in this case was differentiating leukaemoid reaction from congenital leukaemia. Key features supporting a benign process included minimal blast percentage, absence of organomegaly, lack of progressive cytopaenias, and spontaneous resolution of leukocytosis. Recognition of these features prevented unnecessary invasive investigations and inappropriate treatment [5].

Conclusions

This case demonstrates that leukaemoid reaction in preterm neonates may occur as an early, non-infective physiological response, mimicking leukaemia. Awareness of this phenomenon is essential to avoid unnecessary investigations and treatment.

References

1. Terry C, Kane D, Eogan M, McCallion N, Doyle E, Drew RJ. Retrospective analysis of leukemoid reactions in extremely preterm infants in a tertiary NICU from 2018-2021. J Matern Fetal Neonatal Med. 2023 Dec;36(2):2225115. https://doi.org/10.1080/14767058.2023.2225115
2. Blanchette V, Dror Y, Chan A. Hematology. In: MacDonald MG, Mullett MD, Seshia MM, editors. Avery's Neonatology - Pathophysiology and management of the Newborn. 6th ed. Philadelphia: Lippincott Williams and Wilkins; 2005. pp. 1169-234.
3. Duran R, Ozbek UV, Ciftdemir NA, et al. The relationship between leukemoid reaction and perinatal morbidity, mortality, and chorioamnionitis in low birth weight infants. Int J Infect Dis. 2010;14(11):e998-1001-1001. https://doi.org/10.1016/j.ijid.2010.06.012
4. Rastogi S, Rastogi D, Sundaram R, Kulpa J, Parekh AJ. Leukemoid reaction in extremely low birth weight infants. Am J Perinatol. 1999;16:93-7. https://doi.org/10.1055/s-2007-993843
5. Kakkat SM, Lakra MS, Lakhar B, Jain A, Reddy RM. An Unusual Presentation of Neonatal Sepsis as Hyperleukocytosis With Firm Lymphadenopathy: A Diagnostic Challenge. Cureus. 2022 Oct https://doi.org/10.7759/cureus.30454