Journal of the Postgraduate Institute of Medicine 2026; 13(1): E304 1-6

https://doi.org/10.4038/jpgim.8642

Case Report

Delayed thoracic metastasis of leiomyosarcoma presenting as an anterior mediastinal spindle cell neoplasm: A diagnostic challenge

K V P Munasinghe[1,2], A M Nanayakkara[1,3], W D N De Zoysa[1,2], D Rodrigo[2], G BL Samarasekera[2]

[1]Postgraduate Institute of Medicine, University of Colombo, [2]National Hospital for Respiratory Diseases, Welisara, [3]National STD/AIDS Control Programme, Ministry of Health

Key words: leiomyosarcoma, spindle cell tumour, pleural effusion, thoracic metastasis

Corresponding Author: K V P Munasinghe, E-mail< paramivm@gmail.com >

https://orcid.org/0009-0007-3316-1838

Received: 19 Jun 2026, Accepted: 07 Jul 2026, Published: 26 Nov 2026

Competing Interests: Author has declared that no competing interests exist

© Authors. This is an open-access article distributed under a Creative Commons Attribution-Share Alike 4.0 International License (CC BY-SA 4.0), which permits unrestricted use, distribution, and reproduction in any medium, provided the original author and source are attributed and materials are shared under the same license.

Introduction

Spindle cell tumors carry a morphological description of a mass composed of spindle shaped cells ranging from benign tumors such as schwannoma and leiomyoma to malignant tumors in the form of sarcomas.

Leiomyosarcomas are the most common type of soft tissue sarcomas arising from the smooth muscle carrying an incidence of 11% [1]. They are derivatives of mesenchymal cell precursors. Soft tissue leiomyosarcomas most frequently arise in the retroperitoneum and from large blood vessels. Lower extremities serve as the commonest site of extra-retroperitoneal leiomyosarcomas accounting for approximately 10–15% of all limb soft tissue sarcomas [2]. Mediastinal leiomyosarcomas are found in approximately 9% of mediastinal sarcomas [3]. Even though leiomyosarcomas are prone to late metastasis to sites such as the lungs, bones, and liver, the presentation of a spindle cell tumor as an anterior mediastinal mass in a patient with a prior history of lower extremity leiomyosarcoma, years after treatment, carries a high degree of suspicion for metastatic disease rather than a primary spindle cell neoplasm.

https://doi.org/10.4038/jpgim.8642

We hereby report a case of a middle-aged man with a history of leiomyosarcoma in lower extremity which was treated six years back, presenting with a large mediastinal spindle cell tumor with pleural effusion.

Case presentation

A 47-year-old male with a history of leiomyosarcoma of the left lower limb six years back, who had undergone surgery with a curative intent and on oncology follow up, presented with a dry cough of 6 weeks duration. He did not complain of significant shortness of breath, haemoptysis or constitutional symptoms. He is a soldering technician by profession and had been functioning well and asymptomatic until 6 weeks prior to this admission.

On examination, he was haemodynamically stable. There were reduced chest wall movements, dullness to percussion and reduced breath sounds on the middle to lower parts of the right hemithorax. His haemogram revealed a high C-reactive protein with a normal erythrocyte sedimentation rate (ESR). His chest X-ray showed a mass involving the right middle and lower lobes with mild pleural effusion on the same side. (Figure A)

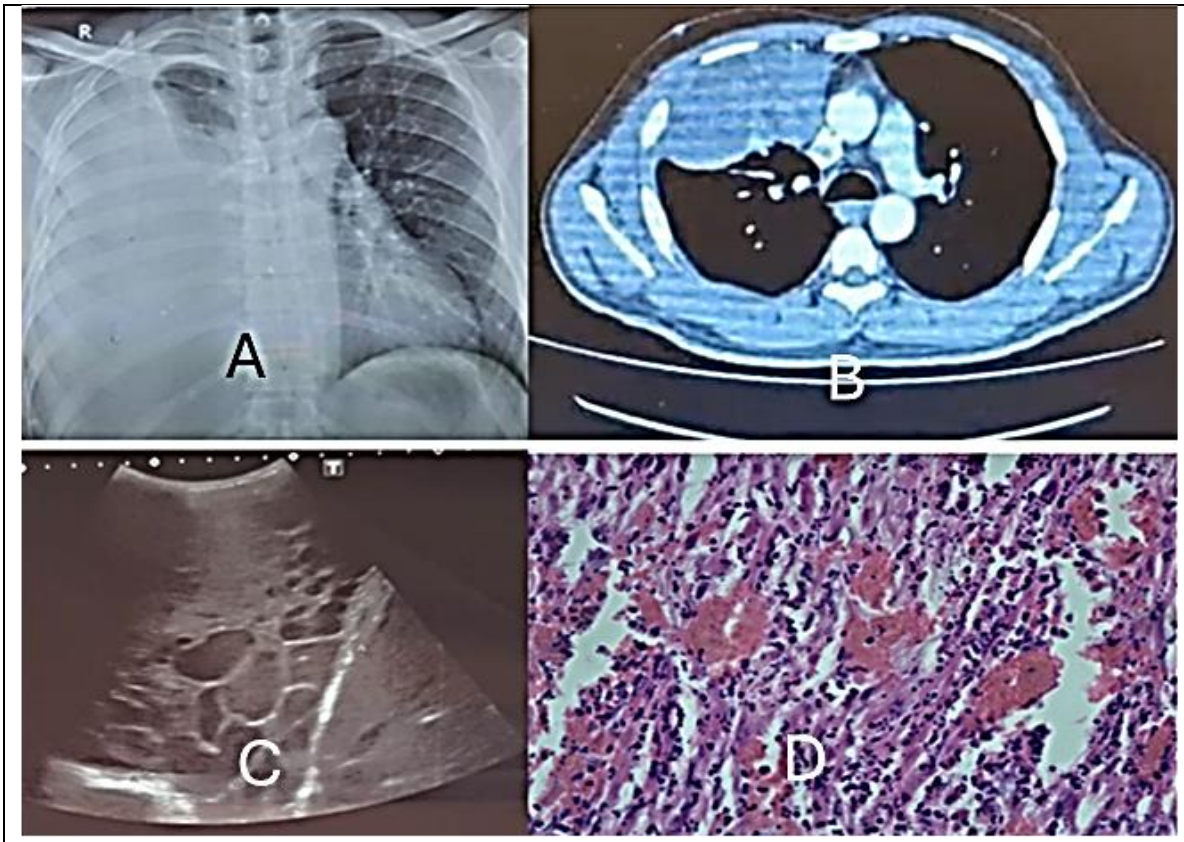

Figure A - CXR –Right massive pleural effusion with mass in upper and middle lobes
Figure B - CECT chest – Right anterior mediastinal mass
Figure C- USS Chest – Right septated pleural effusion
Figure D - Histology – Malignant spindle cell tumor

His contrast enhanced computed tomography (CECT) chest and abdomen revealed a large heterogeneously enhancing necrotic right side anterior mediastinal mass measuring 12cmx10cmx9cm in size associated with a mild pleural effusion. (Figure B). Bronchoscopy revealed external compression of the right middle lobe with no endobronchial masses. Ultrasound guided biopsy of the mass was performed and returned as a malignant spindle cell tumor supported by immunohistochemistry. (Figure D, Table)

Table: Investigation results with reference values

Test	Value	Reference range
WBC	10.6 X 10^9/L (Neutrophil - 66%)	4-10x10^9/L
Hemoglobin	12.2 mg/dl	12 – 16 g/dL
Platelets	404 x10^9/L	150 – 400 X10^9/L
CRP	67 mg/dL	< 6 mg/dL
ESR	50 mm/1st hour	<20 mm/hour
Serum Sodium	135 mmol/L	135 – 145 mmol/L
Serum Potassium	3.8 mmol/L	3.5 – 5.5 mmol/L
Serum creatinine	1.94 mg/dL	0.7 – 1.3 mg/dL
SGOT (AST)	18 U/L	8 – 33 U/L
SGPT (ALT)	48 U/L	4 – 36 U/L
Serum Bilirubin	0.4 mg/dL	0.2 – 1.3 mg/dL
INR	0.98	0.8 – 1.1
Sputum for tuberculosis screening	Negative	
Pleural fluid analysis	Pleural full report Total cell count – 60 cells/ml Polymorphs - 90% Lymphocytes – 10% ADA – 14 U/L Pleural fluid for Tuberculosis/pyogenic/fungal screening – negative Cytology – malignant cells seen	
Chest Xray	Right sided massive pleural effusion with mass involving right upper and middle lobes	
Ultra sound scan (USS) of the chest	Right sided septated effusion noted. Thickness>9cm Right lung appears collapsed 13x10x11cm size large cystic, solid mass in right chest cavity (Figure C)	
CECT Chest, abdomen, pelvis	large heterogeneously enhancing necrotic right side anterior mediastinal mass measuring 12cmx10cmx9cm in size associated with mild pleural effusion. Malignant anterior mediastinal mass is likely. Left upper lobe nodules present.	
Bronchoscopy	external compression of the right middle lobe with no endobronchial masses.	
USS guided tru cut biopsy from right lung mass	A malignant spindle cell tumor identified. Immunohistochemistry positive for SMA, desmin, and h-caldesmon. Negative for cytokeratins and S-100	

Meanwhile, during the ward stay his pleural effusion further advanced, worsening his shortness of breath. Liaising with the thoracic surgical team, an intercostal tube was inserted ensuring adequate drainage accompanied by talc pleurodesis. Following which, he was handed over to the oncology team for further management.

Discussion

Based on the clinical presentation, the key consideration was whether the mediastinal mass represented a de novo leiomyosarcoma or late metastatic disease from the spindle cell tumor of the lower limb excised six years back. However, his past medical history favored a metastatic spread. Leiomyosarcoma is well known for its bizarre nature and tends to cause late metastasis years after initial treatment with curative intent [4]. Lungs, liver, bone, and pleura serve as well recognized metastatic sites [5]. Many factors contribute to the scarcity of primary leiomyosarcoma originating in the thorax. Considering the anatomy of the thoracic cavity, the mediastinum with its minimal amount of smooth muscles, provides an unfavorable environment for tumor growth. However, smooth muscles in the great vessels, esophagus, and bronchi may serve as potential primary sites for tumor development [6].

On imaging, a primary leiomyosarcoma typically presents as a solitary, well-defined mass confined to a single organ or a structure. In contrast, a metastatic leiomyosarcoma in the thoracic cavity may involve adjacent structures presenting as multiple lung nodules, pleural effusions with malignant cytology, pleural thickening, or a mediastinal mass with necrosis. This aligns with our patient who had left upper lobe nodules with malignant pleural effusion in addition to the anterior mediastinal mass. The bronchoscopy, which showed extrinsic compression only, further argues against the possibility of primary bronchogenic carcinoma.

Histopathology, which was consistent with a malignant spindle cell neoplasm, was further confirmed by positive immunohistochemical markers including smooth muscle actin (SMA), desmin, and h-caldesmon, and negative markers such as cytokeratins and S-100 [7].

Management of metastatic leiomyosarcoma warrants a multi multidisciplinary approach. Pleural effusion due to metastatic deposits is managed with drainage and pleurodesis to prevent recurrence as performed in this patient. Systemic therapy for spindle cell sarcomas includes a histology driven approach. Combination chemotherapy with anthracycline-based regimens is associated with higher response rates, although increased toxicity remains a major limiting factor. One such combination is doxorubicin and ifosfamide. Gemcitabine-based chemotherapy (often gemcitabine + docetaxel) is considered effective where anthracycline agents are not tolerated [8]. Evidence from retrospective studies have demonstrated that metastasectomy (surgical resection of metastases), especially in the lung, can be considered in carefully selected patients [9]. Emerging agents such as pazopanib, an oral multi-tyrosine-kinase inhibitor and

trabectedin, a marine-derived alkylating agent, offer alternative therapy for advanced disease (5). Since most metastatic leiomyosarcomas are not curable, palliative care measures play an important role, along with follow-up and monitoring.

Conclusion

This case illustrates a rare occurrence of an anterior mediastinal spindle cell tumor with massive malignant pleural effusion in a patient previously treated for lower extremity leiomyosarcoma. The six-year interval between the initial presentation and recurrence highlights the importance of long-term surveillance and follow-up. Diagnostic accuracy was achieved through a comprehensive evaluation including imaging, pleural fluid analysis, tissue biopsy, and advanced histopathological techniques. Early diagnosis facilitates optimal management through a multidisciplinary approach.

References

1. Al M, Elgohary H, Abbas Y, Al Saadi M. Spindle cell leiomyosarcoma of gluteal muscle: a case report. Am J Surg Clin Case Rep. 2021;4:1-5. https://doi.org/10.47829/AJSCCR.2021.4203
2. Cordeiro M, Casanova JM, Rodrigues J, Freitas J, Fonseca R, Caetano de Oliveira R, et al. Long-term response after 94 cycles of trabectedin in a patient with metastatic leiomyosarcoma of the lower extremity. Case Rep Oncol. 2020;13(1):113-9. https://doi.org/10.1159/000505393
3. Burt M, Ihde JK, Hajdu SI, Smith JW, Bains MS, Downey R, et al. Primary sarcomas of the mediastinum: results of therapy. J Thorac Cardiovasc Surg. 1998;115(3):671-80. https://doi.org/10.1016/S0022-5223(98)70333-2
4. Mousavi Seresht L, Farhadi Dehkordi AR, Danesh Shahraki A, Mohammadizadeh F, Haghollahi F. Which behavior of myomatous masses is diagnostic for leiomyosarcoma: How do you clinically differentiate between leiomyoma and leiomyosarcoma? A case report. J Obstet Gynecol Cancer Res. 2024;9(4):475-8. https://doi.org/10.30699/jogcr.9.4.475
5. Demicco EG, Maki RG, Lev DC, Lazar AJ. New therapeutic targets in soft tissue sarcoma. Adv Anat Pathol. 2012;19(3):170-80. https://doi.org/10.1097/PAP.0b013e318253462f
6. Collaud S, Aigner C. A case report of a giant middle mediastinal leiomyosarcoma. Mediastinum. 2022;6:38. https://doi.org/10.21037/med-21-44
7. Hisaoka M, Wei-Qi S, Jian W, Morio T, Hashimoto H. Specific but variable expression of h-caldesmon in leiomyosarcomas: an immunohistochemical reassessment of a novel myogenic marker: An immunohistochemical reassessment of a novel myogenic marker. Appl Immunohistochem Mol Morphol. 2001;9(4):302-8. https://doi.org/10.1097/00129039-200112000-00003
8. Serrano C, Arregui M, Carrasco I, Hindi N, Martínez-Trufero J, Martínez-García J, et al. SEOM-GEIS Spanish clinical guidelines for the management of soft tissue sarcomas (2024). Clin Transl Oncol. 2025;27(4):1460-71. https://doi.org/10.1007/s12094-024-03842-5

9. Delisle M, Alshamsan B, Nagaratnam K, Smith D, Wang Y, Srikanthan A. Metastasectomy in leiomyosarcoma: A systematic review and pooled survival analysis. Cancers (Basel). 2022;14(13):3055. https://doi.org/10.3390/cancers14133055