Journal of the Postgraduate Institute of Medicine 2026; 13(1): E305 1-4
https://doi.org/10.4038/jpgim.8645

Case Report

Ansa Pancreatica: A rare pancreatic duct variation leading to idiopathic recurrent acute pancreatitis

A R M Isthiyak[1,2], Malith Nandasena[2]

[1]Postgraduate Institute of Medicine, University of Colombo, [2]Colombo South Teaching Hospital

Key words: Pancreatic duct, Pancreatitis, Cholangiopancreatography, Magnetic Resonance, Ansa pancreatica

Corresponding Author: A R M Isthiyak, E-mail< dristhiyak@gmail.com >

https://orcid.org/0009-0001-1831-2331

Received: 27 Jun 2026, Accepted revised version: 08 Oct 2026, Published: 26 Nov 2026

Competing Interests: Author has declared that no competing interests exist

© Authors. This is an open-access article distributed under a Creative Commons Attribution-Share Alike 4.0 International License (CC BY-SA 4.0), which permits unrestricted use, distribution, and reproduction in any medium, provided the original author and source are attributed and materials are shared under the same license.

Introduction

Pancreatic duct developmental anomalies lead to variations in its course and configurations. Ansa pancreatica is a rare pancreatic duct anomaly where the duct of Santorini forms a loop or S-shape as it joins the duct of Wirsung, resulting in impedance to the flow of pancreatic juice and predisposing to recurrent acute pancreatitis (Figure 1). The reported incidence of Ansa pancreatica ranges from approximately 0.5-1.2%, highlighting its rarity among pancreatic ductal anatomical variations [2].

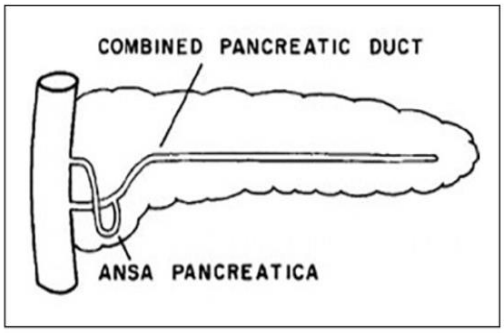

Figure 1: Ansa Pancreatica – S-shaped loop arising from MPD and joining the minor papilla

Recurrent acute pancreatitis (RAP) is defined as two or more episodes of acute pancreatitis that are fully resolved and it is a reversible condition. Recurrent attacks of acute pancreatitis, especially >3 episodes can lead to chronic pancreatitis, as evidenced by pancreatic duct dilation, atrophy and calcification [1].

There are numerous etiologies demonstrated for pancreatitis, but globally, common bile duct gallstones (38%) and alcohol abuse (36%) are the most common causes of acute pancreatitis [1]. Rapid advancement in knowledge and technology has contributed to the detection of structural abnormalities of the pancreatic duct as playing a major role in patients with recurrent acute pancreatitis. Among pancreatic duct abnormalities, pancreatic divisum is the most common congenital anatomical variant, reported in approximately 7% of autopsy series [1] and ansa pancreatica is the rarer and less commonly addressed variant [3].

This case report describes a presentation of recurrent acute pancreatitis secondary to ansa pancreatica in a young female with no history of alcohol consumption. To the best of our knowledge, no previously published report in Sri Lanka has described ansa pancreatica.

Case presentation

A 19-year-old female presented to emergency department with a chief complaint of an insidious onset of epigastric pain for 2 days, progressive in nature, that radiated to her back. The pain was typically aggravated during meals and relieved on bending forward. It responded well to paracetamol. The pain was associated with 3 episodes of non-bilious vomiting and vomitus contained food residues.

She had a 2-year history of similar abdominal symptoms for which she had three hospital admissions to date. Her initial investigations from the first admission revealed a haemoglobulin level of 10g/dL, white blood cell count (WBC) of $14x10^3/\mu L$, C-reactive protein (CRP) of 110 mg/L, serum amylase of 1256 U/L and alkaline phosphatase (ALP) of 400 U/L. The elevated serum amylase, CRP and WBC supported the diagnosis of acute pancreatitis and its associated inflammatory response, while the elevated ALP points toward a hepatobiliary pathology.

Radiological investigations were negative for gallstones or significant bile duct dilatation on ultrasound but showed an oedematous pancreas. A working diagnosis of acute pancreatitis was made, and she was managed medically with IV fluids and analgesics. Her condition improved clinically and biochemically over the next few days. Once the inflammation is settled, she was planned for a magnetic resonance cholangiopancreatography (MRCP), which revealed an S-shaped loop from the main pancreatic duct to the minor papilla.

Discussion

The normal pancreatic ductal system is formed by the fusion of the ventral duct (Wirsung's duct) and the dorsal duct (Santorini's duct) in the head of the pancreas.

Abnormal ductal fusion may cause many anatomic variations of pancreatic ducts such as ansa pancreatica. Ansa pancreatica was first described in the literature by Dawson and Langman in 1961.

Normally most of the pancreatic drainage occurs through the duct of Wirsung to the major papilla while a small proportion of pancreatic secretion is drained by the duct of Santorini to the minor papilla. Ansa pancreatica is a predisposing factor to recurrent pancreatitis due to many reasons, such as impedance to the flow of pancreatic juice and increased pancreatic ductal pressure. This is true for people taking alcohol [4]. The risk of acute and recurrent pancreatitis is higher in patients with ansa pancreatica (20%) versus the ones without it (0.52%) [5].

The diagnosis of chronic pancreatitis is made based on a history suggestive of recurrent episodes of upper abdominal pain with or without evidence of endocrine and exocrine failure. Radiologically, it is supported by pancreatic atrophy, calcification, and duct stricture & dilation. If there is no proof of histological or radiological or both, then the diagnosis of recurrent acute pancreatitis (RAP) will be made instead of chronic pancreatitis. In this case, diagnosis of ansa pancreatica was made based on MRCP findings. Although she had recurrent abdominal pain and raised serum amylase, there was no CT/MRI evidence of chronic pancreatitis. (Figure 2) The patient did not exhibit any evidence of endocrine or exocrine failure. Recent studies highlighted that the contribution of pancreatic ductal variations on the insufficiency of pancreatic exocrine function is still controversial [1].



Figure 2: MRCP depicts an S-shaped loop arising from MPD and joining the minor papilla

There is no specific treatment for ansa pancreatica described in the literature [6]. In this case, each episode of my patient's pancreatitis was a mild attack and was managed conservatively with hydration and analgesics. Subsequently, after a multi-disciplinary meeting, elective endoscopic sphincterotomy was performed to facilitate the drainage of pancreatic juices. Though chronic pancreatitis is a known complication of RAP, timely identification and early endoscopic intervention can prevent progression of the disease.

Every intervention carries its own complications; the decision to perform ERCP and endoscopic sphincterotomy must be carefully made, as there are dreadful complications like post-ERCP pancreatitis. The risk-benefit ration should be discussed in detail with the patient, taking into account the patient's clinical presentation, severity, and presence of other risk factors for pancreatitis [7].

Conclusion

Ansa pancreatica is a rare anatomic variant of the pancreatic ducts accounting for only about 1% in the literature [2]. Its presence should be investigated thoroughly, especially in idiopathic recurrent acute pancreatitis and steps taken to prevent chronic pancreatitis.

References

1. Wang GJ, Gao CF, Wei D, et al. Acute pancreatitis: etiology and common pathogenesis. World J Gastroenterol 2009;15:1427-30. https://doi.org/10.3748/wjg.15.1427
2. Kosirog JS, Boulay BR. Cemal Yazici Ansa Pancreatica. A Rare Cause of Acute Pancreatitis:Clinical Relevance and Review of the Literature Pancreas 2018;19:315-20. https://doi.org/10.11604/pamj.2020.37.202.23218
3. Akram S, Khan K, Zuberi BF, et al. Ansa pancreatica: a rare cause of recurrent acute pancreatitis. J Pak Med Assoc 2021;71: 757-9. https://doi.org/10.1259/bjrcr.20200044
4. Hussain SN, Malik MI, Khan SA. Case report on ansa pancreatica: an uncommon cause accounting for recurrent pancreatitis in children. Journal of Pakistan Medical Association. 2019;69(11). https://doi.org/10.5455/JPMA.29846
5. Hayashi TY, Gonoi W, Yoshikawa T, Hayashi N, Ohtomo K. Ansa pancreatica as a predisposing factor for recurrent acute pancreatitis. WJG 2016; 22: 8940-8. https://doi.org/10.3748/wjg.v22.i40.8940
6. Kleeff J, Whitcomb DC, Shimosegawa T, Esposito I, Lerch MM, Gress T, et al. Neoptolemos chronic pancreatitis. Nature 2017. https://doi.org/10.1038/nrdp.2017.60
7. Sotirios K, Dimitrios F, Panagiotis S: Ansa pancreatica. Review of the literature . Ital J Anat Embryol. 2019, 124:79-86. https://doi.org/10.13128/IJAE-25472