

CASE REPORT

DEATHS DUE TO RABIES IN SHIVAMOGGA, INDIA: CASE SERIES AND REVIEW

Navamani S*, Chidananda PS, Naik S, Veeresh MR

Department of Forensic Medicine and Toxicology, Shimoga Institute of Medical Sciences, Shivamogga, India

ABSTRACT


Rabies is a fatal disease and deaths due to this have been on the increase. This is due to a lack of awareness leading to failure to obtain proper treatment. We report five cases confirmed to be rabies virus positive, with Negri bodies in their neuronal tissues. Due to a lack of awareness, the individuals are failing to take proper postexposure prophylaxis. The people are avoiding going to health care hospitals as a result of which, after varying incubatory periods the individuals eventually are succumbing to the illness. They are exhibiting characteristic encephalitic symptoms, as a result of this deadly disease. Proper prevention and management, along with awareness among the people can decrease the fatality. Effective programs and continuous surveillance of rabid dogs, to effectively control their population and vaccinate them on a consecutive basis, can combat the virus and stop its spread.

Keywords: *Canine species; Negri bodies; Post-exposure prophylaxis; Rabies encephalitis; India*

Corresponding author: Navamani S*
navamanishefali@gmail.com
ORCID iD: <https://orcid.org/0009-0002-0079-5256>

ARTICLE HISTORY

Received: 04.09.2023 Received in revised form: 18.10.2023
Accepted: 12.12.2023 Available online: 22.12.2023



This article is licensed under the terms of the Creative Commons Attribution-Non Commercial 4.0 International License.

INTRODUCTION

Rabies is a vaccine-preventable viral disease that is occurring worldwide in huge numbers. It affects more than 150 countries in almost all continents except Antarctica, and it is an almost 100% fatal disease once the clinical symptoms appear^{1,2}. It is estimated that around 59,000 deaths every year due to this fatal disease have occurred. Children between the age group 5 and 14 years are frequent victims¹. It is estimated that 90% of human rabies exposure and 99% of human rabies death is due to exposure to rabid dogs³. In India, the burden of rabies is not fully known, but it is reported that around 18,000 to 20,000 deaths occur every year,

constituting 36% of world rabies deaths⁴. The main objective of this report is to discuss five rabies-confirmed cases in the district and aims to find out the reasons for the sudden increase in rabies deaths.

METHODS

A total of 12,616 cases were subjected to autopsy from the year 2008 to 2023, out of which 5046 cases were subjected to microscopic examination. They were subjected to complete autopsy under special precautionary measures, and specimens of brain preserved in formalin and trigeminal ganglion preserved in viral transport medium (VTM) were sent for neuropathological and neuro-virological examination to the National Institute of Mental Health and Neurosciences (NIMHANS), Bangalore, Karnataka, India. The histopathology of the specimens was done by staining them with haematoxylin-eosin. The autopsy findings were documented along with the detailed history of the cases from the police and relatives of the deceased.

OBSERVATIONS

Case 1

A 71-year-old male with a previous history of dog bite 14 days back, came with symptoms of hydrophobia and aerophobia, after which he expired

within a day of treatment (Table 1). At autopsy, he had multiple old healed scars over his left leg and all the internal organs showed congestion. The brain showed no gross abnormalities except for mild cerebral oedema and tonsillar herniation. Microscopically, there were numerous neuronal intracytoplasmic inclusion bodies (Negri bodies) in the cerebral cortex, cerebellum (Fig 1, 2, 3), and brainstem.

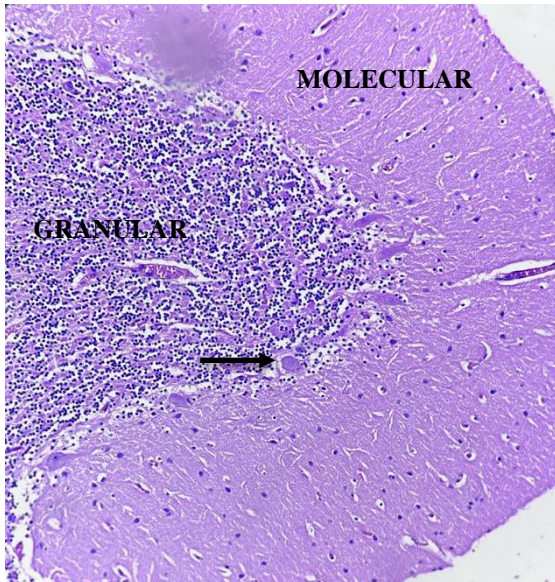


Fig. 1: Negri bodies in the cytoplasm of Purkinje cells of the cerebellum (black arrow) (H&E x10).

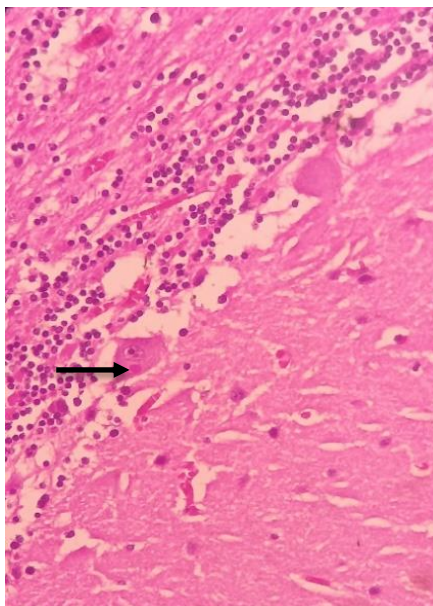


Fig. 2: Negri body inside Purkinje cell (black arrow) (H&E x40).

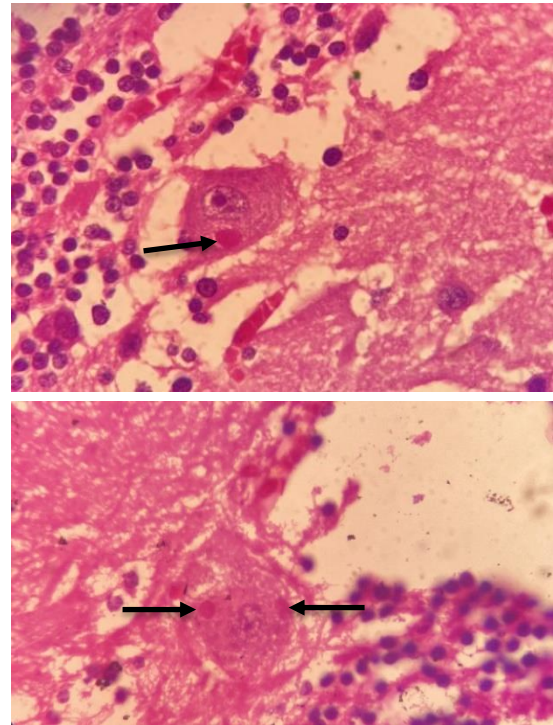


Fig. 3: Negri bodies inside Purkinje cells (black arrow) (H&E x100)

Case 2

A 16-year-old male with a history of dog bite 23 days back succumbed to his illness within one day after developing hydrophobia and aerophobia (Table 1). The brain was intensely congested and oedematous and other organs also showed congestion.

Case 3

A 40-year-old male with complaints of hydrophobia and aerophobia gave a history of dog bite several months back. At autopsy, the brain was deeply congested along with the other organs. Microscopically, there was diffuse cerebral oedema with ischemic changes (Table 1).

Case 4

A 30-year-old male came with complaints of aerophobia and hydrophobia after an alleged history of dog bite to his leg three months back. At autopsy, all the organs were congested (Table 1).

Case 5

A 43-year-old female, alleged to have been bitten by a cat four months back, for which she had taken a tetanus toxoid injection, expired after developing aerophobia. At autopsy, the brain was pale and showed petechial hemorrhages (Table 1).

Table 1: Demographic, clinical details, neuropathology, and neurovirology findings of the patients.

No.	Age in years/ sex	Type of rabies variant/ type of animal	Postexposure prophylaxis given/not given.	Incubation period	Period of survival after clinical symptoms (days)	Neuro-histopathology findings	Neuro-virology findings
1	71/M	En/Dog	Not given	14 days	1 day	Rabies encephalitis with neuronal viral inclusion bodies in the cerebral cortex, cerebellum, and brainstem.	Positive for rabies viral RNA.
2	16/M	En/Dog	Not given	23 days	1 day	Rabies encephalitis with neuronal viral inclusion bodies in the cerebral cortex, cerebellum, and brainstem.	Positive for rabies viral RNA.
3	40/M	En/Dog	Not given	Several months	1 day	Viral inclusions representing Negri bodies of rabies in multiple neuronal zones.	Positive for rabies viral RNA.
4	30/M	En/Dog	Not given	Three months	2 days	Rabies encephalitis with neuronal viral inclusion bodies in the cerebellum.	Positive for rabies viral RNA.
5	43/F	En/Cat	TT alone given	Four months	2 days	Purkinje cells show round to oval eosinophilic intracytoplasmic inclusions (Negri bodies).	Positive for rabies viral RNA.

M: Male; F: Female; En: Encephalitic; RNA: Ribonucleic acid.

DISCUSSION

The age group affected due to this virus was of a wide range in our cases. The animals causing the disease were dogs, and a cat in one of the cases. All the individuals experienced the characteristic symptoms of rabies and had varying incubation periods. The neuropathological and neurovirological findings were suggestive of rabies virus. The varying incubation periods, the causative animals, and the reasons for the sudden increase in this disease will be discussed further. The Rabies virus belongs to the Rhabdovirus family and it has a unique morphology of having a bullet shape. It is an enveloped virus and its nucleocapsid has a helical symmetry. It has two major antigens- Glycoprotein-G and Nucleocapsid⁵. The incubation period of this deadly virus is one to three months. In our cases, the incubation period ranged from fourteen days to four months. But rare cases such as less than two weeks

or more than one year also have been reported⁶. The virus has two variants- Encephalitic or Furious, which accounts for 80% of Rabies cases, and Paralytic variant, which accounts for 20% of cases. The Encephalitic variant shows characteristic features of autonomic dysfunction and episodes of agitation and aggressive behaviour. The patient develops aerophobia and hydrophobia, as seen commonly in our cases, further substantiating that the rabies virus causes early brainstem dysfunction. The Paralytic variant usually lacks these characteristic symptoms, but they pose challenges for physicians in differentiating them from Guillain-Barre Syndrome, as they show the same pattern of ascending paralysis^{6,7,8}. The average survival is five days for the Encephalitic variant and thirteen days for the Paralytic variant⁸.

There is even a case known to have an incubation period of 25 years in India, further raising the concern about the virus' erratic incubatory intervals⁹. All cases conducted by us showed a similar pattern of history, wherein none of the individuals took immediate recommended treatment such as post-exposure prophylaxis. Four out of five cases were caused due to dog bites and one case was due to a cat bite. This further concludes that; dogs are not the only reservoirs of this fatal virus and any mammal including foxes serve as carriers/ reservoirs¹⁰.

At autopsy, not many changes were noted grossly except for brain oedema and congestion of all the organs. Microscopically, the characteristic eosinophilic intracytoplasmic inclusion bodies (Negri bodies) were found in the neurons. All the cases showed positivity for rabies viral RNA.

Studies of these Negri bodies have shown that they are most commonly predominant or can be easily found in Purkinje cells, hippocampal pyramidal cells, and brainstem nuclei⁸. They are bodies varying from 2 to 10 µm, and they consist of a mass of nucleocapsids surrounded by viral particles budding from intracytoplasmic membranes¹¹. It is further studied that these bodies are usually found in areas devoid of inflammation¹².

The positive diagnosis of rabies seems to pose challenges for physicians, as there are difficulties in diagnosing it antemortem. Post-mortem samples seem to be promising. An audit from a clinical laboratory was taken regarding rabies in India, wherein 128 patients were followed up⁷. Antemortem samples such as cerebrospinal fluid (CSF), serum, saliva, and nuchal skin biopsy were taken. Postmortem brain tissue was taken into the study. Laboratory tests could confirm rabies in 40.6% of suspected cases and postmortem samples gave almost 100% sensitivity and specificity⁷.

CT and MRI have shown to be of some importance in the antemortem diagnosis, by looking into the hypodense and ill-defined hyperintensity lesions in various neuronal zones¹³. There are various antemortem laboratory tests available for the diagnosis, however, their limitations are to be taken into consideration, with a focus on their sensitivity and specificity. The tests done are Direct Fluorescent Antibody Test (DFA) on corneal smear (Antigen), DFA on skin biopsy, RT-PCR on saliva for viral nucleic acid, Real-time PCR on saliva for viral nucleic acid, Virus isolation from saliva by Rabies Tissue Culture Infection Test (RTCIT), Antibody detection in serum/CSF by Rapid Fluorescent Focus Inhibition

Test (RFFIT)¹³. The postmortem samples subjected to histopathology can be stained with haematoxylin and eosin, Sellers stain, Eosin Methylene Blue stain, or stains based on Methylene Blue along with immune-histochemistry for easier visualization of the Negri bodies^{14,15}.

The management and prevention of rabies is important to face the fatality of this virus. The Government of India has launched the National Rabies Control Programme (NRCP) for the prevention and control of rabies. The Ministry of Fisheries Animal Husbandry & Dairying and the Ministry of Health & Family Welfare jointly launched 'The National Action Plan For Dog Mediated Rabies Elimination (NAPRE) from India by 2030. The main objectives of the NRCP are to provide rabies vaccine and immunoglobulin, training on animal bite management, prevention, and control, strengthen the reporting of animal bite events, and create awareness about rabies prevention. The NAPRE has framed the Animal Birth Control Rules, 2023, to combat the population of stray dogs¹⁶. The NAPRE has also proposed strategies for the human health component, which includes encouragement of pre-exposure prophylaxis for High-Risk Groups, to formulate protocols for the safety of health workers/professionals exposed to an environment conducive to rabies virus transmission¹⁷.

It has been noted that before the COVID lockdown, cases of rabies reported were nil from our centre. However, we could see a rapid rise in its number which could be due to the COVID-19 lockdown allowing free movement of canines and an increase in the number of cases. A study stated that human rabies cases had resurfaced in countries like Brazil, Bhutan, Lebanon, Afghanistan, Jordan, Philippines, South Africa, Sri Lanka, USA, and India after the lockdown, and it could be due to pet dog abandonment, decreased human–dog contact, and starvation of street dogs during lockdown which further added to the stray dog menace¹⁸.

Compulsory post-exposure prophylaxis and awareness among the public are lacking, especially in rural areas, where they tend to go for home remedies or succumb to superstitious beliefs. The current medicine era is developing at a faster rate, wherein many new treatment methods are being implemented. There is even a case where a 15-year-old girl who was bitten by a bat, was induced into a coma for almost a month as a part of a treatment procedure according to the 'Milwaukee Protocol' in 2004¹⁹.

Hence, appropriate measures need to be taken, to prevent the untoward consequences of this deadly virus. The WHO has devised three interventions for the prevention and management of rabies. The first point talks about the awareness of rabies disease prevention and management among the public and understanding when rabies needs to be suspected and what needs to be done to prevent and take care of oneself. The second point emphasizes the Post-exposure Prophylaxis which consists of a series of rabies vaccines, and appropriate wound management. The third point talks about the mass dog vaccination, in which we can combat the virus at its root source since dogs account for about 99% of rabies exposure²⁰.

The limitation of our study is that detailed history was lacking and immune-histochemistry methods to demonstrate the viral inclusions could have been present.

CONCLUSION

Rabies deaths have been on the increase recently in India. The only way to overcome these incidents is to bring awareness to the society. They need to be aware of the control, prevention, and first aid measures in case of animal bites. The immediate admission of oneself to the health facility prevents deaths due to this fatal virus. Vigorous post-exposure prophylaxis needs to be given to the patients. Rural health setups need to be more vigilant on these matters, as the rural areas are the most affected by this disease. High-risk groups need to be more careful and stick to protocols of pre-exposure prophylaxis. Antemortem diagnostic methods need to be implemented and health professionals need to be trained on the management protocols. Awareness needs to be created among health professionals because dogs are not the only carriers of the virus and many more animals like cats, foxes, etc also play a role in it. Autopsy surgeons are required to send the appropriate samples for confirmation of these deaths, as it gives 100% sensitivity and specificity. Since the Government gives compensation to the deceased relatives, false claims need to be disproved by scientific methods.

ACKNOWLEDGEMENTS

None

CONFLICTS OF INTEREST

The authors declared no conflicts of interest.

ETHICAL ISSUES

None

SOURCES OF SUPPORT

None

AUTHOR CONTRIBUTIONS

SN1: Acquisition of data for the work; drafting the work; and final approval of the version to be published. **PSC:** Acquisition of data for the work; revising the draft critically for important intellectual content; and final approval of the version to be published. **SN2:** Revising the draft critically for important intellectual content; and final approval of the version to be published. **MRV:** Revising the draft critically for important intellectual content; and final approval of the version to be published.

REFERENCES

1. World Health Organization. *Rabies*. Available from: <https://www.who.int/news-room/fact-sheets/detail/rabies> [Accessed 14th July 2023].
2. Centers for Disease Control and Prevention. *Rabies*. Available from: <https://www.cdc.gov/rabies/index.html> [Accessed 14th July 2023].
3. Centers for Disease Control and Prevention. *Rabies around the world*. Available from: <https://www.cdc.gov/rabies/location/world/index.html> [Accessed 14th July 2023].
4. World Health Organization. *Rabies in India*. Available from: <https://www.who.int/india/health-topics/rabies> [Accessed 14th July 2023].
5. Shastry AS, Bhat S. Central Nervous System Infections. In: *Essentials of Medical Microbiology*. 3rd ed. Jaypee Brothers Medical Publishers; 2021:718-724.
6. Fauci AS, Braunwald B, Kasper DL, *et al*. Rabies and other Rhabdovirus Infections. In: *Harrison's Principles of Internal Medicine*. 17th ed. Vol. I. McGraw Hill; 2008:1222-1226.
7. Mani RS, Anand AM, Madhusudana SN. Human rabies in India: An audit from a rabies diagnostic laboratory. *Tropical Medicine & International Health*. 2016 Apr;21(4):556-63. <https://doi.org/10.1111/tmi.12669>.
8. Love S, Louis DN, Ellison DW. Viral Infections. In: *Greenfield's Neuropathology*. 8th ed. Vol. II. Edward Arnold (P) Ltd; 2008:1320-1323.

9. Shankar SK, Mahadevan A, Sapico SD, Ghodkirekar MS, Pinto RG, Madhusudana SN. Rabies viral encephalitis with a probable 25 year incubation period! *Annals of Indian Academy of Neurology*. 2012 Jul;15(3):221-3. <https://doi.org/10.4103/0972-2327.99728>.
10. Rao NA, Chidananda PS. Death due to Fox bite – Case report. *Journal of South India Medicolegal Association*. 2011;3:72-75.
11. Damjanov I, Linder J. Viral Diseases. In: *Anderson's Pathology*. 10th ed. Vol. I. Elsevier Publications. 2009;933.
12. Kumar V, Abbas AK, Fausto N. The Central Nervous System. In: *Robbins and Cotran Pathologic Basis of Disease*. 7th ed. Elsevier Publications. 2006;1375.
13. Madhusudana SN, Sukumaran SM. Antemortem diagnosis and prevention of human rabies. *Annals of Indian Academy of Neurology*. 2008 Jan;11(1):3-12. <https://doi.org/10.4103/0972-2327.40219>.
14. Beck S, Gunawardena P, Horton DL, et al. Pathobiological investigation of naturally infected canine rabies cases from Sri Lanka. *BMC Veterinary Research*. 2017 Apr 12;13(1):99. <https://doi.org/10.1186/s12917-017-1024-5>.
15. Harris DL. A Method for Staining Negri Bodies. *American Journal of Public Hygiene*. 1909 May;19(2):314-6.
16. *Prevention and control of Rabies in India*. Available from: <https://www.pib.gov.in/PressReleaseDetailm.aspx?PRID=1910410> [Accessed 14th July 2023].
17. Ministry of Health and Family Welfare. Government of India. *National Action Plan for Dog Mediated Rabies Elimination from India by 2030*. 2021. p. 28-30.
18. Goel K, Sen A, Satapathy P, et al. Human rabies control in the era of post-COVID-19: A call for action. *Journal of Travel Medicine*. 2023 Jan 28:taad009. <https://doi.org/10.1093/jtm/taad009>.
19. Willoughby RE Jr, Tieves KS, Hoffman GM, et al. Survival after treatment of rabies with induction of coma. *The New England Journal of Medicine*. 2005 Jun 16;352(24):2508-14. <https://doi.org/10.1056/NEJMoa050382>.
20. World Health Organisation. *Human rabies prevention and management*. Available from: <https://www.who.int/activities/human-rabies-prevention-and-management> (Accessed 12th September 2023).