DOI: https://doi.org/10.4038/slju.v17i1.4139

Sri Lanka Journal of Urology, 2026, **17**(1), 5-11

Original Article

Preoperative CT Urography in Newly Diagnosed Bladder Cancer: Is a Selective Approach Feasible?

Sivagnanasundarampillai T.[1], **Bright E.**[1], **Idhrees I. H.**[2]

[1]Department of Urology, Royal Cornwall Hospital, Truro, United Kingdom.
[2]District General Hospital, Trincomalee, Sri Lanka.

Abstract

Introduction: European Association of Urology (EAU) guidelines recommend a selective approach to preoperative CT urography (CTU) in newly diagnosed bladder cancer (BC) to exclude synchronous upper urinary tract tumours (UUTTs), reserving it for trigone, multiple, or high-risk tumours. In routine practice a universal approach is frequently adopted despite a low yield. We determined the yield of preoperative CTU and the clinicopathological factors associated with synchronous UUTTs.

Methods: Retrospective case-note review of patients with new BC diagnosed at transurethral resection of bladder tumour (TURBT) over 12 months; recording patient demographics, tumour characteristics and preoperative CTU results. Associations between synchronous UUTT and BC tumour grade, stage (≤T1 vs ≥T2), and location (trigone vs non-trigone) were assessed with Fisher's exact test, with a p value <0.05 considered statistically significant.

Results: 206 patients (male n=162, female n=44; age range 43-95 years, mean age 76.1 years) were analysed. Tumour location was trigone (n=46), lateral wall (n=82), posterior wall (n=35), bladder neck (n=21) and diffuse multifocal (n=72). Tumour size measured ≤1 cm (n=34), 1-3 cm (n=101) and >3 cm (n=71). 95% were urothelial carcinoma. CTU identified synchronous UUTTs in 3 patients (1.5%). All were high-grade tumours, ≥pT1 and located at the trigone. Synchronous UUTT was significantly associated with trigone location (3/46 vs 0/160, p=0.011). No significant association between synchronous UUTT and tumour grade (p = 0.554) or pathological stage (≤T2 vs ≥T1, p=0.579) was identified.

Conclusion: Synchronous UUTTs were uncommon and occurred exclusively in trigone tumours. Our findings align with EAU, NICE and AUA guidance and support a selective, risk-based use of preoperative CTU.

Keywords: Bladder cancer, CT urography, upper tract urothelial carcinoma, trigone, selective imaging

Introduction

Bladder cancer is the commonest malignancy of the urinary tract, and the great majority are urothelial carcinomas that share a common field-change biology along the entire urothelium (1). Because this field effect extends to the renal pelvis and ureter, a minority of patients harbour a synchronous upper urinary tract tumour (UUTT) at the time of bladder cancer diagnosis. Detecting such a lesion preoperatively alters the operative plan, may upstage the patient, and influences the decision between organ-sparing and radical surgery (2).

CT urography (CTU) is the reference imaging test for the upper tract, with a pooled sensitivity and specificity of approximately 92% and 95% respectively for upper-tract urothelial carcinoma, outperforming ultrasonography and intravenous urography for papillary lesions (3,4). However, the overall incidence of synchronous UUTT in newly diagnosed bladder cancer is low – reported at approximately 1.8% – rising to around 7.5% when the index tumour involves the trigone (1). On this basis the EAU recommends a selective rather than universal approach, reserving CTU for tumours of the trigone or those that are multiple or high-risk (1).

Despite this, universal CTU remains common. Large series confirm the low yield of upper-tract imaging: in a prospective multicentre haematuria cohort the incidence of upper-tract urothelial carcinoma was only 0.8% with macroscopic and 0% with microscopic haematuria (5). Routine surveillance urography has likewise been shown to be unnecessary in long-term follow-up (6,7). Where CTU prompts diagnostic ureteroscopy, this can delay definitive surgery and increase intravesical recurrence, a finding demonstrated in our own institutional series (8). We therefore audited the yield of preoperative CTU in a consecutive UK cohort and examined which clinicopathological factors predict a synchronous UUTT.

Methods

Study design and population

We performed a retrospective case-note review of all patients with newly diagnosed bladder cancer confirmed at TURBT at a single tertiary urology centre over a 12-month period. Patient demographics, tumour characteristics (location, size, grade, pathological stage, histological type) and the results of preoperative CTU were extracted from electronic records and histopathology reports. Patients with a prior history of urothelial carcinoma were excluded so that detected upper-tract lesions could be classified as synchronous.

Definitions

A synchronous UUTT was defined as a pelvicalyceal or ureteric urothelial lesion identified on the preoperative CTU performed at the time of bladder cancer diagnosis. Tumour location was dichotomised as trigone versus non-trigone, and stage as non-muscle-invasive (≤T1) versus muscle-invasive (≥T2), consistent with EAU risk descriptors (1).

Statistical analysis

Continuous variables are summarised as mean and range; categorical variables as counts and percentages. Associations between synchronous UUTT and trigone location, tumour grade, and pathological stage were tested using Fisher's exact test, which is appropriate here because the expected cell counts were small and one cell (non-trigone UUTT) was zero – conditions under which the chi-squared approximation is unreliable. A two-sided $p<0.05$ was considered statistically significant. Analyses were performed in R with cross-verification of exact p-values.

Results

206 patients were analysed (162 male, 44 female; male-to-female ratio approximately 3.7:1), with a mean age of 76.1 years (range 43-95), confirming the expected elderly, male-predominant demographic of bladder cancer. Urothelial carcinoma accounted for 95% of tumours, with the remainder comprising squamous and other variant histologies. The full demographic, clinical and tumour profile is detailed in Table 1, with patient demographics in Figure 1 and tumour characteristics in Figure 2. Tumour location was recorded per site rather than per patient, because multifocal tumours involved more than one region; the resulting 256 site records (from 206 patients) reflect this. The lateral wall was the commonest single site (82 sites), followed by diffuse/multifocal disease (72) and the trigone (46); posterior wall (35) and bladder neck (21) were less frequent. Most tumours measured 1-3 cm (49.0%).

Table 1. Demographic, clinical and tumour characteristics of the study cohort (N = 206 patients)

Characteristic	n	%
Sex		
Male	162	78.6
Female	44	21.4
Age (years)		
Mean (range)	76.1	43-95

(Continued)

Characteristic	n	%
Tumour location (by site; n = 256 sites)[a]		
Lateral wall	82	32.0
Diffuse / multifocal	72	28.1
Trigone[b]	46	18.0
Posterior wall	35	13.7
Bladder neck	21	8.2
Tumour size (greatest dimension)		
≤ 1 cm	34	16.5
1-3 cm	101	49.0
> 3 cm	71	34.5
Histological type		
Urothelial carcinoma	196	95.0
Non-urothelial / variant	10	5.0
Preoperative CT urography outcome		
Synchronous UUTT detected	3	1.5
No synchronous UUTT	203	98.5

HG, high grade; SCC, squamous cell carcinoma; UUTT, upper urinary tract tumour.

[a] Location is reported per tumour site, not per patient: tumours involving more than one region were counted at each region, so site counts (n = 256) exceed the number of patients (N = 206). Percentages in this block are of total sites.

[b] Trigone involvement was the only factor significantly associated with synchronous UUTT (see Table 2).

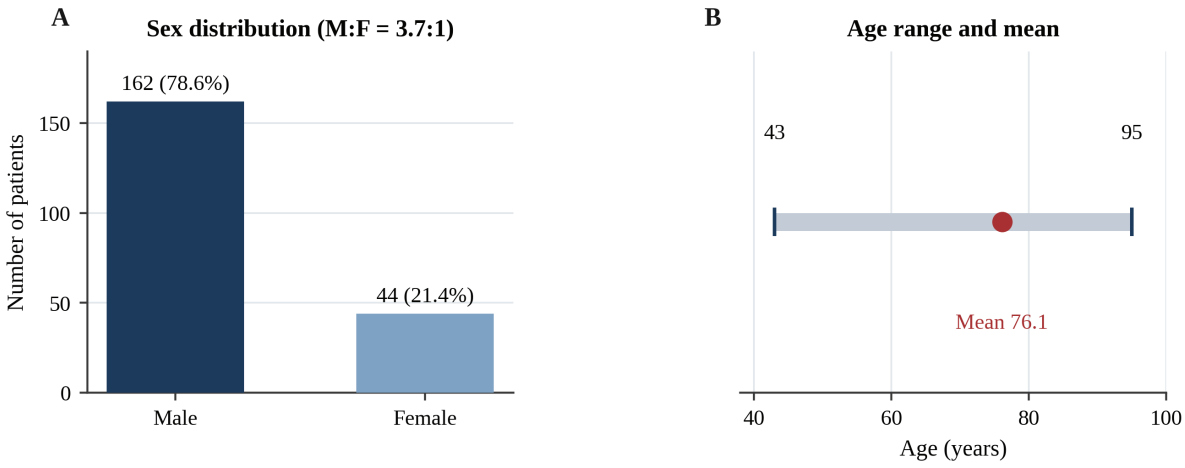

Figure 1. *Patient demographics (N = 206). (A) Sex distribution. (B) Age range and mean.*

CTU identified a synchronous UUTT in 3 of 206 patients, an overall yield of 1.5%. All three lesions occurred in patients whose bladder tumour involved the trigone; none were found among the 160 patients with non-trigone tumours (Figure 3). All three lesions occurred in patients whose bladder tumour involved the trigone. All three were high-grade and ≥pT1.

On Fisher's exact testing, synchronous UUTT was significantly associated with trigone location (3/46 vs 0/160, p=0.011). No significant association was found with tumour grade (p=0.554) or with pathological stage (≥T2 vs ≤T1, p=0.579) (Table 2, Figure 4). The trigone yield of 6.5% (3/46) closely matches the ≈7.5% figure cited in EAU guidance, while the non-trigone yield of 0% supports the safety of omitting routine CTU in that group (1,2).

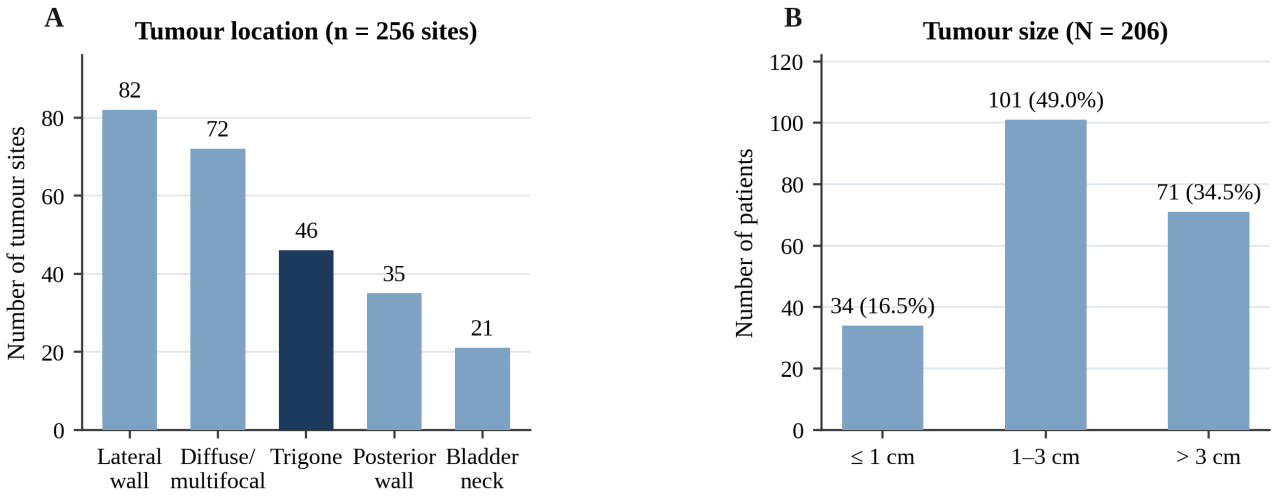

Figure 2. *Tumour characteristics. (A) Tumour location by site (n = 256 sites). (B) Tumour size (N = 206 patients).*

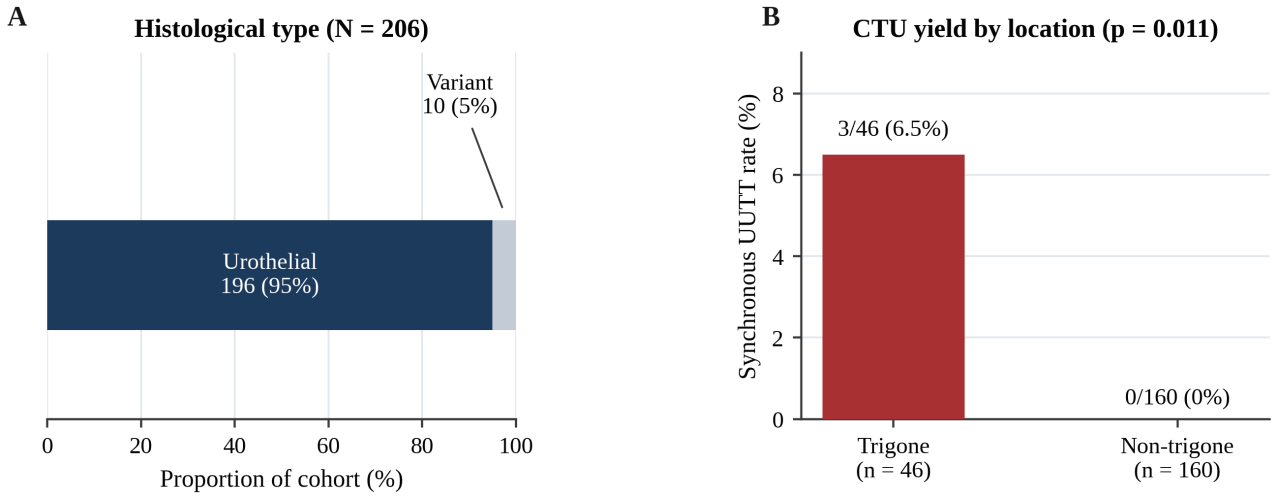

Figure 3. *Histology and synchronous UUTT yield. (A) Histological type. (B) CTU yield by bladder tumour location (Fisher's exact test, p=0.011).*

Table 2. Association of clinicopathological factors with synchronous UUTT (Fisher's exact test)

Factor	UUTT+ / total	p-value
Trigone vs non-trigone	3/46 vs 0/160	0.011
High grade vs low grade	-	0.554
Stage ≥T2 vs ≤T1	-	0.579

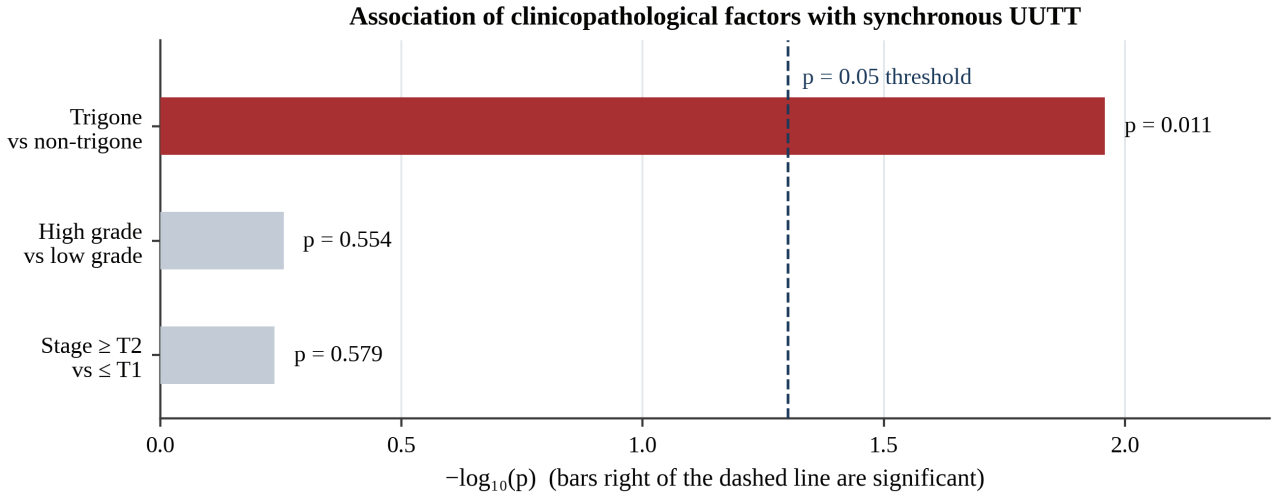

Figure 4. *Association of clinicopathological factors with synchronous UUTT, expressed as -log$_{10}$(p). Bars to the right of the dashed line meet the p < 0.05 threshold.*

Discussion

In this consecutive cohort, the yield of preoperative CTU for synchronous UUTT was 1.5%, and every positive case arose from a trigone tumour. This reproduces, in a real-world UK dataset, the central premise of EAU guidance: that the baseline risk of synchronous upper-tract disease is low (≈1.8%) but concentrates in trigone tumours (≈7.5%) (1,9). The statistically significant association with trigone location, alongside the absence of any association with grade or stage, indicates that anatomical site is the dominant, and clinically actionable, predictor in this series. The yield is closely comparable to the 1.7% reported in an earlier UK series that reached the same conclusion (10).

A plausible mechanism links the trigone to the upper tract. The trigone and the intramural ureter share a contiguous urothelial lining and a common embryological origin from the mesonephric (Wolffian) ducts; a field-change carcinogenic insult acting at the ureteric orifices may therefore predispose to concurrent disease at the distal ureter and beyond (2,11). This anatomical reasoning underpins why a periorificial trigone tumour, rather than tumour grade per se, flags upper-tract risk, and is consistent with established risk-group stratification for UUTT after bladder cancer (12).

The clinical case for selectivity is strengthened by the harms of universal imaging. CTU delivers a radiation and iodinated-contrast load and generates incidental findings that drive further testing and cost, while large prospective data confirm a very low upper-tract cancer yield, particularly in lower-risk presentations (5). Routine upper-tract surveillance imaging is similarly low-yield, with most recurrences detected through symptoms or cytology rather than scheduled scans (6,7). Furthermore, where CTU triggers diagnostic

ureteroscopy, our own institutional data show this delays definitive surgery and is associated with increased intravesical recurrence – a further argument against indiscriminate upper-tract investigation (8).

Our findings are concordant across guideline bodies. The EAU, NICE and AUA all endorse risk-stratified rather than universal upper-tract imaging (1,13,14). The companion EAU upper-tract guideline similarly frames CTU within a risk-based diagnostic pathway (11). A selective strategy would have safely avoided CTU in the 160 non-trigone patients here without missing a single synchronous UUTT.

Limitations include the retrospective, single-centre design and the small number of UUTT events, which widens the confidence around the grade and stage comparisons and means a true but modest effect cannot be excluded. The duplicate counting of multifocal tumours across location categories complicates the denominator for site-specific rates and should be standardised in prospective work. CTU also carries a recognised false-negative rate for small or flat upper-tract lesions, so a negative scan does not wholly exclude disease (3). Repeat resection and structured pathological staging further refine risk stratification and would strengthen future prospective evaluation (15). Larger multicentre cohorts, ideally with cost-effectiveness modelling, would help define the optimal selective threshold.

Conclusion

Synchronous UUTTs were uncommon (1.5%) and occurred exclusively in trigone tumours, which were significantly associated with upper-tract disease while grade and stage were not. These results align with EAU, NICE and AUA guidance and support a selective, risk-based approach to pre-operative CTU – reserving it principally for trigone, multiple, and high-risk tumours – thereby reducing radiation, contrast exposure, incidental findings and cost without compromising detection.

References

1. Babjuk M, Burger M, Capoun O, et al. European Association of Urology Guidelines on Non-muscle-invasive Bladder Cancer (Ta, T1, and Carcinoma In Situ). Eur Urol. 2022; 81(1): 75-94. doi:10.1016/j.eururo.2021.08.010
2. Jinzaki M, Kikuchi E, Akita H, Sugiura H, Shinmoto H, Oya M. Role of computed tomography urography in the clinical evaluation of upper tract urothelial carcinoma. Int J Urol. 2016; 23(4): 284-98. doi:10.1111/iju.13032.
3. Janisch F, Shariat SF, Baltzer P, et al. Diagnostic performance of multidetector computed tomographic urography in upper tract urothelial carcinoma: a systematic review and meta-analysis. World J Urol. 2020; 38(5): 1165-75. doi:10.1007/s00345-019-02875-8.
4. Cowan NC, Turney BW, Taylor NJ, McCarthy CL, Crew JP. Multidetector computed tomography urography for diagnosing upper urinary tract urothelial tumour. BJU Int. 2007; 99(6): 1363-70. doi:10.1111/j.1464-410X.2007.06766.x.
5. Tan WS, Sarpong R, Khetrapal P, et al; DETECT I Trial Collaborators. Can renal and bladder ultrasound replace computerized tomography urogram in patients investigated for microscopic hematuria? J Urol. 2018; 200(5): 973-80. doi:10.1016/j.juro.2018.04.065.
6. Holmäng S, Hedelin H, Anderström C, Holmberg E, Johansson SL. Long-term followup of a bladder carcinoma cohort: routine followup urography is not necessary. J Urol. 1998;160(1):45-48. PMID: 9628602.
7. Hession P, Flynn P, Paul N, Goodfellow J, Murthy LN. Intravenous urography in urinary tract surveillance in carcinoma of the bladder. Clin Radiol. 1999; 54(7): 465-7. PMID: 10437700.
8. Hadi SHSM, Bright E, Mantle M, Munro N, Fahmy O. Diagnostic ureteroscopy in CT urography-diagnosed upper tract urothelial carcinoma: delay in definitive treatment and increased intravesical recurrence. Cureus. 2021; 13(6): e15775. doi:10.7759/cureus.15775
9. Palou J, Rodríguez-Rubio F, Huguet J, Segarra J, Ribal MJ, Alcaraz A, Villavicencio H. Multivariate analysis of clinical parameters of synchronous primary superficial bladder cancer and upper urinary tract tumour. J Urol. 2005; 174(3): 859-61. doi:10.1097/01.ju.0000169424.79702.6d
10. Bajaj A, Sokhi H, Rajesh A. Intravenous urography for diagnosing synchronous upper-tract tumours in patients with newly diagnosed bladder carcinoma can be restricted to patients with high-risk superficial disease. Clin Radiol. 2007; 62(9): 854-7. doi:10.1016/j.crad. 2007. 04.003

11. Rouprêt M, Seisen T, Birtle AJ, et al. European Association of Urology Guidelines on Upper Urinary Tract Urothelial Carcinoma: 2023 Update. Eur Urol. 2023; 84(1): 49-64. doi:10.1016/j.eururo.2023.03.013

12. Millán-Rodríguez F, Chechile-Toniolo G, Salvador-Bayarri J, Huguet-Pérez J, Vicente-Rodríguez J. Upper urinary tract tumors after primary superficial bladder tumors: prognostic factors and risk groups. J Urol. 2000; 164(4): 1183-7. doi:10.1016/S0022-5347(05)67137-6

13. National Institute for Health and Care Excellence. Bladder cancer: diagnosis and management. NICE Guideline NG2. London: NICE; 2015 (updated 2024).

14. Chang SS, Boorjian SA, Chou R, et al. Diagnosis and treatment of non-muscle invasive bladder cancer: AUA/SUO guideline. J Urol. 2016; 196(4): 1021-9. doi:10.1016/j.juro.2016.06.049.

15. Cumberbatch MGK, Foerster B, Catto JWF, et al. Repeat transurethral resection in non-muscle-invasive bladder cancer: a systematic review. Eur Urol. 2018; 73(6): 925-33. doi:10.1016/j.eururo.2018.02.014