DOI: https://doi.org/10.4038/slju.v17i1.4146

Sri Lanka Journal of Urology, 2026, **17**(1), 47-51

Case Series

Role of the Cardiothoracic Surgeon in the Multidisciplinary Surgical Management of Renal Cell Carcinoma with Supradiaphragmatic Inferior Vena Cava and Right Atrial Tumour Thrombus: A Case Series

Vinodhakumar B.[1], **Gnanakanthan K.**[2]

[1]Senior Registrar in Cardiothoracic Surgery, National Hospital of Sri Lanka.

[2]Consultant Cardiothoracic Surgeon, Cardiothoracic Surgery, National Hospital of Sri Lanka.

Abstract

Renal cell carcinoma with tumour thrombus extending into the supradiaphragmatic inferior vena cava and right atrium is rare and presents a major surgical challenge. We report two patients with Mayo level IV tumour thrombus managed through a multidisciplinary approach involving urological and cardiothoracic surgical teams. Both patients underwent radical nephrectomy, right atrial and inferior vena caval thrombectomy under cardiopulmonary bypass. One patient required concomitant coronary artery bypass grafting for significant left anterior descending artery disease. Complete tumour thrombus extraction was achieved without deep hypothermic circulatory arrest. These cases highlight the importance of cardiothoracic surgical involvement, meticulous operative planning, and multidisciplinary management in achieving safe surgical outcomes.

Keywords: Renal cell carcinoma, tumour thrombus, right atrial extension, cardiopulmonary bypass, multidisciplinary management

Introduction

Renal cell carcinoma (RCC) has a characteristic tendency for venous invasion, with tumour thrombus occurring in approximately 4-10% of patients. In a small proportion, the thrombus extends above the diaphragm into the right atrium, classified as Mayo level IV, representing a technically challenging form of locally advanced RCC (1). Surgical removal of the renal tumour and venous tumour thrombus remains the preferred treatment for appropriately selected patients without metastatic disease (1,2). Management of supradiaphragmatic and right atrial tumour thrombus requires meticulous multidisciplinary planning, with cardiothoracic surgical involvement and cardiopulmonary bypass (CPB) often required to facilitate safe intracardiac tumour extraction (1,3).

Case presentation

Case 1

A 65-year-old woman with hypertension and dyslipidaemia presented with a four-month history of loss of appetite and exertional dyspnoea. Examination revealed pallor, bilateral lower-limb oedema, and a palpable left-sided ballotable loin mass. Her haemoglobin was 9.8 g/dL, and serum creatinine was 0.6 mg/dL. Contrast-enhanced computed tomography (CECT) demonstrated a left renal mass with tumour thrombus extending through the IVC to the supradiaphragmatic level, with right atrial extension on echocardiography (Figure 1).

Following multidisciplinary discussion, she underwent left radical nephrectomy and right atrial and IVC tumour thrombectomy under CPB. The

abdomen was approached through a rooftop incision, followed by median sternotomy and establishment of CPB through aortic and superior vena caval cannulation, with cooling to 28°C. Right atriotomy revealed tumour thrombus extending to the IVC-right atrial junction. An attempt was made to mobilise the thrombus from below; however, it was firmly adherent to the IVC and was subsequently mobilised from the right atrial aspect and removed completely in a piecemeal fashion. CPB time was 89 minutes, with an estimated blood loss of 3,005 mL.

The postoperative course was uneventful. Histopathological examination confirmed grade 2 clear cell RCC, pT3c pNx. She was referred to the oncology team for consideration of adjuvant treatment and remains under joint oncology and urology follow-up, with no evidence of local recurrence or distant metastasis at 12 months.

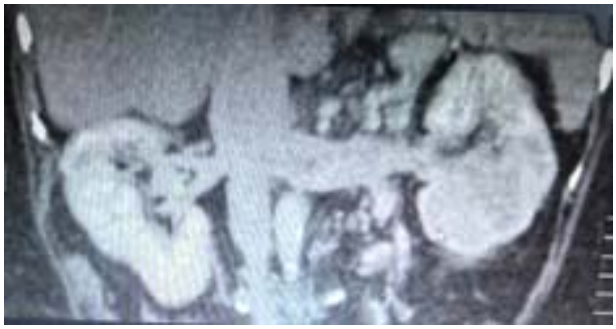

Figure 1. *Shows a left renal tumor with extension into the left renal vein and inferior vena cava.*

Case 2

A 68-year-old man with type 2 diabetes mellitus and dyslipidaemia presented with a three-week history of visible haematuria. Examination revealed pallor and a palpable right-sided ballotable loin mass. His haemoglobin was 8.4 g/dL, and serum creatinine was 3.2 mg/dL. CECT demonstrated a right renal mass with tumour thrombus extending through the IVC to the supradiaphragmatic level, with right atrial extension on echocardiography (Figure 2). Coronary angiography revealed significant LAD stenosis.

Following multidisciplinary assessment, he underwent right radical nephrectomy, IVC and right atrial tumour thrombectomy, and concomitant LIMA-to-LAD coronary artery bypass grafting under CPB. The kidney was approached through a rooftop incision, followed by median sternotomy and establishment of CPB. The patient was cooled to 25°C, and the LIMA was harvested and grafted to the LAD. Following right atriotomy and anterior cavotomy, the tumour thrombus was mobilised and completely extracted from the IVC and right atrium under direct vision without DHCA (Figure 3). Histopathological examination confirmed grade 3 clear cell RCC with pT3c pN0 disease. He was referred to the oncology and urology teams for continued follow-up; however, he was subsequently lost to follow-up 8 months after surgery.

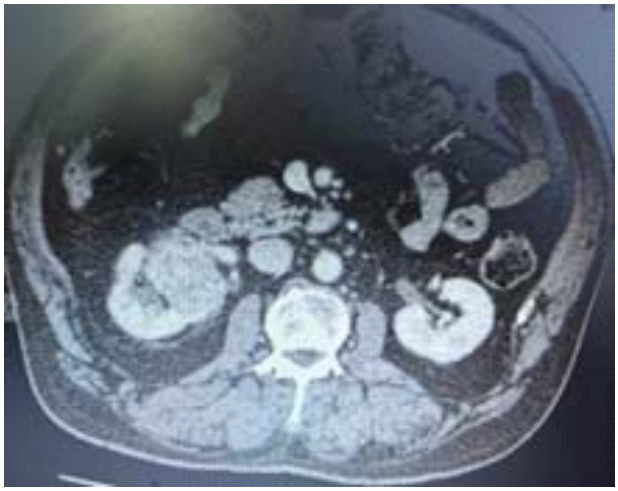

Figure 2. *Imaging demonstrating the right renal tumour with extension into the inferior vena cava (IVC).*



Figure 3. *Extracted tumour thrombus from IVC and right atrium.*

Discussion

Renal cell carcinoma (RCC) with venous tumour thrombus extending into the inferior vena cava (IVC) represents a distinct surgical challenge. Extension above the diaphragm into the right atrium, classified as Mayo level IV tumour thrombus, is particularly demanding because it requires management of both the extensive venous tumour burden and the cardiovascular consequences of intracardiac extension. Although venous tumour thrombus is present in approximately 4-10% of patients with RCC, right atrial extension is uncommon. In appropriately selected patients without unresectable metastatic disease, radical nephrectomy with complete tumour thrombectomy remains the principal potentially curative treatment (1,2).

The major message of this case series is the importance of multidisciplinary planning for Mayo level IV disease. These procedures require close coordination between urological, cardiothoracic, vascular, anaesthetic and intensive care teams, with oncology involvement when appropriate. Detailed preoperative imaging is essential to determine the cranial extent of the thrombus, its relationship to the hepatic veins and right atrium, and the possibility of caval wall invasion. High-quality preoperative imaging also assists in determining whether vascular reconstruction or CPB may be required (2,3). Echocardiographic assessment is particularly important when the thrombus extends into the right atrium, allowing evaluation of cardiac function, thrombus mobility, tricuspid valve involvement and potential obstruction of right-sided cardiac inflow (2).

The cardiothoracic surgeon has a central role in the management of Mayo level IV tumour thrombus. This role extends beyond providing CPB support and includes preoperative cardiovascular assessment, planning of vascular access, selection of the appropriate cardiac exposure, establishment and management of CPB, direct right atrial access and controlled extraction of the intracardiac tumour component. Direct visualisation of the thrombus may reduce the risk of fragmentation and incomplete removal during intracardiac manipulation. The importance of cardiothoracic involvement in high-level tumour thrombus has been demonstrated in previous surgical series and case reports (3).

Our two cases illustrate different aspects of this multidisciplinary approach. In the first patient, the thrombus was found intraoperatively to be firmly adherent to the IVC wall. An attempt was initially made to mobilise the thrombus from below; however, because of its adherence, it was subsequently approached from the right atrial aspect and removed completely in a piecemeal fashion under CPB. This finding emphasises that the radiological level of tumour thrombus does not fully predict its intraoperative behaviour. In addition to the cranial extent, thrombus mobility, friability and caval wall adherence are important determinants of surgical difficulty and operative strategy (2,3).

The use of CPB with or without deep hypothermic circulatory arrest (DHCA) remains an important technical consideration in Mayo level IV disease. CPB provides controlled haemodynamic support during manipulation and opening of the right atrium and IVC and facilitates direct intracardiac tumour extraction. DHCA may provide a relatively bloodless field and improve direct visualisation when the thrombus is extensive, friable or difficult to control. However, DHCA introduces additional physiological stress and may increase the risks associated with profound hypothermia, circulatory arrest, coagulopathy and prolonged CPB (4,5). Therefore, DHCA should not necessarily be considered mandatory in every patient with Mayo level IV thrombus.

Evidence regarding the need for DHCA remains heterogeneous. Shuch et al. evaluated patients with level IV RCC undergoing CPB-supported surgery and highlighted the significant perioperative morbidity associated with these procedures while examining whether DHCA provided an advantage (4). More recently, Zacek et al. reported a 37-patient single-centre experience of RCC with intracardiac tumour thrombus treated with radical surgery and DHCA, demonstrating that aggressive surgical treatment can provide meaningful long-term survival in selected patients (5). Conversely, other surgical approaches have demonstrated that selected supradiaphragmatic or right atrial thrombi can be removed without CPB or DHCA when the thrombus is sufficiently mobile and can be safely controlled (6). Thus, the decision regarding CPB and DHCA should be individualised according to thrombus morphology, mobility, caval wall

involvement, cardiac extension and the anticipated technical requirements of the operation.

The second case demonstrates the additional complexity of concomitant coronary artery disease. Preoperative coronary angiography identified significant left anterior descending coronary artery stenosis. This finding allowed the cardiac surgical team to incorporate coronary revascularisation into the overall operative plan. The patient subsequently underwent right radical nephrectomy, IVC and right atrial thrombectomy, and left internal mammary artery-to-LAD coronary artery bypass grafting during the same CPB-supported procedure. This illustrates the broader role of the cardiothoracic surgeon in patients with extensive RCC thrombus, particularly when significant cardiovascular comorbidity is identified during preoperative assessment.

Concomitant cardiac surgery and oncological surgery require careful consideration because of the competing risks of major blood loss, prolonged operative duration, CPB-associated coagulopathy and postoperative organ dysfunction. Previous reports have highlighted the additional technical challenges associated with IVC tumour thrombus in patients with previous CABG, particularly when redo sternotomy and CPB are required (7). Although our patient had not undergone previous CABG, the case demonstrates the potential advantage of identifying significant coronary disease before surgery and incorporating appropriate revascularisation into a single planned operation.

Major haemorrhage and blood conservation are additional considerations during radical nephrectomy and IVC thrombectomy. Tumour adherence to the caval wall may necessitate extensive dissection or vascular reconstruction, increasing the risk of major blood loss (2,3). In our second patient, estimated blood loss was 3,830 mL, and intraoperative cell salvage allowed 2,580 mL of salvaged blood to be returned to the patient. These cases emphasise the importance of anticipating major haemorrhage and ensuring appropriate anaesthetic, transfusion and blood-conservation strategies. Such procedures are best undertaken in centres with access to experienced urological and cardiothoracic surgical teams, CPB facilities and appropriate postoperative intensive care.

The oncological benefit of surgery must ultimately be balanced against the substantial perioperative risks associated with Mayo level IV disease. Earlier large surgical series demonstrated increasing operative morbidity with increasing thrombus level, although surgical resection remains an important treatment option in appropriately selected patients (6). The current EAU guidance supports surgical removal of the renal tumour and venous tumour thrombus in selected patients with non-metastatic disease (1). In our first patient, there was no evidence of local recurrence or distant metastasis at 12 months. The second patient remained under clinical follow-up for 8 months but was subsequently lost to follow-up, limiting assessment of his long-term oncological outcome.

Conclusion

Overall, these cases demonstrate that Mayo level IV RCC should be regarded as a multidisciplinary surgical condition rather than an isolated urological procedure. The cardiothoracic surgeon contributes to preoperative cardiovascular assessment, operative planning, CPB, direct right atrial access, intracardiac tumour extraction, management of major haemorrhage and concomitant coronary revascularisation when indicated. Importantly, the need for DHCA should be determined by the characteristics of the thrombus and the anticipated operative requirements rather than by thrombus level alone. A coordinated approach between urological and cardiothoracic teams can facilitate safe and complete tumour thrombectomy while allowing simultaneous management of significant cardiovascular disease when necessary.

References

1. Bex A, Abu-Ghanem Y, Albiges L, Bonn S, Campi R, Capitanio U, et al. European Association of Urology guidelines on renal cell carcinoma: the 2025 update. Eur Urol. 2025; 87(6): 683-96. doi:10.1016/j.eururo.2025.02.020.
2. Psutka SP, Leibovich BC. Management of inferior vena cava tumor thrombus in locally advanced renal cell carcinoma. Ther Adv Urol. 2015; 7(4): 216-229. doi:10.1177/17562872 15576443.
3. Lawindy SM, Kurian T, Kim T, Mangar D, Armstrong PA, Alsina AE, et al. Important surgical considerations in the management of renal cell carcinoma with inferior vena cava

tumour thrombus. BJU Int. 2012; 110(7): 926-39. doi:10.1111/j.1464-410X.2012.11174.x.

4. Shuch B, Crispen PL, Leibovich BC, LaRochelle JC, Pouliot F, Pantuck AJ, et al. Cardio-pulmonary bypass and renal cell carcinoma with level IV tumour thrombus: can deep hypothermic circulatory arrest limit perio-perative mortality? BJU Int. 2011; 107(5): 724-8. doi:10.1111/j.1464-410X.2010.09488.x.
5. Zacek P, Brodak M, Gofus J, Dominik J, Moravek P, Louda M, et al. Renal cell carcinoma with intracardiac tumor thrombus extension: radical surgery yields 2 years of postoperative survival in a single-center study over a period of 30 years. Front Oncol. 2023; 13: 1137804. doi:10.3389/fonc.2023.1137804.
6. Blute ML, Leibovich BC, Lohse CM, Cheville JC, Zincke H. The Mayo Clinic experience with surgical management, complications and outcome for patients with renal cell carcinoma and venous tumour thrombus. BJU Int. 2004; 94(1): 33-41. doi:10.1111/j.1464-410X.2004. 04897.x.
7. Ciancio G, Farag A, Salerno T. Renal cell carcinoma with inferior vena cava tumor thrombus in two patients with previous coronary artery bypass graft: strategy for surgical removal. Front Surg. 2021; 8: 676245. doi:10.3389/fsurg.2021.676245.