

## LEIOMYOMATOSIS PERITONEALIS DISSEMINATA IN A 50-YEAR OLD WOMAN: IMAGING FINDINGS

A. Talebian Yazdi, K. De Smet, M. Antic, B. Ilsen, F. Vandenbroucke, J. de Mey<sup>1</sup>

**Leiomyomatosis peritonealis disseminata (LPD) – or diffuse abdominal leiomyomatosis – is a very rare benign abdominal entity. Only a little more than 100 cases have been reported in the English literature since its first description in 1965. Middle aged female are typically affected and the clinical presentation is rather aspecific. The differential diagnosis between benign LPD and diffuse peritoneal carcinomatosis or abdominal disseminated malignancy represents the crucial diagnostic challenge that can only definitively be made through biopsy and histologic analysis.**

**Multimodal imaging features (ultrasound, CT, MR and PET) of a case of LPD diagnosed in a 50-year old female are presented with review the literature.**

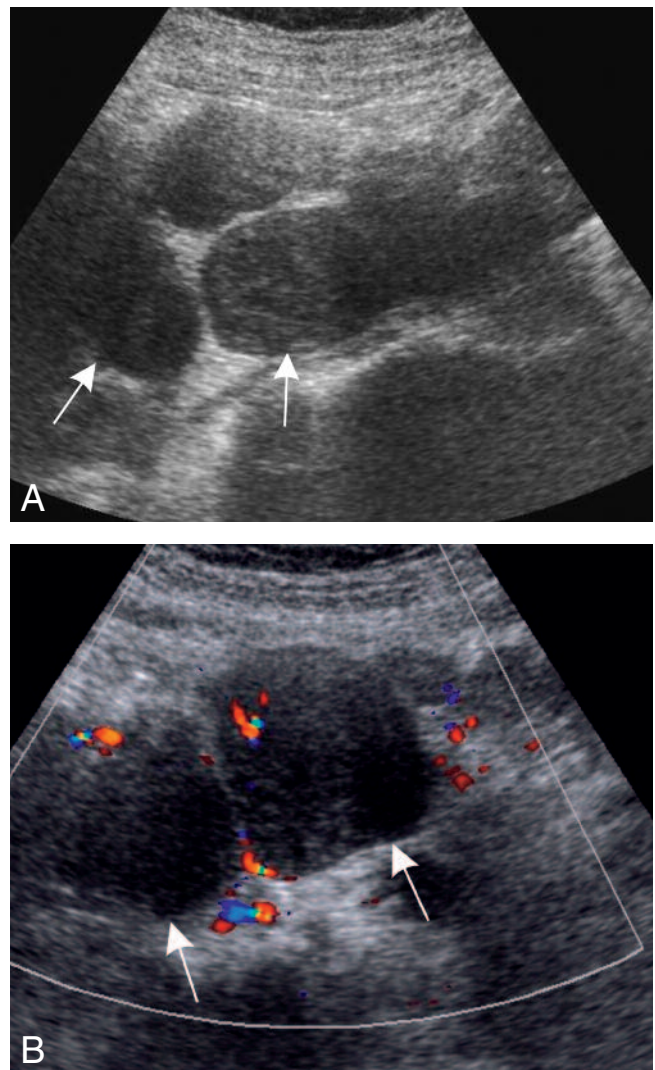
**Key-word: Leiomyoma.**

Uterine leiomyoma is a well known and common gynecological entity affecting women primarily in the 3<sup>rd</sup> through 5<sup>th</sup> decades of life. These benign tumors usually arise in the urogenital tract, but unusual locations have been described. Differentiation from malignant leiomyosarcoma is of great clinical importance. Histopathologically, the most important criterium is mitotic activity (1-2). Extra-uterine leiomyoma is a rare but well known entity with the lung, small bowel, skin and oesophagus being the most common locations. Although the classical leiomyoma of the uterus has easily distinguishable radiological features, unusual locations of leiomyoma can confront the radiologist with a diagnostic dilemma. This manuscript reports on a case of diffuse peritoneal leiomyomatosis, with illustration of the key radiological and histopathological features.

### Case report

A 50-year-old, female patient presented at the emergency department complaining of vague abdominal discomfort in the back, radiating to the left lower quadrant. Routine clinical and laboratory work-up led to no specific diagnosis.

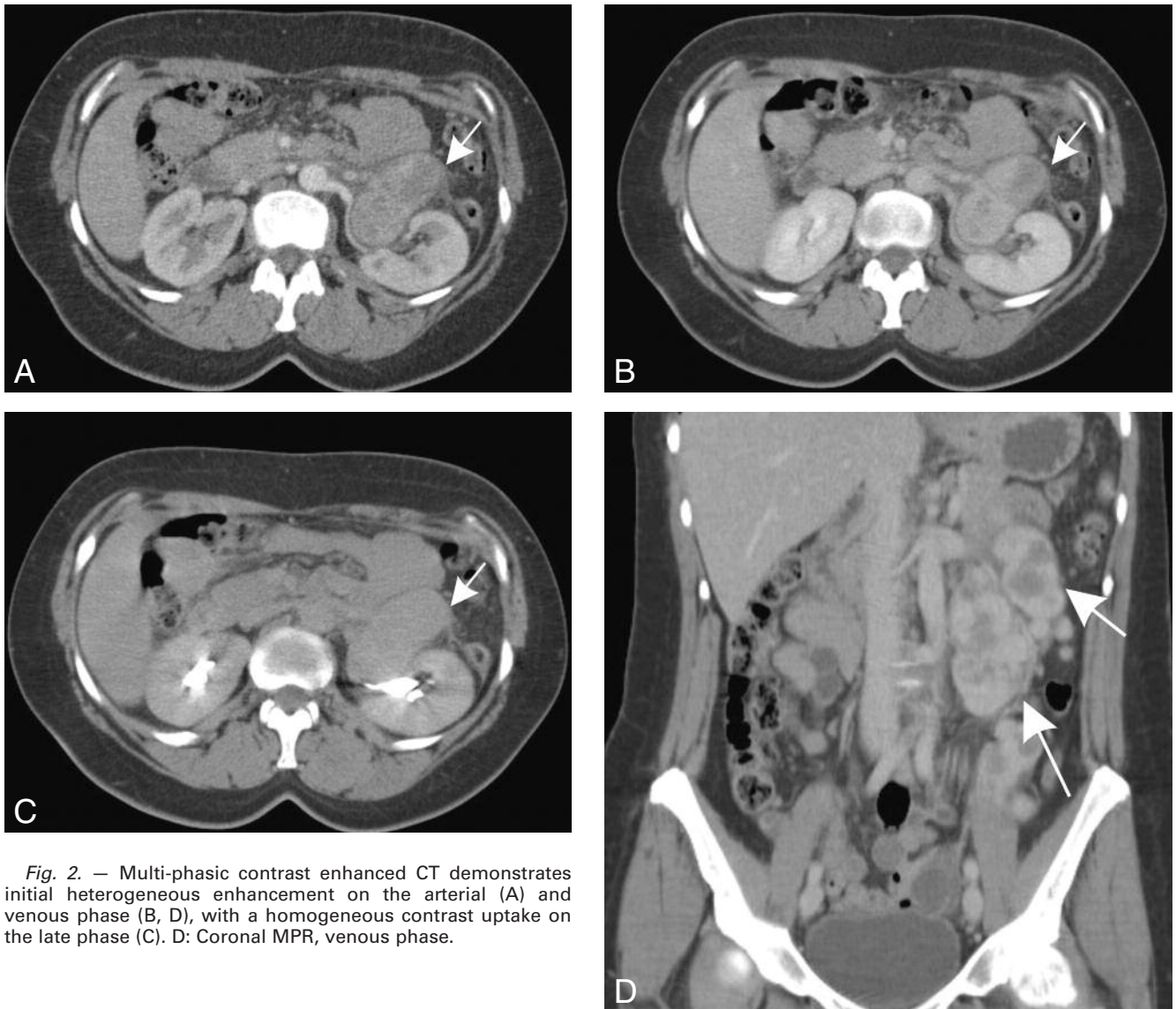
Ultrasonography of the abdomen showed a normal aspect of the solid abdominal organs. Dispersed in the abdominal cavity, numerous nodules with varying size were detected (Fig. 1). These solid nodules were hypoechoic with little vascularisation on color Doppler. A contrast enhanced abdominal CT demon-



*Fig. 1. – A: Grey scale US showing multiple solid nodules, randomly dispersed in the peritoneum. B: On color Doppler US the nodules shows low to moderate vascularisation.*

*From:* 1. Department of Radiology, UZ Brussel, Brussels.  
*Address for correspondence:* Dr A. Talebian Yazdi, Dept. of Radiology, UZ Brussels, Laarbeeklaan 101, B-1090 Brussels, Belgium.

strated multiple nodules, located in the intra-, retro- and extraperitoneal cavity. The nodules demonstrated a heterogeneous uptake of contrast on



*Fig. 2.* — Multi-phasic contrast enhanced CT demonstrates initial heterogeneous enhancement on the arterial (A) and venous phase (B, D), with a homogeneous contrast uptake on the late phase (C). D: Coronal MPR, venous phase.

the arterial and venous phase. On the late phase however a nearly homogenous uptake in the lesions was demonstrated (Fig. 2).

The patient was scheduled for CT-guided biopsy. The tentative histopathological diagnosis was leiomyoma, but malignant leiomyosarcoma could not be ruled out on basis of the biopsy. The tumor markers showed normal levels of B-HCG, CEA and CA125 and on the PET-examination no tracer uptake was shown for the nodules. These results practically excluded malignancy. The patient was scheduled for a MRI of the abdomen. The nodules showed an intensity similar to smooth muscle (Fig. 3).

On explorative laparotomy surgical specimens were taken for a more definite PA diagnosis. The PA report described no sign of necrosis, nor-

mal mitotic activity and no nuclear polymorphism, confirming the diagnosis of diffuse peritoneal leiomyomatosis.

#### Discussion

Leiomyomas of the urogenital tract are primarily benign disorders and reports on metastases from these tumors are infrequently encountered in the literature. These benign tumors of smooth muscle origin are more common in the urogenital tract while leiomyomatosis in unusual locations can pose a diagnostic challenge. Women in their reproductive age or using oral contraceptives are at risk for developing leiomyomas outside the urogenital tract. A hormonal influence has therefore been hypothesized (3). History of hysterectomy has also

been suggested to be associated with distant urogenital leiomyomas. The time interval between hysterectomy and metastases can reach up to 20 years.

Although the clinical presentation is nonspecific, symptoms such as chest pain, abdominal discomfort and dyspnea have been described.

Usually these tumors arise in the genitourinary tract but may arise in or metastasize to nearly any anatomic site. In case of invasion of the peritoneal cavity the condition is called leiomyomatosis peritonealis disseminata or diffuse peritoneal leiomyomatosis (4). The exact pathophysiology of disseminated leiomyomatosis remains enigmatic. Local overgrowth of smooth muscle cells under hormonal influence has been hypothesized (5). Intra-abdominal deposition during surgery for a pri-

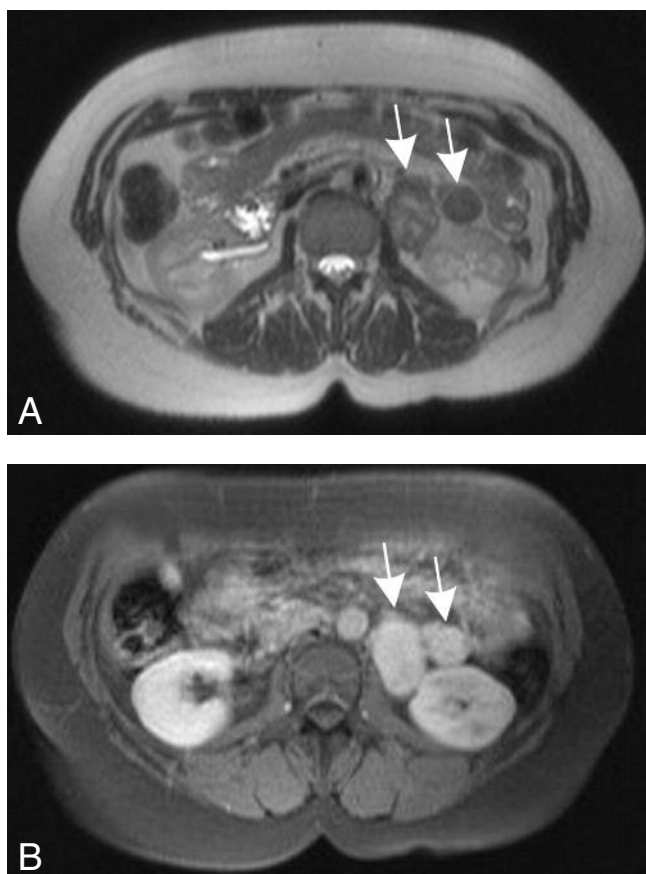


Fig. 3. — MRI of the abdomen shows iso-intensity of the lesions with skeletal muscle (A). After Gadolinium injection there is heterogeneous enhancement in the early phase (B, 30 sec), gradually progressing to homogenous enhancement on the late phase (C, 90 sec).

mary urogenital leiomyoma is another hypothesis (6).

Although a highly malignant leiomyosarcoma can be readily diagnosed histopathologically, the distinction between a leiomyoma and a low-grade leiomyosarcoma can be challenging. The latter entity must be ruled out regarding the evident clinical implications. Laparotomy and surgical biopsy are essential for a definitive diagnosis.

In this paper we have reported a case of leiomyomatosis of the abdominopelvic cavity, first described in 1965 (3). This entity strongly mimics peritoneal metastasis. Knowledge of the imaging characteristics of this benign entity, therefore helps the radiologist to recognise this disorder, with peritoneal carcinomatosis being the most important differential diagnosis. Lymphoma, tuberculosis and mesothelioma are also other potential mimickers. Ultrasound character-

istics include homogenous hypoechoic, solid nodules with low to moderate vascularity (7). Contrast enhanced CT will reveal solid lesions dispersed in the abdominal cavity with heterogeneous contrast uptake in the arterial and venous phase, gradually progressing to a homogenous uptake in the late phase (8). Iso-intensity with skeletal muscle on T1 and T2 is the most important MRI feature. Administration of gadolinium reveals homogenous enhancement of the lesions in the late phase (9).

On positron emission tomography (PET) the nodules show no uptake of FDG, whereas malignant lesions classically show avid FDG uptake. PET is therefore a key modality for the differentiation of LPD from malignant peritoneal disease.

The treatment of LPD is generally surgical. Resection of the primary tumors, metastatic implants and

oophorectomy leads to a good overall prognosis and survival rate.

## Conclusion

Leiomyomatosis peritonealis disseminata is a very rare benign disorder affecting middle aged women. The differentiation from leiomyosarcoma is essential and requires imaging and histopathological workup. Knowledge of the main features is important for the radiologist in order to correctly diagnose this entity and prevent unnecessary and potentially harmful intervention.

## References

1. Silverberg S.G., Kurman R.J.: Tumors of the uterine corpus. Tumors of the Uterine Corpus and Gestational Trophoblastic Disease. Washington, DC: Armed Forces Institute of Pathology; 1991, 113-146. Atlas of Tumor Pathology; 3rd series, fascicle 3.
2. Kempson R.L., Hendrickson M.R.: Pure mesenchymal neoplasms of the uterine corpus. Haines and Taylor Obstetrical and Gynecological Pathology. Edinburgh, Scotland: Churchill Livingstone, 1987, 411-456.
3. Taubert H.D., Wissner S.E., Haskins A.L.: Leiomyomatosis peritonealis disseminata. *Obstet Gynecol*, 1965, 25: 561-574.
4. Kaplan C., Bernirschke K., Johnson K.C.: Leiomyomatosis peritonealis disseminata with endometrium. *Obstet Gynecol*, 1980, 55: 119-122.
5. Tavassoli F.A., Norris H.J.: Peritoneal leiomyomatosis (leiomyomatosis peritonealis disseminata): a clinicopathological study of 20 cases with ultrastructural observations. *Int J Gynecol Pathol*, 1982, 1: 59-74.
6. Thian Y.L., Tan K.H., Kwek J.W.: Leiomyomatosis peritonealis disseminata and subcutaneous myoma - a rare complication of laparoscopic myomectomy. *Abdom Imaging*, 2009, 34: 235-8.
7. Papadatos D., Taourel P., Bret P.M.: CT of leiomyomatosis peritonealis disseminata mimicking peritoneal carcinomatosis. *AJR*, 1996, 167: 475-476.
8. Fulcher A.S., Szucs R.A.: Leiomyomatosis peritonealis disseminata complicated by sarcomatous transformation and ovarian torsion: presentation of two cases and review of the literature. *Abdom Imaging*, 1998, 23: 640-644.
9. Singh G., Gordon-Harris L., Frazer G.B.: leiomyomatosis peritonealis disseminata - diagnosis by sonography. *Ind J Radiol Imaging*, 2002, 12: 497-500.