

METASTATIC CARCINOID OF THE APPENDIX

K. van der Sloot, E.J. Vonken, P.A. de Jong¹

Key-word: Carcinoid

Background: A 72-year-old female patient presented to the gynecologist after referral by her general practitioner, with complaints of occasional abdominal discomfort. Besides the vague lower abdominal discomfort and 10 kg weight loss due to loss of appetite, there were no specific symptoms. The medical history was negative, except for a cyst in the breast. Physical examination revealed a palpable large, mobile mass in the right lower abdomen and a deviation of the portion to the left. Otherwise, physical examination was unremarkable.

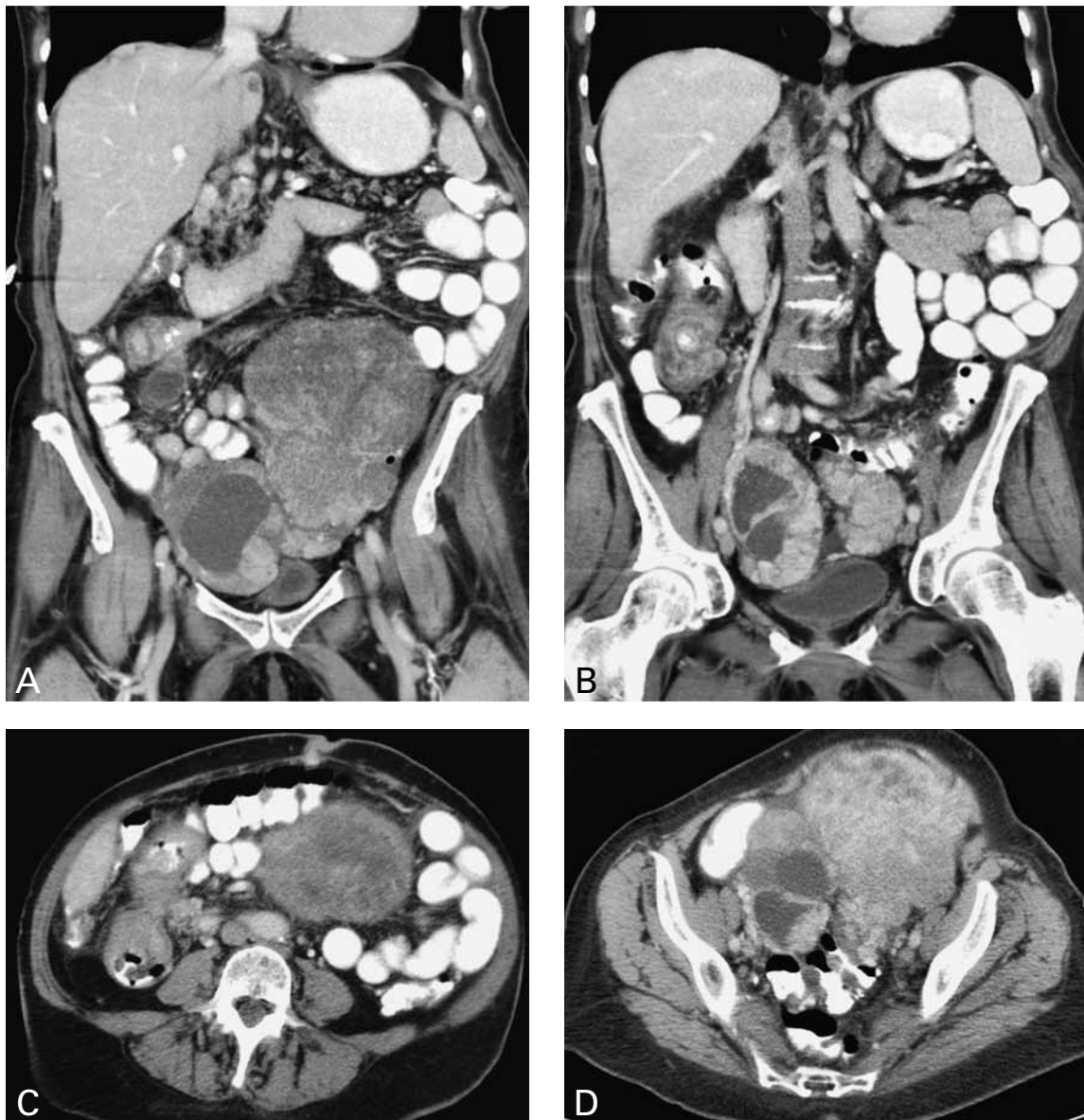


Fig.

1A	1B
1C	1D

Work up

Abdominal CT scan with oral contrast and intravenous contrast during the portal venous phase (Fig. 1) shows on coronal reformatted images (A,B) bilaterally enlarged ovaries with cystic and solid components. Lymphadenopathies are seen in the right lower abdomen and retroperitoneum (A,B). In addition, there is an ileocolic intussusception (B). Axial images at the level of the umbilicus (C) and the pelvis (D) demonstrate the bilateral ovarian masses, the invagination of the distal ileum into the ascending colon with thickening of the intestinal wall and lymphadenopathy. In addition, a mass is visible in the umbilicus (sister Mary Joseph nodule) (C).

Radiological diagnosis

Radiologically, the most likely diagnosis was distal ileum tumor with metastasis to the umbilicus (sister Mary Joseph nodule) and ovaria (Krukenberg). Ultrasound guided core biopsy of the ovarian mass revealed an atypical carcinoid. Histopathologic assessment following ovariectomy and right hemicolectomy, confirmed the presence of a carcinoid at the base of the appendix with involvement of multiple pathologic mesenteric lymph nodes. The left and right ovary measured 16,5 cm and 11,0 cm in maximal diameter, respectively. In both ovaries, tumorous carcinoid tissue was present indicating metastases from a different primary site (second primary site unknown). The pathologically proven diagnosis was *metastatic carcinoid of the appendix*.

Discussion

Traditionally, a Krukenberg tumor is a metastatic signet ring cell adenocarcinoma of the ovary. It is a rare disorder accounting for 1 to 2% of all ovarian tumors. In 70% of Krukenberg tumor cases the

stomach is the primary site of lesion. In the presented case the bilateral ovarian metastases were not of a signet ring cell adenocarcinoma type, but were composed of atypical carcinoid stroma. Although primary ovarian carcinoid does exist, it is usually unilateral. A sister Mary Joseph nodule is most often caused by a gastrointestinal tumor, but can be caused in 25% of the cases by an ovarian tumor. The route to the umbilicus is unclear and could be transperitoneal, lymphatic or hematogenous.

In our case, the radiological diagnosis of a primary gastro-intestinal tumor was triggered mainly by the ileo-colic intussusception and the lymphadenopathy in the right lower abdomen. In the literature, over 70 cases of ovarian metastasis of a carcinoid have been reported. In one article describing 17 patients, the age ranged from 44 to 77 years. Six of those 17 patients presented with abdominal complaints, of whom three with pain and three with signs of bowel obstruction. In 15 out of 17 the primary tumor site was the distal ileum. After a median follow-up of 31 months, 15 of the 17 patients were still alive.

The lesson of this case is that even with disseminated disease and very obvious ovarian disease, it is important to scrutinize every organ systematically. Additional (subtle) signs can point towards the correct diagnosis.

Bibliography

1. Al-Agha O.M., Nicastro A.D.: An in-depth look at Krukenberg tumor: an overview. *Arch Pathol Lab Med*, 2006, 130: 1725-1730.
2. Strosberg J., Nasir A., Cragun J., et al.: Metastatic carcinoid tumor of the ovary: A clinicopathologic analysis of seventeen cases. *Gyn Oncol*, 2007, 106: 65-68.
3. Yada N., Yamamoto T., et al.: Metastatic ovarian tumors: a review of 64 cases. *Gynecol Oncol*, 2003, 89: 314-317.