

Percutaneous Thrombus Removal in a COVID-19–Infected Patient with Pulmonary Embolism

Angelo Nascimbene, MD; Sukhdeep S Basra, MD; Kha Dinh, MD; Jayeshkumar A Patel, MD; Igor D Gregoric, MD; Biswajit Kar, MD

THE UNIVERSITY OF TEXAS HEALTH SCIENCE CENTER AT HOUSTON, HOUSTON, TEXAS

ABSTRACT: We present a case describing the use of the AngioVac system (AngioDynamics, Inc.) and SENTINEL™ cerebral protection system (SCPS; Boston Scientific) in a patient with COVID-19 who initially presented with a large deep-vein thrombosis of the left lower extremity, complicated by a pulmonary embolism. Although he initially improved with systemic alteplase, he later developed a second large clot diagnosed in transit in the right atrium. Within 12 hours from initial thrombolysis, this large clot wedged across an incidental patent foramen ovale (PFO), the atrial septum, and the cavotricuspid annulus. We emergently performed a percutaneous clot extraction with preemptive placement of the SCPS in anticipation of cardioembolic phenomenon. A large (> 10 cm) clot was extracted without complication, and the patient was discharged home.

The combined use of SCPS and AngioVac in this case suggests a potential role for percutaneous treatment of severe and consequential thromboembolic disease, especially in patients with a PFO, and may be considered as an alternative and less-invasive option in patients with COVID-19. While cerebral embolic protection devices are approved for and widely used in transcatheter aortic valve replacement procedures, there is a theoretical benefit for use in percutaneous thrombolectomies as well.

INTRODUCTION

The past year has seen a higher incidence of deep venous thrombosis (DVT) and pulmonary embolism (PE) due to the highly prothrombotic nature of COVID-19.¹ Guided by D-dimer levels, clinicians have initiated full-dose anticoagulation when the index of suspicion is high for venous thromboembolism or when patients have disproportionate hypoxemia.²

We present a patient with a recent diagnosis of COVID-19 who was found to have a massive saddle pulmonary embolism with a large right atrial thrombus in transit.

CASE PRESENTATION

Within 8 days of being diagnosed with COVID-19, a 44-year-old man presented to a satellite hospital after a syncopal episode. He was hypoxic, with oxygen saturation in the 80s, tachycardic (140 beats per minute), and mildly hypotensive (101/63). He complained of chest pain and dyspnea and had a history of type 2 diabetes mellitus, hypertension, dyslipidemia, and obesity.

His blood work was significant for a lactate level of 4.7 mmol/L, creatinine of 2.4 mg/dL, and troponin I of 0.19 ng/mL. Computed tomography angiogram of the chest revealed a large saddle embolism extending to the segmental branches, with right ventricular (RV) strain (Figure 1) as well as diffuse patchy ground-glass opacities consistent

with COVID-19 pneumonia. A lower extremity venous Doppler ultrasound revealed a large left occlusive thrombus spanning from the proximal superficial femoral vein into the popliteal, posterior tibial, anterior tibial, and peroneal veins. A thrombus was visualized in the right atrium in transit across the tricuspid annulus on a transthoracic echocardiogram (TTE, Video 1).

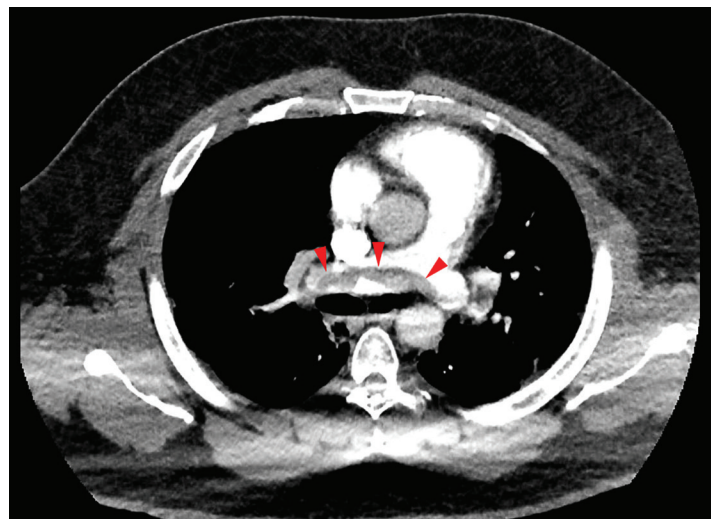


Figure 1.

A large, saddle pulmonary embolism (arrows) shown in computed tomography angiogram of the chest, axial view.

The patient was transferred to a central hospital for advanced care, where he was placed on a nonrebreather mask at 15 L/min and 100% FiO₂. He was treated with dexamethasone and remdesivir for his COVID-19 pneumonia and intravenously given 50 mg of alteplase. His hemodynamics improved, lactic acid normalized within 6 hours from thrombolytic therapy, and weight-based heparin was continued.

A repeat TTE showed the large clot now wedged across the interatrial septum (Video 2). Surgical options were eliminated due to tenuous hemodynamics, recent systemic thrombolytics

(less 12 hours), and acute COVID-19 pneumonia requiring high oxygen supplementation. Given the rapidly evolving nature of his clinical condition and in anticipation of a foreseeable additional PE with likely worsening hemodynamic compromise and/or a large cerebral or arterial embolic occlusion, the patient underwent an expedited right and left atrial embolectomy. He was pre-emptively intubated with rocuronium and etomidate to help him tolerate a prolonged supine position, improve his oxygenation, and facilitate intraprocedural control. Femoral venous and arterial access was obtained prior to intubation.

The SENTINEL cerebral protection system (SCPS, Boston Scientific) was deployed through a 6F sheath in the right radial artery (Figure 2), and the AngioVac system (Angiodynamics, Inc.) was deployed according to standard practice.³ The right and left femoral veins were accessed using the modified Seldinger technique with a 19F Bio-Medicus (inflow) cannula (Medtronic), and a 25F sheath was used to accommodate the 25F Bio-Medicus (outflow) cannula. Cannulas were deployed over 0.035-inch Amplatz Super Stiff™ guidewires (Boston Scientific). Both large access sites were pre-closed with bilateral Perclose ProGlide™ closure devices (Abbott) given the recent thrombolytic use.

Next, the activated clotting time was driven to > 300 seconds with multiple boluses of unfractionated heparin. Using the 25F sheath, we inserted an AngioVac curved cannula into the right atrium to apply extracorporeal retrograde flow up to 3 L/min (Figure 3). Under transesophageal echocardiography (TEE) guidance (Video 3), the AngioVac cannula was directed into the right atrium medially to engage the clot, and it was slowly retracted by increasing the circuit flow to increase suction and prevent systemic embolization. On inspection, the clot was already organized (Figure 4), and it was retrieved through the patent foramen ovale (PFO) without any systemic embolization. Due to the residual high thrombus burden in the left lower extremity, an OPTASE® retrievable vena cava filter (Cordis) was placed under fluoroscopic guidance. Furthermore, percutaneous closure of the PFO was delayed due to the presence of acute COVID-19 infection and associated prothrombotic state. Based on the intraoperative TEE, no large clots were identified; thus, an additional distal embolectomy was deferred.

The patient was extubated a few hours after the procedure and was neurologically intact. He was transferred out of the intensive care unit a few days later and was discharged home on room air and full anticoagulation.

DISCUSSION

Thrombi in the vena cava and right atrium are risk factors for increased morbidity and mortality and are associated with the

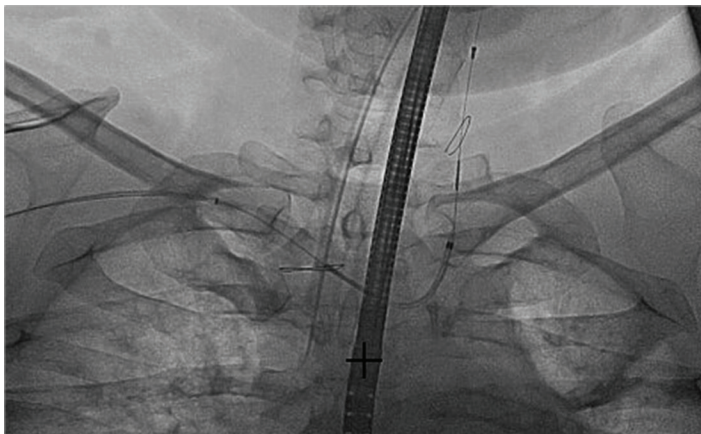


Figure 2.

Fluoroscopic image of the SENTINEL cerebral embolic protection device (Boston Scientific) with proximal basket in the brachiocephalic trunk and distal basket in the proximal left carotid artery.

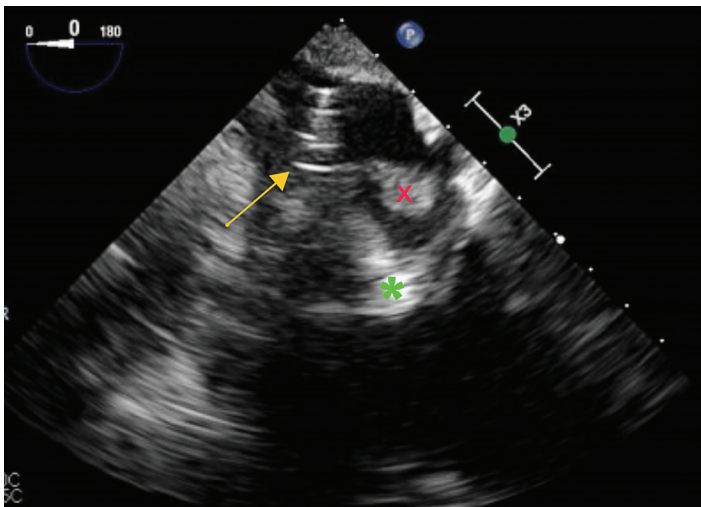


Figure 3.

Transesophageal echocardiogram shows the AngioVac System cannula (arrow) retrieved back into the right atrium across the patent foramen ovale. The left atrial portion of the clot (X) is visualized, as is the right atrial portion of the clot (*).

potential risk of PE.³ In patients with PFO, these thrombi can get wedged in the PFO and also are associated with a high risk of cerebrovascular accidents. Percutaneous aspiration of thrombi or vegetations using the AngioVac system is a minimally invasive method that minimizes surgical trauma and associated comorbidities.

Fujikura et al. previously reported a case of COVID-19–related submassive PE with thrombus in transit through a PFO that was conservatively managed with heparin infusion.⁴ However, our case demonstrates the feasibility of a percutaneous option when medical management is suboptimal. Specifically, the clot in this case was already organized despite the use of alteplase and was able to cross into systemic circulation.

Although the AngioVac system has been used for percutaneous mechanical embolectomies, its use has been relatively limited as evidenced by the largest published series, which consists of only 26 cases.⁵ The system offers straightforward deployment in a catheterization laboratory setting. In this case, the system provided up to 3 L/min of retrograde flow, which enabled complete aspiration of a large

clot across the interatrial septum without any significant fragmentation. We also advocate for the use of cerebral embolic protection devices (CEPDs), which are readily available and relatively easy-to-use, to prevent possible systemic arterial embolization through a PFO.

It is conceivable that this patient had a prior PFO or acute elevation in pulmonary pressure (as demonstrated by RV strain pattern) that facilitated opening of the PFO with associated right-to-left shunting across the interatrial septum. Patients with thrombus in transit are typically treated with a surgical embolectomy and concomitant surgical PFO closure; however, this case demonstrates a minimally invasive method of achieving the same result in patients who are not surgical candidates.

Finally, CEPDs are widely approved for use as an embolic protection device to capture thrombus and debris following transcatheter aortic valve deployment.^{6,7} The preemptive deployment of the SCPS adds an additional safety feature to prevent catastrophic cerebral embolization when mechanical thrombectomy is used to disrupt and remove clots.

CONCLUSION

The combined use of SCPS and AngioVAC in this patient suggests a potential role for percutaneous treatment of thrombus in transit. This is especially important in the context of the COVID-19 pandemic, which is generating a large number of patients with thrombotic complications who may not be eligible for surgery. The use of CEPDs may provide additional protection against catastrophic neurologic sequelae in these critically ill patients.

Acknowledgments:

The authors thank Michelle Sauer, ELS, PhD, and Jessica Moody, PhD, for editorial assistance.

Corresponding Author:

Biswajit.Kar@uth.tmc.edu

Conflict of Interest Disclosure:

Dr. Basra is on the AstraZeneca scientific advisory board and speaker's bureau.

Keywords:

thrombus, pulmonary embolism, COVID-19, case report

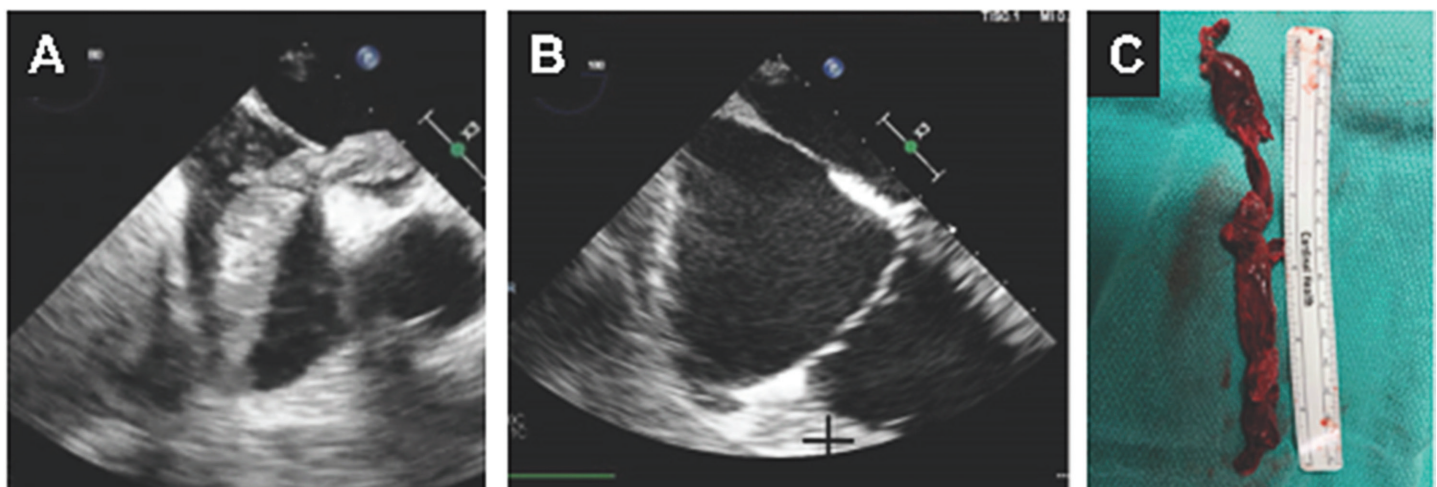


Figure 4.

Transesophageal echocardiogram and clinical specimen. (A) Negative flow applied using the AngioVac system's inflow aspirates the clots in a retrograde fashion into the right atrium across the patent foramen ovale. Microcavitation is seen on the right chamber and leftward interatrial septum. (B) Post clot extraction. (C) Extracted specimen.

SUPPLEMENTAL*Video 1.*

Transthoracic echocardiogram view of the right ventricular inflow/left atrium reveals the presence of large clots next to the interatrial septum.

Video 2.

Transthoracic echocardiogram shows the large clots, previously seen next to the interatrial septum, crossing into the left atrium.

Video 3.

Transesophageal echocardiogram modified 4-chamber view is used to visualize large clots in transit across the interatrial septum, through a patent foramen ovale.

REFERENCES

1. Gonzalez-Fajardo JA, Ansuategui M, Romero C et al. Mortality of COVID-19 patients with vascular thrombotic complications. *Med Clin (Engl Ed)*. 2021 Feb 12;156(3):112-117. doi: 10.1016/j.medcle.2020.10.008.
2. Garcia-Olive I, Sintes H, Radua J, Abad Capa J, Rosell A. D-dimer in patients infected with COVID-19 and suspected pulmonary embolism. *Respir Med*. 2020 Aug;169:106023. doi: 10.1016/j.rmed.2020.106023.
3. Haupt B, Merkle F, Dreizler T, Falk V, Starck C. Technical implementation of percutaneous thrombus aspiration using the AngioVac system. *Perfusion*. 2021 May;36(4):352-356. doi: 10.1177/0267659120946734. Epub 2020 Aug 13.
4. Fujikura K, Fontes JD, Taub CC. Saddle pulmonary embolism and thrombus-in-transit straddling the patent foramen ovale 28 days after COVID symptom onset. *Echocardiography*. 2020 Aug;37(8):1296-1299. doi: 10.1111/echo.14796. Epub 2020 Jul 31.
5. Al-Hakim R, Park J, Bansal A, Genshaft S, Moriarty JM. Early Experience with AngioVac Aspiration in the Pulmonary Arteries. *J Vasc Interv Radiol*. 2016 May;27(5):730-4. doi: 10.1016/j.jvir.2016.01.012.
6. Jobanputra Y, Jones BM, Mohananeey D, Fatima B, Kandregula K, Kapadia SR. Cerebral protection devices for transcatheter aortic valve replacement. *Expert Rev Med Devices*. 2017 Jul;14(7):529-543. doi: 10.1080/17434440.2017.1347038. Epub 2017 Jul 13.
7. Kapadia SR, Kodali S, Makkar R, et al. Protection Against Cerebral Embolism During Transcatheter Aortic Valve Replacement. *J Am Coll Cardiol*. 2017 Jan 31;69(4):367-377. doi: 10.1016/j.jacc.2016.10.023. Epub 2016 Nov 1.