

## Case Reports

## Transient Generalized Chorea in Influenza A Encephalopathy

Jannik Prasuhn<sup>1,2\*</sup>, Georg Royl<sup>1</sup>, Klaus P. Wandinger<sup>1,3</sup>, Norbert Brüggemann<sup>1,2</sup>, Alexander Neumann<sup>4</sup> & Thomas F. Münte<sup>1</sup>

<sup>1</sup>Department of Neurology, University of Lübeck, Lübeck, DE, <sup>2</sup>Institute of Neurogenetics, University of Lübeck, Lübeck, DE, <sup>3</sup>Institute of Clinical Chemistry, University Medical Center Schleswig-Holstein, Lübeck, DE, <sup>4</sup>Institute of Neuroradiology, University of Lübeck, Lübeck, DE

### Abstract

**Background:** Influenza A infections are a rare cause of movement disorders. Previously described patients have suffered from acute-onset myoclonus and/or dystonia or post-viral parkinsonism.

**Case Report:** We present the case of a 74-year-old female patient with transient generalized chorea due to influenza A-mediated encephalopathy.

**Discussion:** We discuss whether the clinical presentation and the magnetic resonance imaging changes may be attributable to cytokine-mediated encephalopathy or to direct cytotoxic effects of the virus. Additionally, we would like to make clinicians aware of this clinical sign in the context of viral encephalopathy.

**Keywords:** Influenza, encephalopathy, diffusion-weighted imaging lesion, chorea

**Citation:** Prasuhn J, Royl G, Wandinger KP, Brüggemann N, Neumann A, Münte TF. Transient generalized chorea in influenza A encephalopathy. *Tremor Other Hyperkinet Mov.* 2018; 8. doi: 10.7916/D8F495TP

\*To whom correspondence should be addressed. E-mail: jannik.prasuhn@neuro.uni-luebeck.de

**Editor:** Elan D. Louis, Yale University, USA

**Received:** July 19, 2018 **Accepted:** September 17, 2018 **Published:** October 9, 2018

**Copyright:** © 2018 Prasuhn et al. This is an open-access article distributed under the terms of the Creative Commons Attribution–Noncommercial–No Derivatives License, which permits the user to copy, distribute, and transmit the work provided that the original authors and source are credited; that no commercial use is made of the work; and that the work is not altered or transformed.

**Funding:** N.B. received funding from DFG (Deutsche Forschungsgemeinschaft), the Collaborative Center for X-linked Dystonia-Parkinsonism, and the Else-Kröner-Fresenius Foundation. T.F.M. received funding from DFG (Deutsche Forschungsgemeinschaft) and BMBF (Federal Ministry of Education and Research).

**Financial Disclosures:** N.B. received honoraria from Grünenthal GmbH. J.P. received funding from the GSK foundation. We acknowledge financial support by Land Schleswig-Holstein within the funding program ‘Open Access Publikationsfonds’.

**Conflicts of Interest:** The authors report no conflict of interest.

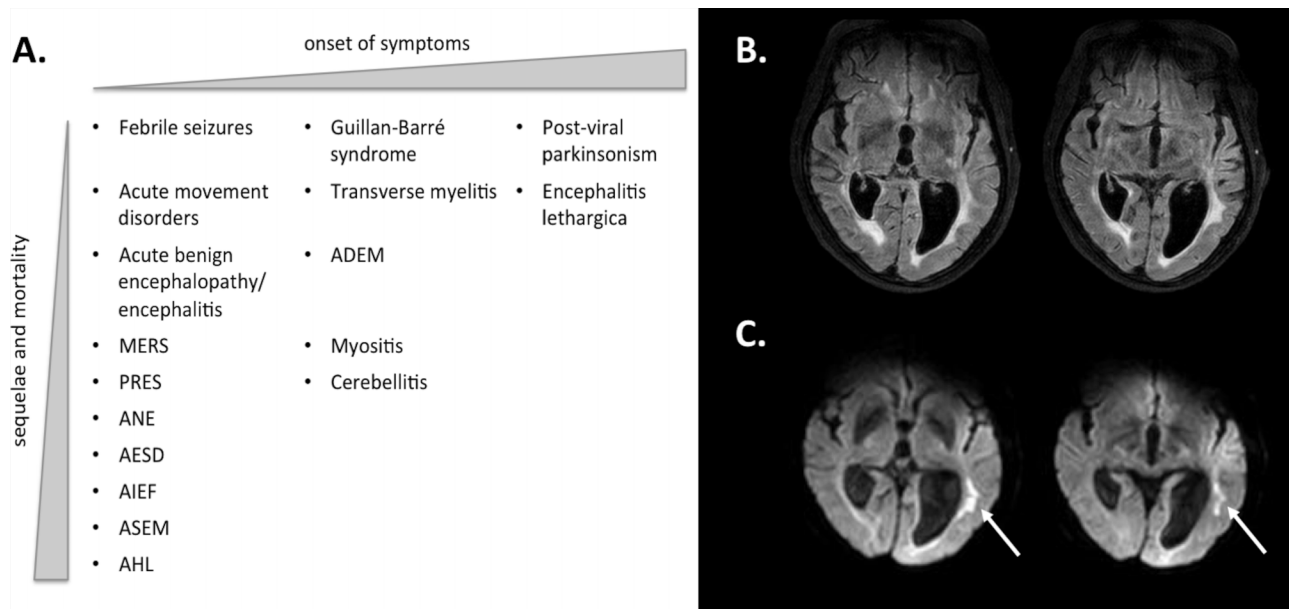
**Ethics Statement:** This study was performed in accordance with the ethical standards detailed in the Declaration of Helsinki. The authors’ institutional ethics committee has approved this study and all patients have provided written informed consent.

### Introduction

Influenza A infections of the respiratory system are known to be associated with a plethora of neurological manifestations (see Figure 1).<sup>1</sup> For example, it is a well-recognized but rather uncommon cause of viral encephalitis or encephalopathy in the younger and elderly population.<sup>2,3</sup> The occurrence of movement disorders concomitant to or following influenza A infections has already been reported. However, most previously described patients were either children presenting with acute-onset myoclonus and/or dystonia or were adults and suffered from post-viral parkinsonism.<sup>1,4</sup> A single historic case of influenza A-mediated chorea has been published, although the diagnostic reasoning, 125 years ago, was solely based on clinical grounds.<sup>5</sup> Here, we present a patient with confirmed influenza A-mediated chorea to raise awareness of a rare presentation of an uncommon cause of encephalopathy.

### Case report

The 74-year-old female patient was admitted to our emergency department accompanied by her sister. The case study was performed in accordance to Institutional Review Board (IRB) approval. According to third-party medical history, she had last been seen to be well the day before. She woke up with aphasia and severe disorientation following a couple of days of lassitude. She neither suffered from any pre-existing illness, nor did she take any medication regularly. Her initial body temperature was 37.4°C. On clinical examination, she presented with severe neuropsychiatric disturbances including irritability, dysexecutive symptoms, disorientation (in all dimensions), aphasia, concretism, and acalculia. She further exhibited right-sided central facial nerve paresis. Apart from that, there were no further findings on clinical examination. A computed tomography (CT) scan was performed immediately with no ischemic or hemorrhagic lesions in the native



**Figure 1. Clinical Syndromes and MRI Findings Associated with Influenza A Mediated Encephalopathy.** Overview of possible neurological manifestations of influenza infections (adapted from Goenka et al.<sup>1</sup>) (A) and magnetic resonance imaging (MRI) findings in the present case of influenza-A mediated encephalitis (B,C). Transversal fluid-attenuated inversion recovery sequence (B) and diffusion-weighted imaging (C) MRI scans revealed an elongated pattern confluent periventricular lesion at the left upper temporal lobe (arrowheads). Additionally, aspects of normal pressure hydrocephalus with signs of transependymal liquor diapedesis adjacent to the ventricles are present; MERS, Mild Encephalitis/Encephalopathy with Reversible Splenial Lesions; PRES, Posterior Reversible Encephalopathy Syndrome; ANE, Acute Necrotizing Encephalopathy; AESD, Acute Encephalopathy with Biphasic Seizures and Late Reduced Diffusion; AIEF, Acute Infantile Encephalopathy Predominantly Affecting the Frontal Lobes; ASEM, Acute Shock with Encephalopathy and Multiple Organ Failure; AHL, Acute Hemorrhagic Leukoencephalopathy; ADEM, Acute Disseminated Encephalomyelitis.

scan, no acute ischemia in perfusion-weighted CT, and no abnormalities of the supra-aortal vasculature in CT angiography. Cranial magnetic resonance imaging (MRI) performed one day later (see Figure 1) showed subcortical fluid-attenuated inversion recovery (FLAIR) and diffusion-weighted imaging (DWI) lesions in the left temporal region. The longish pattern of these lesions with transversal extension into the vascular territories of middle cerebral artery (MCA) and posterior cerebral artery (PCA) are not typical for an ischemic etiology. Viral encephalitis was considered in the differential diagnosis, and, thus, an empiric therapy with aciclovir was initiated. On her first day after admission the patient developed generalized chorea, including in the head, neck, trunk, and extremities, which she was unable to suppress. The chorea resolved spontaneously within 1 day. A subsequent cerebrospinal fluid (CSF) study showed an unremarkable cell count (4 leucocytes/ $\mu\text{L}$ ;  $<5$ ). Upon microbiological work-up there was no evidence for acute herpes simplex, varicella, or rubeola infection. An extensive work-up for autoimmune or paraneoplastic disorders remained unremarkable (including autoantibodies against amphiphysin, CV2 (CRMP-5), GAD, Hu, Jo1, NMDA, PNMA2 (Ma-2), recoverin, LGI1, Ri, SOX1, titin, and Yo). There was also no clinical or laboratory-based indication of other underlying autoimmune and metabolic disorders, including dysglycemia, renal failure, hepatic dysfunction, electrolyte imbalance, hypoparathyroidism, or hyperthyroidism. Finally, a nasopharyngeal swab for influenza A revealed a positive result. The influenza A infection was considered to be the underlying cause for the presented

symptoms, although irrevocably proving a causal relationship is not possible. The neuropsychiatric symptoms remitted gradually although a tendency for perseveration and mild acalculia remained for days. The patient had no insight into her illness and was discharged against medical advice at her fourth day after admission.

## Discussion

We have presented the case of a 74-year-old female with a complex neuropsychiatric syndrome and transient chorea. An acute influenza A-mediated encephalitis/encephalopathy (IAEE) was considered as the underlying cause of her medical condition. Radiographic findings with a left-sided periventricular FLAIR and DWI lesion support the diagnosis of an IAEE, and an extensive work-up for alternative infectious and autoimmune causes yielded negative results aside from influenza A. However, our patient displayed a rather benign disease course and showed spontaneous improvement of her symptoms without any treatment. Indeed, the subcortical MRI changes observed might be related to excessive immune response and present symptoms due to cytokine-mediated encephalopathy rather than to a direct cytotoxic effect of the virus.<sup>6,7</sup> This might explain the spontaneous remission and the discrepancy of the clinical syndrome and the lack of involvement of basal ganglia upon MRI. The most common clinical features of acute IAEE are seizures, delirium, altered vigilance, and speech abnormalities, of which only the last symptom was present in our patient.<sup>8</sup> For the corresponding year, 329/1,354 influenza swabs

performed in our hospital were positive for influenza A (about 24%), with only this patient revealing neurological complications. To our knowledge, only two adult patients with acute IAEE and subsequent movement disorders have been published so far: one 26-year-old female patient with fever, headache, irritability, intermittent resting tremor of the right hand, and upper limb rigidity and a 42-year-old male patient with fever, headache, bilateral upper limb tremor, rigidity, and orofacial bradykinesia. No abnormalities in cranial CT scans or MRI (the latter only performed on the 26-year-old patient) were reported in these cases.<sup>1</sup> Consistent with our case, CSF findings in acute IAEE are usually non-inflammatory (as it was also in this case) and the virus itself can only rarely be detected in CSF or in brain tissue.<sup>9,10</sup> Given the spontaneous remission and the lack of CSF pleocytosis, we consider our patient to have had influenza A encephalopathy rather than encephalitis. Unfortunately, no follow-up imaging was performed and we missed the opportunity to take a video in time as the chorea was only transiently present. The efficacy of immune-modulatory therapies has been demonstrated in anecdotal reports.<sup>6</sup> Therefore, as the aforementioned case report from 1892 suggested, we would like to conclude that the treatment of these patients with “Liquor arsenicalis ..., milk, liquor carnis, peptonoids, peptonised cocoa ... brandy, and port wine” might no longer be applicable.

### References

1. Goenka A, Michael BD, Ledger E, Hart IJ, Absoud M, Chow G, et al. Neurological manifestations of influenza infection in children and adults: results of a National British Surveillance Study. *Clin Infect Dis* 2014;58:775–784. doi: 10.1093/cid/cit922
2. Khandaker G, Zurynski Y, BATTERY J, Marshall H, Richmond PC, Dale RC, et al. Neurologic complications of influenza A(H1N1)pdm09 surveillance in 6 pediatric hospitals. *Neurology* 2012;79:1474–1481. doi: 10.1212/WNL.0b013e31826d5ea7
3. Michael BD, Sidhu M, Stoeter D, Roberts M, Beeching NJ, Bonington A, et al. Acute central nervous system infections in adults—a retrospective cohort study in the NHS North West region. *QJM* 2010;103:749–758. doi: 10.1093/qjmed/hcq121
4. Ryan MM, Procopis PG, Ouvrier RA. Influenza A encephalitis with movement disorder. *Pediatr Neurol* 1999;21:669–673. doi: 10.1016/S0887-8994(99)00062-4
5. Mccarthy PA. Chorea following influenza in a woman aged sixty-five. *Lancet* 1892;139:745. doi: 10.1016/S0140-6736(02)15384-0
6. Akins PT, Belko J, Uyeki TM, Axelrod Y, Lee KK, Silverthorn J. H1N1 encephalitis with malignant edema and review of neurologic complications from influenza. *Neurocrit Care* 2010;13:396–406. doi: 10.1007/s12028-010-9436-0
7. Takanashi JI, Barkovich AJ, Yamaguchi KI, Kohno Y. Influenza-associated encephalitis/encephalopathy with a reversible lesion in the splenium of the corpus callosum: A case report and literature review. *Am J Neuroradiol* 2004;25:798–802.
8. Surana P, Tang S, McDougall M, Tong CYW, Menson E, Lim M. Neurological complications of pandemic influenza A H1N1 2009 infection: European case series and review. *Eur J Pediatr* 2011;170:1007–1015. doi: 10.1007/s00431-010-1392-3
9. Wang GF, Li W, Li K. Acute encephalopathy and encephalitis caused by influenza virus infection. *Curr Opin Neurol* 2010;23:305–3011. doi: 10.1097/WCO.0b013e328338f6c9
10. Ormitti F, Ventura E, Summa A, Picetti E, Crisi G. Acute necrotizing encephalopathy in a child during the 2009 influenza A(H1N1) pandemic: MR imaging in diagnosis and follow-up. *AJNR Am J Neuroradiol* 2010;31:396–400. doi: 10.3174/ajnr.A2058