



PRIMARY OVARIAN ECTOPIC PREGNANCY: AN UNUSUAL CASE REPORT

Dr. Kranti Bisht*¹, Dr. Akshita Thakur² and Dr. Ankit Chaudhary³

¹Consultant Obstretian, Civil Hospital Thural, Distt Kangra H.P 176107.

²Junior Resident, Deptt of Surgery, PGIMER Chd.

³Medical officer, Civil Hospital, Nagrota Bagwan Distt. Kangra H.P. 176047.



*Corresponding Author: Dr. Kranti Bisht

Consultant Obstretian, Civil Hospital Thural, Distt Kangra H.P 176107.

Article Received on 21/10/2023

Article Revised on 11/11/2023

Article Accepted on 01/12/2023

ABSTRACT

Ovarian pregnancy is rare variant of ectopic pregnancy. An accurate preoperative diagnosis is very challenging various advances in diagnostic modalities like Transvaginal ultrasonography has evolved in identifying an ovarian pregnancy. It results in significant maternal morbidity, fetal loss, repeat ectopic, impairment of subsequent fertility. The case report a 34-year female who presented with pain and severe anemia and explored keeping in view ruptured tubal ectopic but intraoperatively diagnosed as primary ovarian pregnancy and managed conservatively by ovarian wedge resection.

KEYWORDS: Ectopic, Ovarian, Pregnancy.

INTRODUCTION

Ovarian pregnancy is a rare event with incidence between 1 in 2100 to 1 in 7000 pregnancies, or 1-3% of all ectopic pregnancies.^[1] Ovarian pregnancy is frequently misdiagnosed clinically as a tubal ectopic pregnancy. Intraoperative, it is difficult to differentiate ovarian pregnancy, ruptured corpus luteal cyst or haemorrhagic ovarian cyst. Ovarian pregnancy should satisfy the criteria described by Spigelberg:^[2] (a) intact fallopian tube on the affected side, (b) fetal sac must occupy the position of the ovary on the affected side, (c) ovary connected to the uterus by ovarian ligament, (d) ovarian tissue must be located in the sac wall, to be confirmed by histopathology. There is an obvious need to differentiate between tubal ectopic and ovarian ectopic pregnancies as it will aid in management.^[3,4] Thus, here it lies the necessity of reporting this case.

CASE REPORT

A total 34 years old G3P2002 reported to labour room with complaint of pain abdomen, generalized weakness and fainting attacks for 3-4 days. On examination patient was conscious, cooperative and well oriented to time place and person. She was pale, her pulse was 128/min, BP = 90/60 mmHg. On per abdomen examination there was tenderness in lower abdomen. Per speculum examination cervix and vagina were normal and there was no bleeding, on per vaginum examination cervix was downward forward and cervical motion tenderness was present, uterus

was retroverted multiparous size, there was tenderness and fullness in b/l fornix and POD. Her hemoglobin was 5 gm, urine pregnancy test was positive, and paracentesis was also positive, possibility of ruptured ectopic pregnancy was kept. Patient was resuscitated and simultaneously prepared for exploratory laparotomy in view of ruptured ectopic pregnancy. On opening abdomen there was hemoperitoneum of about 800 ml with 200 gm clots. On exploration uterus along with b/l tubes were grossly normal. Left ovary was enlarged, cystic and g sac like structure was seen, there was a rent on it which was actively bleeding (Figure 1). Wedgeresection of left ovary was done and sent for histopathology. Intraoperatively 1unit of blood was given.

Post operatively 2-unit blood was transfused. Histopathology report came consistent with ovarian pregnancy (Figure 2). Thus, the intraoperative findings and the histopathology examination satisfied the criteria for ovarian pregnancy as described by Spigelberg.^[3] The post-operative period was uneventful and patient was discharged successfully on 7th day after skin suture removal.

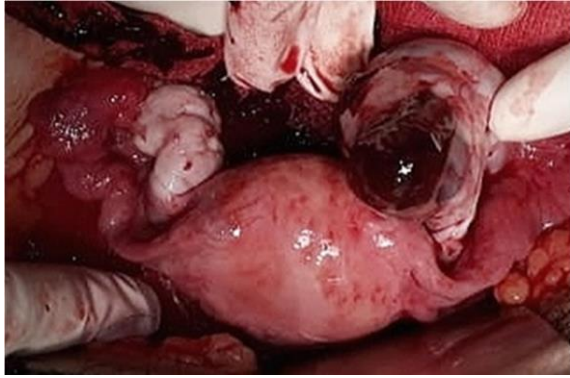


Figure 1: Intraoperative picture of ovarian ectopic pregnancy.

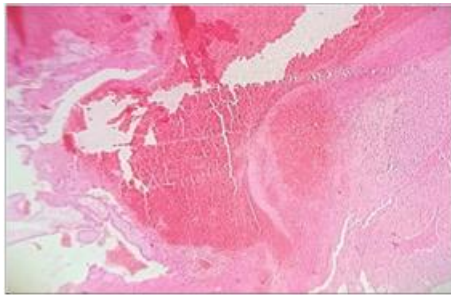


Figure 2: Histopathological picture of ovarian ectopic.

DISCUSSION

Primary ovarian pregnancy is one of the rarest types of extra-uterine pregnancy. Ectopic pregnancy is the most important cause of maternal death in the first trimester accounting for approximately 10% of deaths related to pregnancy. Younger age, endometriosis, pelvic inflammatory disease, intra-uterine devices, ovulatory medications, and assisted reproductive techniques are risk factors.^[5] The signs and symptoms of ovarian pregnancy are similar to disturbed tubal pregnancy, conditions most commonly confused with ruptured hemorrhagic corpus luteum and chocolate cyst or tubal ectopic pregnancy. Rupture in the first trimester is the usual rule in an ovarian ectopic. With few exceptions, the initial diagnosis is made on the operating table and the final diagnosis only on histopathology on the basis of the four.

Spigelberg criteria, establishing that the pregnancy is limited to the ovary and does not involve the tube.^[2] The etiology of ovarian pregnancy remains unclear, it occurs as a result of a fertilized ovum getting implanted on the ovarian tissue. Out of the modern methods, ultrasonography, laparoscopy and estimation of human chorionic gonadotrophic (hCG) levels have been used in conjunction with repeated clinical evaluation in the diagnosis and management of extra uterine pregnancies.^[6]

^[8]Laparotomy was performed in this case as the patients arrived in hemodynamically unstable condition. The established modes of surgical

treatment of ovarian pregnancy are either removal of the entire ovary containing the ectopic gestation or performing a wedge resection of the ovary. Because of viable ovarian tissue of the affected side and young age of the patient, wedge resection with enucleation of the sac was done. Histologically, this case revealed placental and trophoblastic tissue in the ovarian tissue, indicative of the ovarian origin of the ectopic pregnancy. Hence, a diagnosis of primary ovarian pregnancy was made.

Funding: No funding sources Conflict of interest: None declared Ethical approval: Not required

REFERENCES

1. Comstock C, Huston K, Lee W. The ultrasonographic appearance of ovarian ectopic pregnancies. *Obstet. Gynecol*, 2005; 105: 42-5.
2. Spigelberg O. Casusistik der ovarial schwangerschaft. *Arch Gynecol*, 1878; 13: 73.
3. Roy J, Sinha Babu A. Ovarian pregnancy: two case reports. *AMJ*, 2013; 6(8): 406-10.
4. Nath PK, Panigrahy S, Nath SS, Rout PK, Mohanta C. Primary ovarian ectopic pregnancy: a rare case report. *J Evolut Med Dent Sci.*, 2013; 2(48): 9339-41.
5. Das S, Kalyani R, Lakshmi V, Kumar MLH. Ovarian pregnancy. *Indian J Pathol Microbiol*, 2008; 51(1): 37-8.
6. Bradley WG, Fiske CE, Filly RA. The double sac sign of early intrauterine pregnancy: use in exclusion of ectopic pregnancy. *Radiol*, 1982; 143(1): 223-6.
7. Chinn DH, Callen PW. Ultrasound of the acutely ill obstetrics and gynecology patient. *Radiol Clin NorthAm*, 1983; 21(3): 585-94.
8. Lawson TL. Ectopic pregnancy: criteria and accuracy of ultrasonic diagnosis. *AJR Am J Roentgenol*, 1978; 131(1): 153-6.