EUROPEAN JOURNAL OF BIOMEDICAL AND PHARMACEUTICAL SCIENCES
http://www.ejbps.com

ISSN 2349-8870
Volume: 8
Issue: 7
42-46
Year: 2021

EFFECTS OF INTRAOPERATIVE EPIDURAL ADMINISTRATION OF ROPIVACAINE ON POSTOERATIVE ANALGESIA IN SCOLIOSIS SURGERY: A RETROSPECTIVE STUDY

***Tomoki Nishiyama MD, PhD**

Department of Emergency Medicine (Anesthesiology), Maruyama Memorial General Hospital, 2-10-5, Hon-cho, Iwatsuki-ku, Saitama-shi, Saitama, 339-8521, Japan.

***Corresponding Author: Tomoki Nishiyama MD, PhD**
Department of Emergency Medicine (Anesthesiology), Maruyama Memorial General Hospital, 2-10-5, Hon-cho, Iwatsuki-ku, Saitama-shi, Saitama, 339-8521, Japan.

Article Received on 01/05/2021 **Article Revised on 21/05/2021** **Article Accepted on 11/06/2021**

ABSTRACT

Background: Scoliosis surgery induced severe postoperative pain. We investigated postoperative analgesic effects of intraoperative epidural administration of ropivacaine in spinal fusion surgery for scoliosis. **Methods:** Patient records of 20 patients aged 20 to 40 years, who received scoliosis surgery (posterior spinal fusion of 6 to 15 vertebrae), 10 of these received intraoperative epidural administration of ropivacaine (epidural group) and 10 did not receive epidural ropivacaine (control group) in the same period, were extracted to match their background. Anesthesia was induced with midazolam, propofol, fentanyl and vecuronium, and maintained with infusion of propofol and remifentanil. After surgery subdermal infusion of fentanyl 25 µg/h was administered. In the epidural group only, a direct epidural administration of 0.375% ropivacaine about 1.5 mL/vertebra was done by surgeon when epidural space was visible during surgery. Anesthetics, hemodynamics, pain shown by visual analog scale (VAS; 0-10), and consumption of rescue analgesics were extracted from patients' records, and compared between the two groups. **Results:** Consumption of remifentanil, nicardipine, and pentazocine were significantly smaller in the epidural group. Blood pressure at the end of anesthesia, heart rate at 2, 6, 12, and 24 hours after surgery, and pain shown by visual analog scale (VAS) at 1, 2, 6, and 12 hours after surgery were significantly smaller in the epidural group. **Conclusions:** An epidural administration of 0.375% ropivacaine during surgery was effective for postoperative analgesia at least for 12 hours after scoliosis surgery.

KEYWORDS: Scoliosis, postoperative analgesia, epidural block, ropivacaine.

1. INTRODUCTION

Patients with scoliosis surgery have severe postoperative pain. There are many methods studied to decrease postoperative pain in scoliosis surgery such as morphine-based patient-controlled analgesia (PCA), nonsteroidal anti-inflammatory drugs, acetaminophen, gabapentin, epidural analgesia, or intrathecal morphine.[1] We have usually used subdermal infusion of fentanyl, not morphine considering side effects, i.e., itching, nausea and vomit, and not intravenous because venous access is removed on the next day of surgery. However, analgesic effects are not enough with subdermal fentanyl. Many studies[2-5] used continuous epidural block using an epidural catheter. In our country, many surgeons were afraid of infection by an epidural catheter. Therefore, insertion of an epidural catheter is quite difficult and only a few use it. We have preliminary tried an epidural administration of ropivacaine during scoliosis surgery in some patients. In this report, we extracted anesthesia and postoperative records in these patients and compared with the data from patients treated as usual using only a subdermal infusion of fentanyl, whose backgrounds were similar to the patients with epidural analgesia.

2. MATERIALS AND METHODS

Patient records of 20 patients aged 20 to 40 years, American Society of Anesthesiologists physical status I or II, who received scoliosis surgery (posterior spinal fusion of 6 to 15 vertebrae), 10 of these received intraoperative epidural administration of ropivacaine (epidural group) and 10 did not receive epidural ropivacaine (control group) in the same period, and whose backgrounds were similar with the patients in the epidural group, were extracted. Informed consent from patients were obtained with consent for general anesthesia, and approval of Research Committee of the hospital as a retrospective study were obtained.

Anesthesia was induced with midazolam 0.1-0.2 mg/kg, propofol 1-2 mg/kg, fentanyl 3-5 µg/kg and vecuronium

1-1.5 mg/kg, and maintained with infusion of propofol and remifentanil. To decrease blood pressure, nicardipine was infused without any definite protocol. At the end of surgery, diclofenac suppository 50 mg was inserted, and subdermal infusion of fentanyl 25 µg/h was started and continued for 24 hours as a routine protocol. In the epidural group only, a direct epidural administration of 0.375% ropivacaine about 1.5 mL/vertebra (maximum 20 mL) was done by surgeon when epidural space was open during surgery. For postoperative rescue analgesia, intramuscular pentazocine 15 mg was administered when visual analog scale (VAS:0-10) became more than 5 with one hour interval according to the usual protocol.

Consumption of propofol, remifentanil, nicardipine during surgery and pentazocine in postsurgical 24 hours, blood pressure, heart rate, and VAS were compared between the two groups. Statistical analysis was performed using factorial and repeated analysis of variance (ANOVA), and chi-square test. A P value less than 0.5 was considered to be statistically significant.

3. RESULTS

Demographic data were not different between the groups (Table 1). Consumption of remifentanil, nicardipine, and pentazocine were significantly smaller in the epidural group, but not of propofol (Table 2). Blood pressure at the end of anesthesia (Fig. 1), heart rate at 2, 6, 12, and 24 hours after surgery (Fig. 2), and VAS at 0, 1, 2, 6, and 12 hours after surgery (Fig. 3) were significantly smaller in the epidural group. Motor evoked potentials (MEP) disappeared at about 10 to 20 minutes after epidural ropivacaine administration in the epidural group. After surgery, no patients had loss of leg movements in both groups.

Table 1. Demographic data.

	Control group	Epidural group
Age (years)	26 ± 6	27 ± 6
Gender (Male/Female)	5/5	6/4
Height (cm)	162 ± 3	165 ± 11
Body weight (kg)	60 ± 4	58 ± 6
Duration of surgery (min)	309 ± 26	306 ± 31
Number of vertebrals	10 ± 4	9 ± 6
Blood loss (mL)	476 ± 88	477 ± 125

mean ± standard deviation or number of patients

Table 2: Anaesthetics and analgesics.

	Control group	Epidural group
Propofol (mg/kg/h)	6.4 ± 0.4	6.0 ± 0.6
Remifentanil (µg/kg/min)	0.45 ± 0.05	0.16 ± 0.02*
Nicardipine (mg/h)	2.6 ± 0.6	1.6 ± 0.5*
Pentazocine (mg/24h)	56 ± 14	30 ± 12*

mean ± standard deviation, *: P < 0.05 vs. Control group

Figure legends

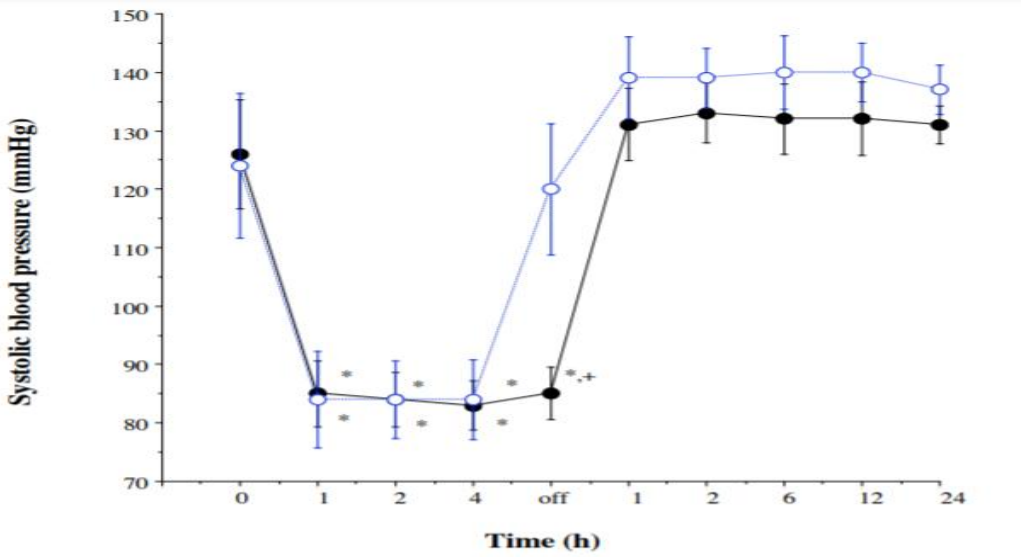

Figure 1: Systolic blood pressure.

Open circles show control group and closed circles show epidural group. Bars indicate standard deviation. *: P < 0.05 vs. the value at time 0 +: P < 0.05 vs. control group.

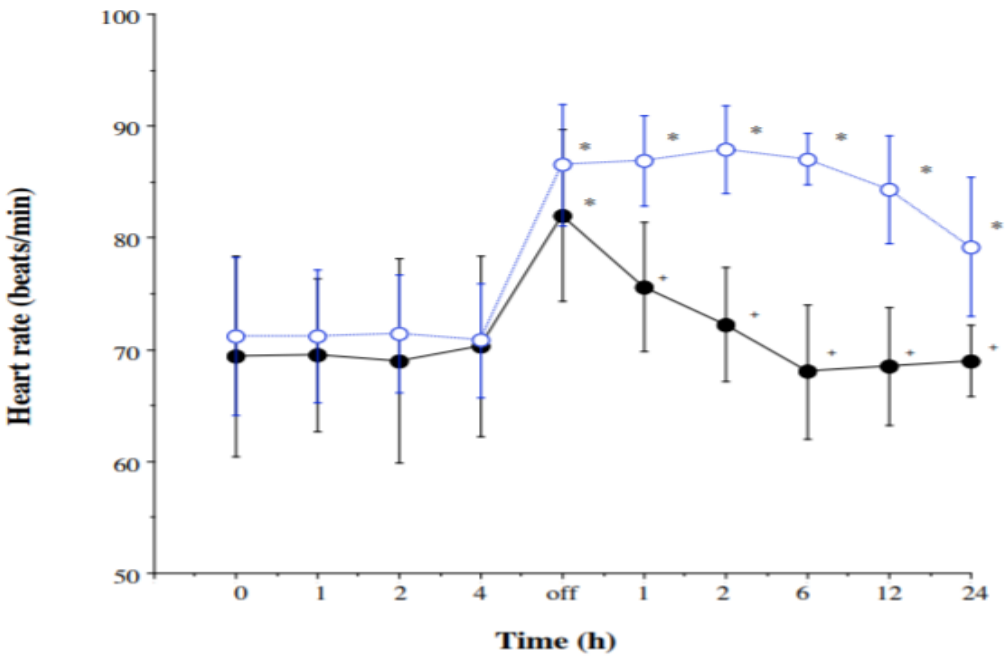

Figure 2: Heart rate.

Open circles show control group and closed circles show epidural group. Bars indicate standard deviation. *: P < 0.05 vs. the value at time 0 +: P < 0.05 vs. control group

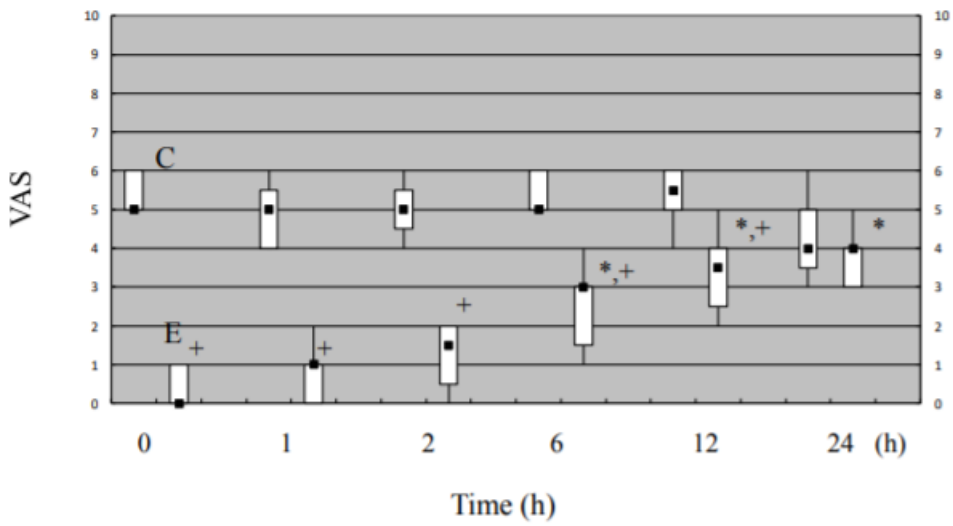

Figure 3: Visual analog scale (VAS).

C, control group; E, epidural group; Open squares show 25th and 75th percentile, solid squares show median, and bars indicate maximum and minimum. *: P < 0.05 vs. the value at time 0 +: P < 0.05 vs. control group.

4. DISCUSSION

This retrospective study showed that an epidural administration of 0.375% ropivacaine during surgery was effective for postoperative analgesia at least for 12 hours after scoliosis surgery. Many methods have been investigated to decrease postoperative pain in scoliosis surgery. Thoracolumbar dorsal ramus nerve block with 0.2% ropivacaine was effective without any complications.[6] However, they used 4 catheters, it might be complicated. Intrathecal morphine was effective in controlling pain for 16 hours postoperatively.[7] In spine surgery, intrathecal administration might increase a risk of infection. Preoperative bilateral erector spinae plane

blocks with 0.25% bupivacaine and epinephrine were reported to be effective in postoperative analgesia in scoliosis surgery for about 48 hours.[8] In comparison to these methods, the most often used is the intravenous PCA, then continuous epidural analgesia.[4,5,9,10]

Continuous epidural infusion of hydromorphone and bupivacaine had effective postoperative analgesia for 48 hours in comparison with intravenous PCA with morphine in posterior spinal fusion surgery.[11] Intraoperative intrathecal morphine with post-operative epidural infusion of ropivacaine was safe and effective analgesic method for post-operative pain in comparison with intravenous PCA with morphine in scoliosis surgery.[12] Continuous epidural 0.3% ropivacaine 4 - 10mL/h x 2 gave better postoperative analgesia, less nausea and vomit, and earlier return of bowel function than continuous intravenous morphine.[3] However, Klatt et al[5] reported that postoperative pain control in scoliosis surgery was equivalent in intravenous PCA with morphine and continuous epidural infusion of bupivacaine and fentanyl. Cassady et al.[10] also showed that analgesic effects were not different between continuous epidural analgesia and PCA, while intestinal peristalsis recovered more rapidly with epidural analgesia. There were no differences in postoperative analgesia, oral intake, bowel sound, ambulation, and length of stay between epidural and intravenous analgesia.[4] Our study did not compare epidural analgesia with subcutaneous fentanyl, but adding epidural ropivacaine was significantly effective at least for 12 hours after surgery.

Sundarathiti et al. inserted epidural catheter before scoliosis surgery and used during and after surgery.[13] Placement of an epidural catheter in spine surgery raises concerns of an increased risk of wound infection and systemic absorption of analgesic medications.[14] Therefore, our surgeons do not want to have an epidural catheter. Sucato et al. showed that 13.1% of epidural analgesia stopped due to pain not controlled because of inadequate catheter placement.[9] This high failure rate is also one of the reasons why our surgeons do not use an epidural catheter. This study has another concern of the risk of damaging epidural catheter during surgery. Yoshimoto et al.[14] used single-shot epidural anesthesia with bupivacaine and morphine just before general anesthesia and removed epidural catheter after injection, i.e. before surgery. However, in such a case, we do not need to insert an epidural catheter. Single shot epidural injection is enough.

We administered 0.375% ropivacaine to get anesthesia during surgery in these patients as test cases. MEP disappeared after administration of ropivacaine. This should be avoided to decrease nerve injury by surgical procedure. However, motor block was not observed after surgery in all patients. Continuous epidural administration of morphine with 0.125% bupivacaine or 0.2% ropivacaine at 6 mL/h did not induce any changes in neurological function test.[2] Sacral motor neuron function was kept when 0.125% bupivacaine or 0.2% ropivacaine was epidurally administered at 6 mL/h,[2] while Zaric et al. showed 0.25% bupivacaine or 0.2% and 0.3% ropivacaine 10 mL/h induced motor block.[15] In the report by Park et al., an epidural infusion of ropivacaine 0.2% caused a transient motor block in 22% of patients.[16] From these studies, ropivacaine should be administered as less than 0.2% not to block motor function.

The postoperative analgesic effects of intraoperative epidural 0.375% ropivacaine continued at least for 12 hours, but not 24 hours. We could not detect precise duration of analgesia because we did not have any data between 12 hours and 24 hours in this retrospective study. We need prospective study to find the duration of the effects of intraoperative epidural ropivacaine administration. In addition, like other studies,[2,5,11] narcotics should be added to ropivacaine.

An epidural administration of ropivacaine during scoliosis surgery might be useful, and we need further study to find optimal concentration and dose of ropivacaine and duration of analgesic effects.

REFERENCES

1. Shah SA, Guidry R, Kumar A, White T, King A, Heffernan MJ. Current trends in pediatric spine deformity surgery: multimodal pain management and rapid recovery. Global Spine J, 2020; 10: 346-352.
2. Dan CP, Delécrin J, Péréon Y, Falconi I, Passuti N, Malinge M, Pinaud M. Epidural analgesia after scoliosis surgery: electrophysiologic and clinical assessment of the effects of bupivacaine 0.125% plus morphine versus ropivacaine 0.2% plus morphine. J Clin Anesth, 2008; 20: 17-24.
3. Blumenthal S, Min K, Nadig M, Borgeat A. Double epidural catheter with ropivacaine versus intravenous morphine: A comparison for postoperative analgesia after scoliosis correction surgery. Anesthesiology 2005; 102: 175-180.
4. O'Hara JF Jr, Cywinski JB, Tetzlaff JE, Xu M, Gurd AR, Andrish IT. The effect of epidural vs intravenous analgesia for posterior spinal fusion surgery. Pediatr Anesth, 2004; 14: 1009-1015.
5. Klatt JWB, Mickelson J, Hung M, Durcan S, Miller C, Smith JT. A randomized prospective evaluation of 3 techniques of postoperative pain management after posterior spinal instrumentation and fusion. Spine, 2013; 38: 1626-1631.
6. Xu JL, Tseng V, Delbello D, Pravetz MA. Thoracolumbar dorsal ramus nerve block using continuous multiorifice infusion catheters: A novel technique for postoperative analgesia after scoliosis surgery. Int J Spine Surg, 2020; 14: 222-225.
7. Hong RA, Gibbons KM, Li GY, Holman A, Voepel-Lewis T. A retrospective comparison of intrathecal morphine and epidural hydromorphone for analgesia

following posterior spinal fusion in adolescents with idiopathic scoliosis. Paediatr Anaesth, 2017; 27: 91-97.
8. Chin KJ, Dinsmore MJ, Lewis S, Chan V. Opioid-sparing multimodal analgesia with bilateral bi-level erector spinae plane blocks in scoliosis surgery: a case report of two patients. Eur Spine J, 2020; Suppl 2: 138-144.
9. Sucato DJ, Duey-Holtz A, Elerson E, Safavi F. Postoperative analgesia following surgical correction for adolescent idiopathic scoliosis: A comparison of continuous epidural analgesia and patient-controlled analgesia. Spine, 2005; 30: 211-217.
10. Cassady JF Jr, Lederhaas G, Cancel DD, Cummings RJ, Loveless EA. A randomized comparison of the effects of continuous thoracic epidural analgesia and intravenous patient-controlled analgesia after posterior spinal fusion in adolescents. Reg Anesth Pain Med, 2000; 25: 246-253.
11. Milbrandt TA, Singhal M, Minter C, McClung A, Talwalkar VR, Iwinski HJ, Walker J, Beimesch C, Montgomery C, Sucato DJ. A comparison of three methods of pain control for posterior fusions in adolescent idiopathic scoliosis. Spine, 2009; 34: 1499-1503.
12. Ravish M, Muldowney B, Becker A, Hetzel S, McCarthy JJ, Nemeth BA, Noonan KJ. Pain management in patients with adolescent idiopathic scoliosis undergoing posterior spinal fusion: Combined intrathecal morphine and continuous epidural versus PCA. J Pediatr Orthop, 2012; 32: 799-804.
13. Sundarathiti P, Pasutharnchat K, Jommaroeng P. Thoracic epidural-general analgesia in scoliosis surgery. J Clin Anesth, 2010; 22: 410-414.
14. Yoshimoto H, Nagashima K, Sato S, Hyakumachi Y, Yanagibashi Y, Masuda T. A prospective evaluation of anesthesia for posterior lumbar spine fusion: the effectiveness of preoperative epidural anesthesia with morphine. Spine, 2005; 30: 863-869.
15. Zaric D, Nydahl PA, Philipson L, Samuelsson L, Heierson A, Axelsson K. The effect of continuous lumbar epidural infusion of ropivacaine (0.1%, 0.2% and 0.3%) and 0.25% bupivacaine on sensory and motor block in volunteers. Reg Anesth, 1996; 21: 14-25.
16. Park SY, An HS, Lee SH, Suh SW, Kim JL, Yoon SJ. A prospective randomized comparative study of postoperative pain control using an epidural catheter in patients undergoing posterior lumbar interbody fusion. Eur Spine J, 2016; 25: 1601-1607.