EUROPEAN JOURNAL OF BIOMEDICAL AND PHARMACEUTICAL SCIENCES
http://www.ejbps.com

ISSN 2349-8870
Volume: 8
Issue: 3
357-359
Year: 2021

RETROSPECTIVE STUDY OF CALCIFIED TRITICEOUS CARTILAGE DETECTED ON DIGITAL PANORAMIC RADIOGRAPHS, CORRELATING WITH AGE AND GENDER AND DIFFERENTIATING FROM CAROTID ARTERY CALCIFICATIONS-INSTITUTIONAL STUDY

[1]*Dr. Shalvi Vora, [2]Dr. Freny Karjodkar and [3]Dr. Kaustubh Sansare

[1]Assistant Professor, Department of Oral Medicine and Radiology, Nair Hospital Dental College, Mumbai (India).
[2]Head of Department, Department of Oral Medicine and Radiology, Nair Hospital Dental College, Mumbai (India).
[3]Associate Professor, Department of Oral Medicine and Radiology, Nair Hospital Dental College, Mumbai (India).

***Corresponding Author: Dr. Shalvi Vora**
Assistant Professor, Department of Oral Medicine and Radiology, Nair Hospital Dental College, Mumbai (India).

Article Received on 11/12/2020 **Article Revised on 01/02/2021** **Article Accepted on 22/02/2021**

ABSTRACT
Objectives: The purpose of this study was detect prevalence of calcified triticeous cartilage on digital panoramic radiograph of an institutional population and to differentiate calcified triticeous cartilage from carotid artery calcification. **Material and Methods:** Retrospective study was conducted on 500 archived digital panoramic radiographs of Indian adults to check prevalence of Calified triticeous cartilage. The Calcified Triticeous Cartilage was identified as an oval with a smooth, well‑defined radiopacity located between the superior horn of the thyroid cartilage and the greater horn of the hyoid bone at the level of the third and the fourth cervical vertebrae. **Results:** Calcified triticeous cartilage were present in 15 patients 10 were male and 5 were female. Out of 15 cases; 7 patients showed unilateral calcified triticeous cartilage and 8 showed bilateral triticeous cartilage. **Conclusions:** Careful attention to differences in morphology and location of calicified triticeous cartilage and carotid atheroma on panoramic radiographs enables clinician to distinguish between two.

KEYWORDS: Carotid atheroma, Panoramic radiograph, Triticeous cartilage.

INTRODUCTION
Triticeous cartilage is ovoid cartilaginous structure located in thyrohyoid ligament. Thyrohyoid ligament extends from distal aspect of greater cornu of hyoid bone to the tip of superior cornu of the thyroid cartilage. Triticeous cartilage is small ovoid cartilage found to be located within this ligament at the level of C3 and C4 vertebrae.[1,2]

Though the role of triticeous cartilage is unidentified; some researchers believe that it may serve to reinforce the thyrohyoid ligament.[3-5] The word triticeous comes from the Latin triticeus, meaning resembling a grain of wheat.

Just like other structures of the laryngeal skeleton, the triticeous cartilage undergoes calcification. In some cases, and becomes visible on panoramic radiographs, especially when the visual field extends inferiorly.[5,6]

Due to its similar location on a panoramic radiograph; the triticeous cartilage can be misdiagnosed as a carotid artery calcification. Since calcified carotid atheromas are a risk factor for stroke, clinicians need to differentiate between a calcified triticeous cartilage and a calcified carotid atheroma.[4,5]

However, although sharing the common location on panoramic radiographs; these two entities can be differentiated easily based on their shape. Calcification of carotid arteries or carotid atheroma may be visualized by number of imaging methods that show a view of the cervical region. These radiographic examinations include cephalometric, panoramic and postero-anterior skull.[4]

However there are no any known radiological investigations for calcified triticeous cartilage. Hence purpose of this study was to evaluate types of calcifications in an Indian population by means of digital panoramic radiographs.

Summarize the rationale and purpose of the study, giving only pertinent references. Clearly state the working hypothesis.

MATERIAL AND METHODS
This was a retrospective study conducted on 500 archived digital panoramic radiographs of Indian adults

taken originally for oral and dental diagnostic reasons in a dental institution in Mumbai, India.

Each radiograph was taken on same machine K 9000 C 3D having exposure parameters of 60-90kV and 2-15 mA and exposure time 9-10.8 sec. One investigator assessed the images on the same monitor over three sessions spaced by a 20-day period. To reduce the errors, 100 images were randomly chosen and rechecked 15 days later.

The Calcified Triticeous Cartilage was identified as an oval with a smooth, well-defined radiopacity located between the superior horn of the thyroid cartilage and the greater horn of the hyoid bone at the level of the third and the fourth cervical vertebrae (Figure 1).

Statistical Analysis

Data collected was compiled on to a MS Office excel worksheet & was subjected to statistical analysis using an appropriate package SPSS software.

Descriptive statistics like frequency (n) & percentage (%) of categorical data, mean & Standard deviation of numerical data in each group was depicted. Keeping alpha error at 5% and Beta error at 20%, power at 80%, $p<0.05$ was considered statistically significant.

RESULTS

We included 500 panoramic radiographs in our study out of which 275 were of male patient and 225 were of female patients. Age range of the included patients was from 20 years to 68 years with mean age of 31.55 years.

Calcified triticeous cartilage were present in 15 patients 10 were male and 5 were female.

Out of 15 cases; 7 patients showed unilateral calcified triticeous cartilage and 8 showed bilateral triticeous cartilage. In unilateral cases; 4 out of 7 were present on left side and 3 were on right side. Out of 10 male patients; 5 showed bilateral and out of 5 female patients 3 showed bilateral. (Table 1).

TABLES

Table1: Comparision of frequency of calicified triticeous cartilage with gender.

		PRESENT						
		L	NIL	R	RL	Total	Chi square value	p value of chi square test
Gender	M	3	265	2	5	275		
	F	1	220	1	3	225	1.019	0.797#
	Total	4	485	3	8	500		

There was a statistically non significant difference seen for the frequencies between the groups ($p>0.05$)

FIGURES

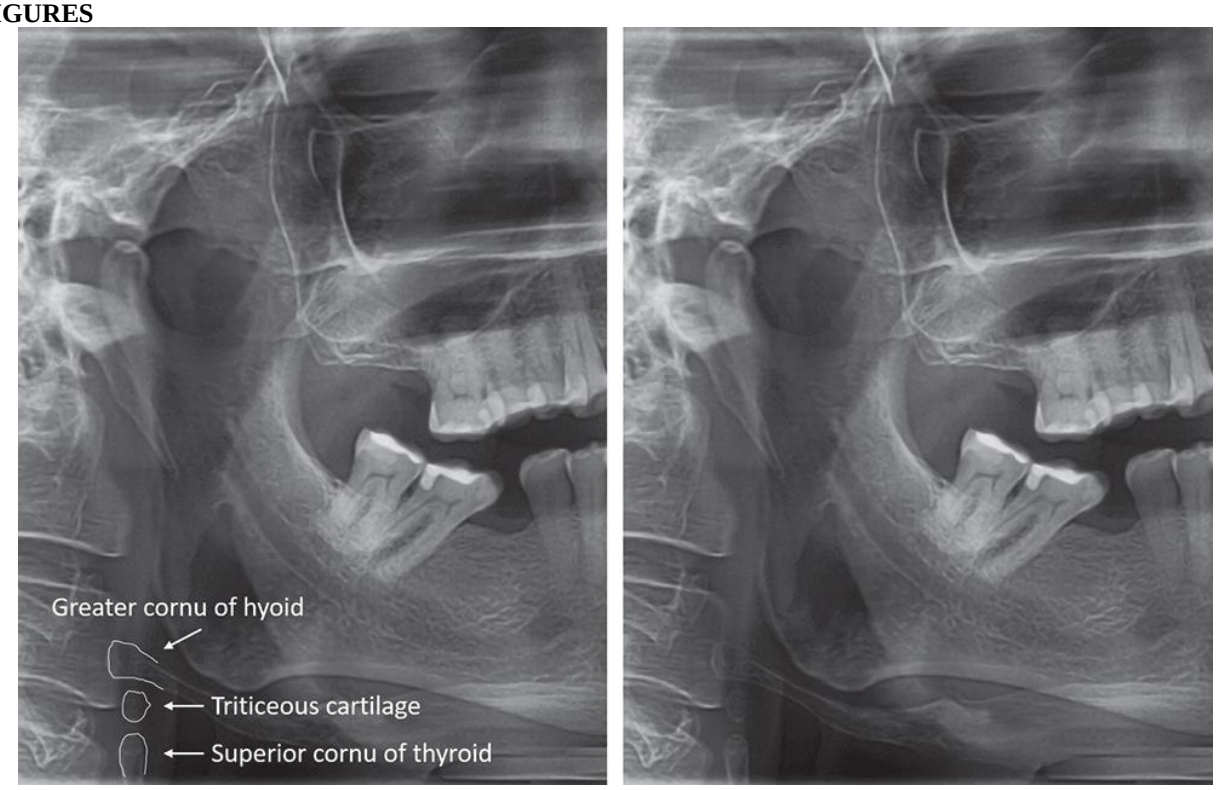

Figure 1: Cropped panoramic image of region of C3 C4 vertebrae showing ovoid calcified structure considered as Calcified Triticeous Cartilage in our study.

DISCUSSION

Soft tissue calcifications of head and neck region are generally asymptomatic. These calcifications may be accidentally detected on panoramic radiographs. In these conditions calcified triticeous cartilage can be mistaken as Carotid artery calcifications because of similar location. Carotid artery calcification may be dangerous potentially leading to cerebrovascular accidents.[7,8]

Small number of studies in the literature studied calcified triticeous cartilage in different populations. Alqahtani et al.[3] and Hatley et al.[9] used, respectively, computed tomography technique and neck radiographs to describe its appearance.

In our study conducted in Indian population showed incidence 3 % which can not be compared with any other study in the literature because of difference in assessment methods.

In the study conducted in Lebanese adults using panoramic by Georges Aoun[1] the incidence of calcified triticeous cartilage was found 10.6 %.

Ahmad et al[4] found incidence as 8.6 % which is greater than our results. This difference in incidence may be attributed to different sample size.
In our study there was statistically non-significant difference noted with respect to age. Though Georges Aoun et al found low positive correlation between age and Calcified triticeous cartilage, with an average of 55.6 years. This difference in the results can be attributed to different sample population and different age groups involved in the study.
Ahmad et al.[4] report of female predominance, there was no significant connection between CTC and gender in our study.

CONCLUSIONS

Careful attention to differences in morphology and location of calicified triticeous cartilage and carotid atheroma on panoramic radiographs enables clinician to distinguish between two. However no active treatment is required for calcified triticeous cartilage; patients with carotid atheroma should be referred to physician for further evaluation of cardiovascular risk.

ACKNOWLEDGMENTS AND DISCLOSURE STATEMENTS

NO CONFLICT OF INTEREST

REFERENCES

1. Georges Aoun, Ibrahim Nasseh Calcified Triticeous Cartilage Detected on Digital Panoramic.
2. Radiographs in a Sample of Lebanese Population J Clin Imaging Sci., 2018; 8: 16.
3. Alqahtani E, Marrero DE, Champion WL, Alawaji A, Kousoubris PD, Small JE. Triticeous cartilage CT imaging characteristics, prevalence, extent, and distribution of ossification. Otolaryngol Head Neck Surg, 2016; 154: 131‑7.
4. Ahmad M, Madden R, Perez L. Triticeous cartilage: Prevalence on panoramic radiographs and diagnostic criteria. Oral Surg Oral Med Oral Pathol Oral Radiol Endod, 2005; 99: 225-30.
5. Carter LC. Discrimination between calcified triticeous cartilage and calcified carotid atheroma on panoramic radiography. Oral Surg Oral Med Oral Pathol Oral Radiol Endod, 2000; 90: 108-10.
6. Taylor E, editor. Dorland's illustrated medical dictionary. 27th ed. Philadelphia: WB Saunders, 1988.
7. Nasseh I, Sokhn S, Noujeim M, Aoun G. Considerations in detecting soft tissue calcifications on panoramic radiography. J Int Oral Health, 2016; 8: 742-6.
8. Cohen SN, Friedlander AH, Jolly DA, Date L. Carotid calcification on panoramic radiographs: An important marker for vascular risk. Oral Surg Oral Med Oral Pathol Oral Radiol Endod, 2002; 94: 510-4.
9. Hatley W, Samuel E, Evison G. The pattern of ossification in the laryngeal cartilages: A radiological study. Br J Radiol, 1965; 38: 585-91.