



HEPATOPROTECTIVE ACTIVITY OF ETHANOLIC EXTRACT OF CASSIA OBTUSIFOLIA SEED AGAINST PARACETAMOL-INDUCED LIVER DAMAGE IN WISTAR RATS

¹Huda S. A. A. Mohamed*, ²Warda S. Abdelgadir, ³Samia M. A. Elbadawi

¹Faculty of Pharmacy, University of Medical Sciences and Technology, Sudan.

²Food Research Centre, Ministry of Science and Communications.

³Faculty of Veterinary Medicine, University of Khartoum.

Article Received on 28/10/2014

Article Revised on 20/11/2014

Article Accepted on 11/12/2014

*Correspondence for
Author

Dr. Huda S. A. A.
Mohamed

Faculty of Pharmacy,
University of Medical
Sciences and Technology,
Sudan.

ABSTRACT

The hepatoprotective activity of the ethanol extract of Cassia obtusifolia seeds were investigated against paracetamol (PCM) – induced liver damage in rats. Thirty rats were divided into 5 equal groups each of 6 rats. Group 1 (control) animals were fed the normal diet. Group 2 received paracetamol at 1g/kg body weight. Group 3 received the standard drug, Silymarin at 70 mg/kg. Group 4 and 5 received the ethanol extract at 250 and 500 respectively. Blood

samples were collected at zero time and at the end of the experimental period (7 days) for biochemical parameters and when the rats were sacrificed, and samples of liver were taken for histological study. Liver damage was assessed by liver morphology, histology and estimation of plasma enzyme activities of aspartate aminotransferases (AST), alanine aminotransferase (ALT) and alkaline phosphatase (ALP) and the concentration of the total protein, albumin and bilirubin. Treatment with ethanol extract of Cassia obtusifolia significantly ($P < 0.05$) reduced paracetamol-induced elevation in plasma liver marker enzymes and the concentrations of total protein, albumin and bilirubin and ameliorated histopathological liver damage and decreased hemorrhage, congestion, fatty change and hepatic necrosis. Hence Cassia obtusifolia extract can be used as hepatoprotective drug, thereby preventing the process of initiation and progress of hepatocellular diseases.

KEYWORDS: Cassia obtusifolia, Ethanol extract, paracetamol, liver damage.

INTRODUCTION

Liver damage, as a result of toxicity or of other diseases, remains one of the most severe health problems and is associated with distortion of various metabolic functions causing cellular necrosis, increase in tissue lipid peroxidation and depletion in the tissue Glutathione (GSH) levels. In addition serum levels of many biochemical markers like GOT, GPT, triglycerides, cholesterol, bilirubin, alkaline phosphatase are elevated (Mascolo, et al., 1998). It is well known that reactive oxygen and nitrogen species play a crucial role in the initiation and progression of liver associated diseases such as alcoholic and viral hepatitis, nonalcoholic steatosis, and hepatocellular carcinoma (Hsiao et al., 2004; Nagata et al., 2007). The free radicals cause cell damage through mechanism of covalent binding and lipid peroxidation with subsequent tissue injury (Brattin et al., 1985). Antioxidant agents of natural origin have attracted special interest because they can protect the body from free radicals (Osawa et al., 1990).

Researches reported that natural products with antioxidant activity are effective to prevent the oxidative stress-related liver pathologies due to particular interactions and synergisms. (Vitaglione et al., 2007). Herbal products and traditional medicines with better effectiveness and fewer side effects in therapeutics could replace the synthetically derived drugs in modern allopathic medication system. (Sakthivel et al., 2012).

Many bioactive compounds and extracts from plants such as *Moringa oleifera*, curcumin from *Curcuma longa* and Salidroside from *Rhodiola sachalinensis* have thus been investigated for hepatoprotective and antioxidant effects against hepatotoxin-induced liver damage (Wu et al., 2008; Choi et al., 2009). Therefore, there is a great demand for development of an effective hepatoprotective drug from the natural products.

The seeds of *Cassia obtusifolia* were chosen for this study. An experiment was designed in an attempt to phytochemically screen and evaluate the hepatoprotective capacity of *C. obtusifolia* seeds ethanolic extract for the treatment of paracetamol (PCM) intoxicated liver.

MATERIALS AND METHODS

Plant material

The seeds of *Cassia obtusifolia* were purchased from Omdurman local market, Sudan Fig. 1. The plant was authenticated by the botanists at the Medicinal and Aromatic Plants Research Institute, National Center for Research, Khartoum, Sudan.



Fig. 1. Cassia obtusifolia seeds

Preparation of the plant extract

The seeds were cleaned allowed to dry at room temperature for 24 hours, and then made into powder using an electrical grinder. Three hundred gm of the powdered seeds was extracted according to Wall et al. (1952) with 70% ethanol using an electric shaker for about three days and daily filtration and evaporation of the solvent using rotary evaporator. The extract was then allowed to fully dry by air and the yield percent was calculated as followed:

Weight of extract / weight of sample X 100

Phytochemical analysis

General phytochemical screening for the active constituents of Cassia obtusifolia seed was carried out using the methods described by Harborne (1984) and Sofowora (1993). Tannins, sterols and triterpenes, alkaloids, flavonoids, saponins, coumarins, Anthraquinone glycoside and cyanogenic glycoside were detected.

Experimental animals and housing

Thirty Wistar rats, (120-170g) were obtained from the Medicinal and Aromatic Plants, Research Institute, National Centre for Research, Khartoum, Sudan, reared within the premises of the Department of Pharmacology and Toxicology, Faculty of Veterinary Medicine, University of Khartoum under 12 hours photoperiod with feed (Table 1) and drinking water provided ad libitum before the commencement of experiment. Room temperature was maintained at $25\pm 2^{\circ}\text{C}$ at adequate house ventilation.

Table 1: Percent inclusion rates (fresh basis) of ingredients of the basal diet fed to experimental rats.

Ingredients	%
Meat meal	42.5
Grain starch	39.2
Granulated Sugar	05.0
Cellulose Powder	03.0
Corn oil	05.0
Super Concentrate	05.0
DL- methionine	00.3
Total	100

Hepatoprotective activity

The rats were divided into 5 groups each of 6 rats. Group 1 were administered orally with distilled water (1 ml/kg body weight/rat) and served as control, Group 2 received oral doses of PCM at 1 g/kg body weight/rat, Group 3 received Silymarin orally at 70 mg/ kg body weight for 7days. Groups 4 and 5 received oral doses of Cassia obtusifolia seed ethanolic extract, 250 and 500 mg/kg body weight, respectively. Groups 3, 4 and 5 were given simultaneous oral doses of PCM (1 g/ kg body weight) dissolved in water for 7 days. Before the commencement of the experimental treatment, blood was collected from the orbital plexus of anaesthetized rats for serum analysis examination. After the end of the experimental period (7 days), rats were humanly sacrificed and the blood samples were collected for biochemical analysis.

Serobiochemical analysis

Collected blood samples were allowed to clot and sera were separated by centrifugation at 3000 r.p.m for 5 min and stored at -20°C until analyzed. Using a spectrophotometric methods and commercial kits, the parameters determined were Aspartate transaminase (AST), Alanine transaminase (ALT) (Linear Chemicals, Barcelona, Spain) and Alkaline phosphatase (ALP) (Plasmatec Laboratory Products Ltd, Spain) in addition to the concentrations of total protein, albumin and bilirubin (Linear Chemicals, Barcelona, Spain).

Histopathological methods

Necropsy was conducted to identify gross lesions, and specimens of the liver were immediately fixed in 10% neutral buffered formalin, embedded in paraffin wax, sectioned at 5 µm and stained routinely with haematoxylin and eosin (H & E).

Statistical analysis

Mean values in body weight, blood and serum data were expressed as mean \pm SE. One- way Analysis of Variance (ANOVA) was used for determining the significance (Snedecor and Cochran, 1989).

RESULTS

Phytochemical investigation of *Cassia obtusifolia* seed ethanolic extract

The extract yield obtained from 300 gm of the powdered seed was 30gm (10%). Phytochemical screening of the *C. obtusifolia* seed ethanolic extract is presented in Table 2, it revealed the presence of high quantity of tannins, flavonoids, saponins, and anthraquinones (+++), sterols and terpenes (++) in addition to traces of coumarins (+). Alkaloids and cyanogenes were not detected in the ethanolic extract of *C. obtusifolia* seed.

Table 2. Preliminary Phytochemical screening of *Cassia obtusifolia* ethanolic extract

Phyto-constituent	Result	Observation
Alkaloids	-	Not detected
Sterols	++	green colour
Triterpenes	++	Pink colour
Flavonoids	+++	Yellow colour
Saponins	+++	Foam
Coumarins	+	UV fluorescence
Tannins	+++	Green-blue colour
Anthraquinones	+++	Pink colour
Cyanogenic	-	Not detected

(+++)= High, (++) = Moderate, (+) = Trace, (-) = Negative

Clinical signs

Depression and loss of appetite were the main signs in group 2 dosed with PCM at 1gm/kg body weight. No clinical signs were observed in groups 3 given Silymarin, groups, 4 and 5 which are given *C. obtusifolia* seed ethanolic extract, at 250 and 500 mg/kg body weight, respectively.

Post-mortem findings

Unlike the livers of control rats and those of the treated groups 3, 4 and 5, fatty change and congestion were observed in the livers of group 2 orally dosed with PCM.

Growth Changes

The effects of *C. obtusifolia* seed ethanolic extract on body weight and weight gain in rats with PCM-induced liver damage were summarized in Table 3. The control rats (Group1), received the normal diet for 7 days, had significantly the highest ($p<0.05$) body weight gain when compared to the treated groups 2, 3, 4, and 5, whereas, group 2 intoxicated with 1g/kg PCM had significantly ($p<0.05$) the lowest gain. No significant difference was observed in weight gain between group 3 and 5 received Silymarin and 500 mg/kg/day *C. obtusifolia* seed ethanolic extract respectively. Body weight gain in the treated groups 3, 4 and 5 were significantly improved when compared with the intoxicated group (group 2).

Serobiochemical changes

Changes in serum constituents of rats treated with *C. obtusifolia* ethanolic extract were presented in Table 4. At day zero, the activities of the liver enzymes, AST, ALT and ALP and the concentrations of total protein, albumin and bilirubin showed no significant differences in all the treated groups when compared to the control rats. At the end of the experimental period (7 days), administration of PCM (1 g/kg body weight, orally) resulted in significant elevation of hepatospecific serum markers activities, AST, ALT, ALP and the concentrations of total protein, albumin and bilirubin when compared to the control group (Group I).

On administration of the standard drug Silymarin (group 3) and *C. obtusifolia* seed ethanolic extract (group 4 and 5) to the paracetamol-intoxicated animals, the levels of AST, ALT, and ALP were significantly reduced ($P<0.05$) and in a dose dependent manner restored towards the normal levels, when compared to the paracetamol alone treated animals (group 2).

Table 3: Body weight and body weight gain in rats orally treated with *C. obtusifolia* seed ethanolic extract for 7days

Group	Initial body weight (g)	Weight gain (g)
1 Control (normal diet)	149.65±0.30	12.50±0.59 ^a
2 PCM (1g/kg)	150.07±0.63	6.68±0.33 ^d
3 PCM+ Silymarin (70mg/kg)	169.53±0.17	10.60±0.17 ^b
4 PCM+250 mg/kg/day <i>C. obtusifolia</i> extract	119.50±0.36	8.62±0.16 ^c
5 PCM+500 mg/kg/day <i>C. obtusifolia</i> extract	129.87±0.46	9.77±0.71 ^b

Means in the same column with the same letter are not significantly different ($p>0.05$).

Table 4. Average (mean± S.E) level of serum biochemical constituents in rats treated with *C. obtusifolia* seed ethanolic extract on PCM induced hepatotoxicity

Day zero

Groups	AST (iu/l)	ALT (iu/l)	ALP (iu/l)	Total protein (g/dl)	Albumin (g/dl)	Bilirubin (mg/dl)
G 1	174.80±0.17 ^a	39.3±0.44 ^a	87.80±0.14 ^a	6.46±0.10 ^a	3.79±0.72 ^a	0.28±0.01 ^a
G 2	174.44±0.37 ^{ab}	38.7±0.17 ^{ab}	89.42±0.23 ^a	6.29±0.07 ^{ab}	2.79±0.08 ^a	0.27±0.01 ^a
G 3	176.00±0.13 ^a	39.97±0.10 ^a	87.00±0.14 ^a	6.37±0.14 ^{ab}	2.85±0.07 ^a	0.30±0.01 ^a
G 4	175.70±0.18 ^a	40.40±0.13 ^a	89.51±0.19 ^a	6.18±0.20 ^a	2.80±0.10 ^a	0.29±0.01 ^a
G 5	176.18±0.13 ^a	40.00±0.13 ^{ab}	88.43±0.17 ^a	6.65±0.03 ^a	2.84±0.18 ^a	0.28±0.01 ^a

Day 7

Groups	AST (iu/l)	ALT (iu/l)	ALP (iu/l)	Total protein (g/dl)	Albumin (g/dl)	Bilirubin (mg/dl)
G 1	175.73±0.31 ^d	39.69±0.14 ^c	87.50±0.21 ^c	6.29±0.06 ^d	2.74±0.08 ^d	0.29±0.01 ^c
G 2	312.46±2.96 ^a	99.57±0.33 ^a	210.85±0.92 ^a	7.51±0.09 ^a	5.35±0.04 ^a	0.52±0.01 ^a
G 3	180.27±0.15 ^c	50.18±0.28 ^d	91.88±0.22 ^d	6.53±0.09 ^c	2.90±0.20 ^c	0.32±0.01 ^c
G 4	187.04±0.44 ^b	55.87±0.04 ^b	97.74±0.14 ^b	6.86±0.05 ^b	3.51±0.03 ^b	0.37±0.01 ^b
G 5	182.64±0.18 ^c	52.89±0.14 ^c	93.98±0.31 ^c	6.61±0.04 ^c	3.11±0.04 ^c	0.34±0.01 ^b

Means in the same column with the same letter are not significantly different ($P>0.05$).

G1 = (control)

G2 = (PCM 1mg/kg)

G3 = (PCM 1mg/kg+Silymarin 70mg/kg)

G4 = (PCM 1mg/kg+250 mg/kg body weight *C. obtusifolia* seed ethanolic extract)

G5 = (PCM 1mg/kg+500 mg/kg body weight *C. obtusifolia* seed ethanolic extract)

Histopathological changes

Histopathological changes of the livers of experimental groups were presented in figures (2-6). The control rats (group 1) showed normal liver tissue and clear hepatocytes with intact cell membranes and clear central vein (Fig 2). In group 2, (PCM) there were severe tissue damage, congestion, haemorrhage, fatty change, hepatocytic necrosis and dilated sinusoids (Fig. 3). Silymarin dosed group (group 3), very mild congestion and dilatation of sinusoids were seen and the general feature of the tissue details is as in the control group i.e tissue started to repair properly (Fig. 3). In group 4 (PCM +250 mg/kg body weight *C. obtusifolia* seed ethanolic extract), Fatty change, haemorrhage, congestion and hepatic necrosis and no repair can be observed when compared with group 3 (Fig. 5). Very, mild congestion, fatty

change and slight haemorrhage with scattered necrotic foci were observed in group 5 receiving PCM+ *C. obtusifolia* seed ethanolic extract (Fig. 6).

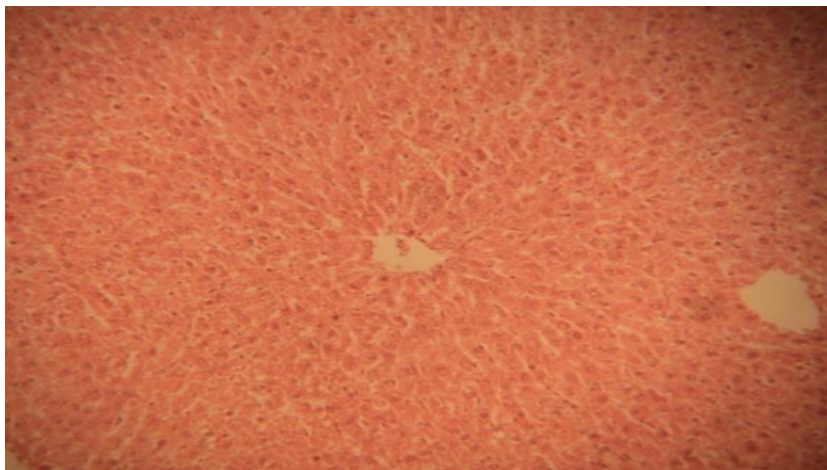


Fig 2. Normal liver tissue and clear hepatocytes with intact cell membranes and clear central vein in control rats;, group 1 (H&E. X100)

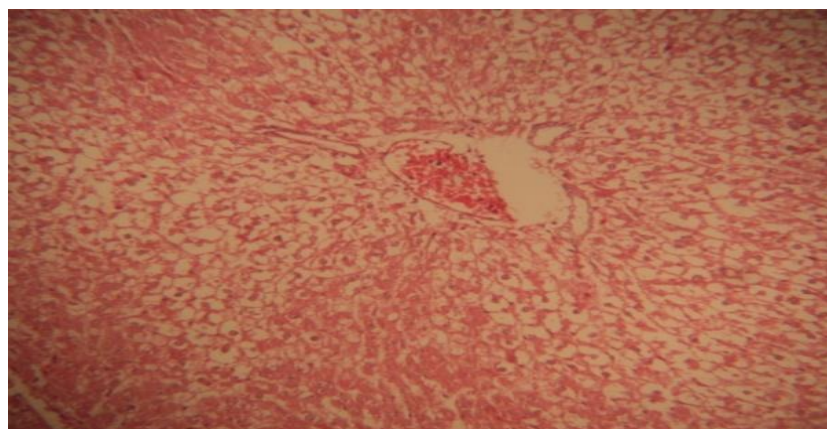


Fig 3. Severe congestion, haemorrhage, fatty change, hepatocytic necrosis and dilated sinusoids in rats intoxicated with PCM; group 2 (H&E. X100)

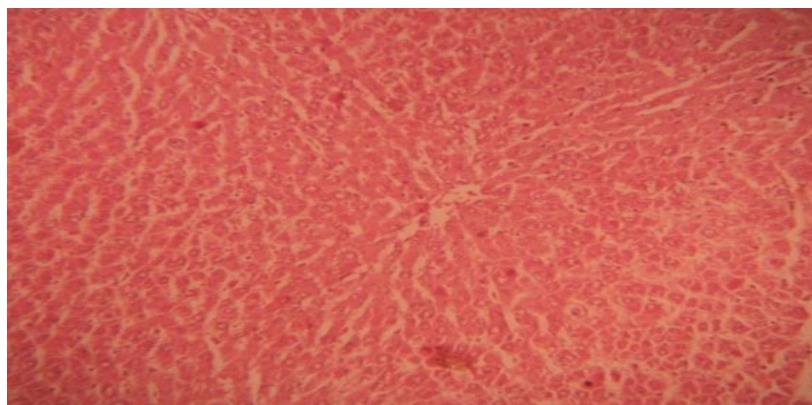


Fig 4. Very mild congestion and dilatation of sinusoids in rats treated with Silymarin; group 3 (H&E.X100)

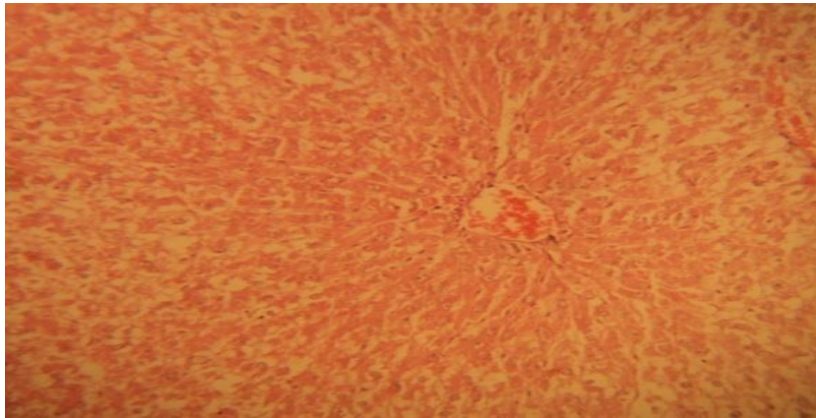


Fig. 5. Fatty change, haemorrhage, congestion and hepatic necrosis in rats treated with *C. obtusifolia* seed ethanolic extract at 250 mg/kg; group 4 (H&E. X100)

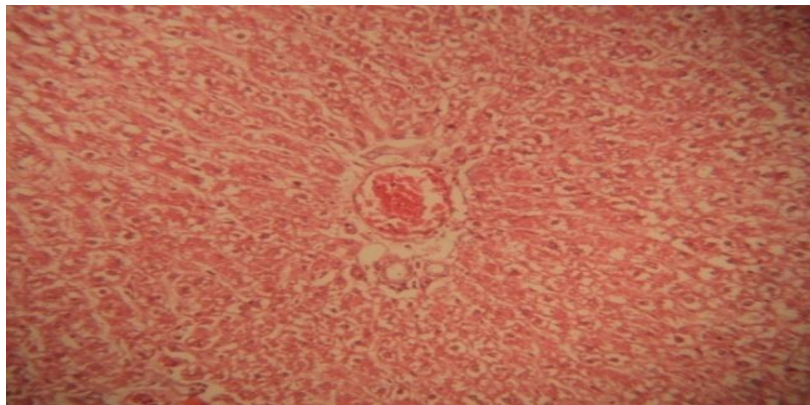


Fig 6. Mild congestion, haemorrhage, fatty change with scattered necrotic foci in rats treated with *C. obtusifolia* seed ethanolic extract at 500 mg/kg; group 5 (H&E. X100)

DISCUSSION

Many herbal drugs or polyherbal combinations are traditionally used in the treatment of liver diseases caused by viruses, alcohol, toxic drugs and plant toxins. These herbs have been studied for their phytochemical constituents, chemical and biological profile and clinical efficacy (Negi *et al.*, 2007).

Paracetamol, a well known compound for producing chemical hepatic injury in mice and rats, has been used as an experimental model to screen the potential hepatoprotective activity of medicinal plants (Vermeulen *et al.*, 1992). It is metabolized primarily in the liver and eliminated by conjugation with sulfate and glucuronide, and then excreted by the kidney. Moreover, paracetamol hepatotoxicity has been attributed to the formation of toxic metabolites, when a part of paracetamol is activated by hepatic cytochrome P-450 to a highly reactive metabolite Nacetyl- p-benzoquinoneimine (NAPQI) (Savides and Oehme, 1983). Toxic metabolites (N-acetyl-p-benzoquineimine) can alkylate and oxidise intracellular GSH,

which results in liver GSH depletion subsequently leads to increased lipid peroxidation by abstracting hydrogen from a polyunsaturated fatty acid and ultimately, liver damage due to higher doses of paracetamol (Mitchell et al., 1973; Grypioti, 2005). Reactive metabolites can exert initial cell stress through a wide range of mechanisms including depletion of glutathione (GSH) or binding to enzymes, lipids, nucleic acids and other cell structures (Pauli-Magnus et al., 2005).

In this study PCM has enhanced the activities of AST, ALT and ALP and the concentrations of total protein, albumin and bilirubin. Serum levels of these parameters are very sensitive markers employed in the diagnosis of liver diseases. When the hepatocellular plasma membrane is damaged, the enzymes normally present in the cytosol are released into the blood stream and can be quantified to assess the type and extent of liver injury (Sallie et al., 1991).

High levels of AST indicate liver damage, such as that due to viral hepatitis, cardiac infarction and muscle injury. ALT catalyses the conversion of alanine to pyruvate and glutamate, and is released in a similar manner. Therefore, ALT is more specific to the liver, and is thus a better parameter for detecting liver injury (Williamson et al., 1996). Serum ALP level on the other hand, is related to the function of hepatic cell. Increase in serum level of ALP is due to increased synthesis of the enzyme, in presence of increasing biliary pressure (Moss and Butterworth, 1974). Hyperbilirubinemia was observed due to excessive heme destruction and blockage of biliary tract. As a result of blockage of the biliary tract there is a mass inhibition of the conjugation reaction and release of unconjugated bilirubin from damaged and dead hepatocytes (Wolf et al., 1997).

The administration of 250 mg/kg and 500 mg/kg *C. obtusifolia* seed ethanolic extract has significantly brought down these elevated levels and exhibited protective effect comparable with the standard drug Silymarin which might be attributed to the maintained structural integrity of hepatocellular membrane. Thabrew and Joice (1987) reported that these parameters return to normal with the healing of hepatic parenchyma and the regeneration of hepatocytes. Toxic metabolites NAPQI leads to covalent modification of cellular target protein, cell death and organ damage (Zaher et al., 1998).

Phytochemical agents have been reported to have medicinal uses (Godwin and Mercer, 1993). High amount of flavonoids, tannins, saponins and anthraquinones were detected in the

ethanolic extract of *Cassia obtusifolia* seed which are reported to possess hepatoprotective activity possibly by ameliorating the extent of oxidative stress caused by paracetamol mediated hepatocellular damage (Scevola *et al.*, 1984; Wegener *et al.*, 1999).

ACKNOWLEDGEMENTS

Authors are grateful to Mr. Mohamed Aldaw, Medicinal and Aromatic Plant Institute, National Centre for Research, the entire technical staff of the Department of Pharmacology and Toxicology, Mr. Abbas El Safi of the Department of Veterinary Pathology and Mr. Altayeb Abbas, Department of Biochemistry for their technical support.

REFERENCES

1. Mascolo N, Sharma R, Jain SC, Capasso F. Ethnopharmacology of *Calotropis Procera* Flowers. *J Ethnopharmacol.* 1998; 22: 211.
2. Hsiao G, Shen M-Y, Lin K-H, Lan M-H, Wu L-Y, Chou D-S, Lin C-H, Su C-H, Sheu JR. Antioxidative and hepatoprotective effects of *Antrodia camphorata* extract. *J Agric Fd Chem*, 2003; 51 (11):3302–3308.
3. Nagata K, Suzuki H, Sakaguchi S. Common pathogenic mechanism in development progression of liver injury caused by non-alcoholic or alcoholic steatohepatitis. *J Toxicol Sci*, 2007; 32(5):453–468.
4. Brattin WJ, Glenda EA, Jr, Recknagel RO. Pathological mechanisms in carbon tetrachloride hepatotoxicity. *J. Free Radical Biol. Med*, 1985; 1:27-38.
5. Osawa T, Namiki M, Kawakishi S. Role of dietary antioxidants in protection against oxidative damage. In: Kuroda Y, Shankei DM, Waters D (eds.). *Antimutagenesis and Anticarcinogenesis Mechanism* 11, New York; Plenum Press: 1990, pp. 139-153.
6. Vitaglione P, Morisco F, Caporaso N, Fogliano V. Dietary antioxidant compounds and liver health. *Crit Rev Fd Sci Nutr*, 2004; 44(7-8):575–586.
7. Sakthivel KM, Guruvayoorappan C. *Biophytum sensitivum*: ancient medicine and modern targets. *J Adv Pharm Technol Res*, 2012; 3(2):83–91.
8. Wu YL, Piao DM, Han, XH, Nan, JX. Protective effects of salidroside against acetaminophen-induced toxicity in mice. *Biol Pharm Bull*, 2008; 31(8):1523–1529.
9. Choi JH, Choi CY, Lee KJ, Hwang YP, Chung YC, Jeong HG. Hepatoprotective effects of an anthocyanin fraction from purple-fleshed sweet potato against acetaminophen-induced liver damage in mice. *J Med Fd*, 2009; 12(2): 320–326.

10. Wall ME, Eddy CR, McClenna ML Klump ME. Detection and estimation of steroid and saponins in plant tissue. *Anal Chem*, 1952; 24:1337-1342.
11. Harborne J B *Phytochemical methods*. 2nd edition:1984; Chapman and Hall.
12. Sofowora A. *Medicinal Plants and Traditional Medicines in Africa*. New York Chichester John, Willey & Sons: 1993 , p 256.
13. Snedecor GW, Cochran WC. *Statistical Methods*, 8th Edn, Iowa State University Press :1989, Ames, Iowa.
14. Negi AS, Kumar JK, Luqman S, Shanker K, Gupta MM, Khanuja SP. Recent advances in plant hepatoprotectives: a chemical and biological profile of some important leads. *Med. Res. Rev* 2007; 28:746-72.
15. Vermeulen NP, Bessems JGM, Vande Streat R. Molecular aspects of paracetamol-induced hepatotoxicity and its mechanism based prevention. *Drug Metab Rev*. 1992; 24:367-407.
16. Savides M C, Oehme FW. Acetaminophen and its toxicity. *J App. Toxicol*. 1983; 3:95-111.
17. Mitchell JR, Jollow DJ, Potter WZ, Gillette JR, Brodie BB. Acetaminophen-induced hepatic necrosis. IV. Protective role of glutathione. *J Pharmacol Exp Ther*. 1973; 187:211-217.
18. Grypioti AD. Liver Oxidant Stress Induced By Paracetamol Overdose. *The Inter J Pharmaco*. 2005; 4(2).
19. Pauli-Magnus C, Stieger B, Meier Y, Kullak-Ublick GA, Meier PJ. Enterohepatic transport of bile salts and genetics of cholestasis. *J. Hepatol*. 2005; 43(2): 342-357.
20. Sallie R, Tredger JM, Williams R. *Drugs and the liver*. Part 1: Testing liver function. *Biopharm. Drug Dispos*. 1991; 12 :251-9.
21. Williamson EM, Okpako DT, Evans FJ. *Selection, preparation and pharmacological evaluation of plant material*, John Wiley, England, 1996; p. 13.
22. Moss DW, Butterworth PJ. *Enzymology and Medicine*. Pitman Medical, London. :1974, p.139.
23. Wolf A, Diez-Fernandez C, Trendelenburg CF, Prieto P, Hany S, Trammer WE. Paracetamol induced oxidative stress in rat hepatocytes. *J. Pharm Exp Ther*. 1997; 280:1328-1334.
24. Thabrew M, Joice PA. A comparative study of the efficacy of *Pavetta indica* and *Osbeckia octanda* in the treatment of liver dysfunction. *Planta Med*, 1987; 53(3):239-241.

25. Zaher H, Buters JT, Ward JM, Bruno MK, Lucas AM, Stern ST, Cohen SD, Gonzalez FJ. Protection against acetaminophen toxicity in CYP1A2 and CYP2E1 double-null mice. *Toxicol Appl Pharmacol.* 1998; 152(1):193-9.
26. Godwin, A. and Mercer, A. (1973). Plant Phenolics. In: *Introduction to Biochemistry*, 2nd Ed. pp. 528-560.
27. Scevola D, Barbarini G, Grosso A, Bona S, Perissoud D. Flavonoids and hepatic cyclic monophosphates in liver injury. *Boll Ist Sieroter Milan.* 1984; 63:77-82.
28. Wegener T, Fintelmann V. Flavonoids and Bioactivity. *Wein Med. Wochem. Schr.* 1999; 149: 241-247.