



PERIPHERAL RETINAL NERVE FIBRE LAYER (RNFL) THICKNESS AND ITS CORRELATION WITH HIGH MYOPIA: A NOVEL EXCLUSIVE NORMOGRAM

Abdul Waris*, Adil Asghar, Mousami Malakar, Humayun Asharf, Syed Nasir Askari,
Anupam Ahuja and Syed Mobashir Yunus

Dept of Ophthalmology, JN Medical College, Aligarh.

Article Received on 06/04/2015

Article Revised on 02/05/2015

Article Accepted on 26/05/2015

*Correspondence for
Author

Dr Abdul Waris

Dept of Ophthalmology, JN
Medical College, Aligarh.

ABSTRACT

Purpose: To evaluate the association of high myopia with retinal nerve fibre layer (RNFL) thickness specially in the peripheral retina after ruling out other causes of RNFL thinning. **METHODS:** Fifty highly myopic eyes and forty emmetropic eyes of patients was selected after excluding concomitant ophthalmic disorder and RNFL thickness

measured using the Fourier domain optical coherence tomography (FD OCT). **RESULTS:** The overall mean RNFL thickness in the myopic groups and control were 87.89 μm and 111.64 μm respectively. The mean retinal nerve fibre thickness was significantly less in myopic eyes as compared to control group ($p = 0.0000$). Mean loss of retinal thickness at periphery was $21.22 \pm 9.27\%$ and it strongly correlated with spherical error ($r^2 = 0.20$). **CONCLUSIONS:** Retinal nerve fibre thickness was significantly decreased in myopic eyes as compared to emmetropic eyes. The peripheral retinal & RNFL of periphery are more stretched and affected in high myopia. Hence, if we focus on the RNFL of periphery after ruling out other disorder specially open angle glaucoma we get an exclusive correlation of RNFL thickness and high myopia which avoid wrong interpretation.

KEYWORDS: RNFL (retinal nerve fibre layer), OCT (optical coherence tomography), Myopia, Normogram.

Thinning of peripheral retinal nerve fibre layer correlates with high myopia: Optical Coherence Tomography assisted

INTRODUCTION

Myopia has a high prevalence in the human population, with some degree of myopia present in 20–42% of individuals worldwide and with a higher prevalence of 60–80% reported in South East Asian populations and 34.6% in Indian urban population.^[1-4] Low to moderate degrees of myopia represent a relatively minor inconvenience in the developed world, as blurred distance vision can be corrected using spectacles, contact lenses or refractive surgery. High degrees of myopia, typically classed as in excess of 6 dioptres (D), while also correctable using the above measures, are of major concern due to the incidence of myopia related pathology, since the risks of retinal atrophy, chorioretinal degeneration and retinal detachment are significantly increased.^[5-8] Up to 70% of myopes over 6 D are reported to have sight threatening ocular pathology.^[9, 10]

High myopia is invariably due to excessive elongation of the eye. High myopes are at greater risk of developing sight threatening pathology of the retina and choroid, primarily due to the increased mechanical stresses placed on these tissues in elongated eyes.^[11] Clinical reports of chorioretinal atrophy in the fundus of eyes with high myopia and histological studies indicate that myopia is associated with thinning of the retina.^[12, 13] Additionally, *in vivo* measurements of retinal thickness in human high myopia with optical coherence tomography (OCT) and the retinal thickness analyzer (RTA) have identified retinal thinning at the periphery of retina.^[14-25]

Since its introduction in 1991 by Huang *et al* the optical coherence tomography (OCT) has become one of the most widely used equipment for assessing the fovea and peripapillary nerve fibre layer in diseases like macular edema, central serous retinopathy, clinically significant macular edema (CSME) in diabetes, wet age related macular degeneration, traumatic macular involvement, macular and non macular retinoschisis, retinal detachment, optic atrophy and chronic glaucomas.^[15] The optical coherence tomography is a non invasive imaging technology, which needs no direct contact with the eye. It is analogous to the B-scan of the ultrasonograph, using light beams instead of sound waves. Time differences in reflected light from each part of the tissue are measured using optical interferometry. The high myopia and concomitant glaucoma is associated with retinal changes which were

extensively studied. Retinal changes in isolated high myopia is still unclear and this emphasize us to detect changes in the RNFL accurately even in early stage.

The aim of the present study is to quantify changes in retinal thickness and produce normative data of myopes with respect to thickness of nerve fibre layer, so as to interpret and distinguish the physiological changes of myopia from accompanying diseases in such individuals. The percentage of retinal thinning in axial high myopia is determined by OCT.

MATERIALS AND METHODS

After obtaining clearance from Institutional ethics committee, the present study was carried out randomly selected subjects from the outpatient department of eye and Retina Clinic, Institute of Ophthalmology on the basis of routine ophthalmic examination. An informed consent was taken from each subject. Subjects were matched for age and sex. Using the Snellen chart, vision was measured. The same experimenter measured the intraocular pressure three times in each eye with the Goldmann tonometer. The refractive error from the manifest refraction (MR) was adjusted to the spherical equivalent. The visual field was measured using the Humphrey field analyzer (HFA 750i, Carl Zeiss Meditec), with the central 30-2 SITA-standard program. Every patient was instilled with a drop of 1% tropicamide and 2.5% phenylephrine hydrochloride in each eye 3 times at 15 minute intervals to dilate the pupil. A fundus examination was precisely performed in all subjects.

Subjects were divided into two groups: Group I- patients with both high myopic (≥ 6 D) eyes and Group II- subjects with both emmetropic eyes. For Group I, inclusion criteria were: Patients with myopia of ≥ 6 D, Emmetropic subjects, Intraocular pressure < 21 mm Hg OU, No glaucomatous changes such as disc haemorrhages and glaucomatous cupping, media opacities, astigmatism up to 2D. Exclusion criteria were: glaucoma, refractive surgery, neurological disease, diabetes mellitus, hypertension and any other systemic illness. For Group II inclusion criteria were BCVA Of 6/6 or 20/20, Intraocular pressure < 21 mm Hg and exclusion criteria were Ocular surgery and apparent pathologies.

Total 50 high myopic eyes and 40 emmetropic eyes were considered. Following pupillary dilation at least 5mm with 0.5% cyclopentolate solution, Fourier domain optical coherence tomography (fast thickness scan) was used to examine the eyes. Three circular scans were obtained at the peripapillary retina at a default radius of 1.74 mm from the center of the optic disc, and the measurements were averaged to provide the average peripapillary RNFL

thickness. In addition, the peripapillary scan was divided into four equal 90 degree quadrants (superior, inferior, temporal, nasal) and RNFL thickness measurements in these four quadrants were also provided. In case of astigmatism upto 2 D was included and its spherical equivalent added before OCT.

Analysis of the collected data was done using SPSS version 20. Significance of difference of RNFL between myopic (group I) and emmetropic (group II) were determined by using unpaired t-test and quadrant comparison by paired t-test. P value ≤ 0.05 was considered statistically significant.

RESULTS

In the present study, 50 eyes of myopic and 40 eyes of emmetropic subjects were enrolled. In both groups age of subjects varied from 11 to 40 years. The mean spherical equivalent (SE) of refractive errors of myopes (Group I) was -10.13 ± 03.01 D and range -6 to -18 D.

In our study, overall mean RNFL thickness in study group (Group I) was $87.89 \mu\text{m}$ and in control group (Group II) was $111.64 \mu\text{m}$. (**Table 1**) The mean retinal nerve fibre thickness was significantly less in myopic eyes (group I) as compared to control group (group II) ($p=0.000$). In all the quadrants Retinal nerve fibre thickness was significantly decreased in myopic eyes (Group I) as compared to emmetropic eyes (group II). (**Table 1**) The mean loss of RNFL thickness is 21.22 ± 9.27 % (9.02-32) at periphery. The high myopia is strongly correlated with loss of RNFL thickness ($r=0.46$). The relation is linear having regression formula is % loss of RNFL thickness = $1.365 \times \text{spherical error} - 6.91$ with correlation coefficient $r^2=0.2075$. (**Graph-I**) The Loss of RNFL thickness at Parafovea is 14.42 ± 9.03 %. Again this is moderately correlated with spherical error ($r=0.21$) and regression formula is Loss of RNFL thickness = $0.62 \times \text{spherical error} + 0.66$ and $r^2=0.043$. (**Graph-II**) Loss of RNFL thickness is negligible at fovea and perifovea position rather these were thick than normal. The nasal retina underwent greater thinning than the temporal retina ($p = 0.005$; paired t-test).

Legends

Table 1: Retinal nerve fibre thickness in Group I (Myopia) and Group II (Emmetropia)

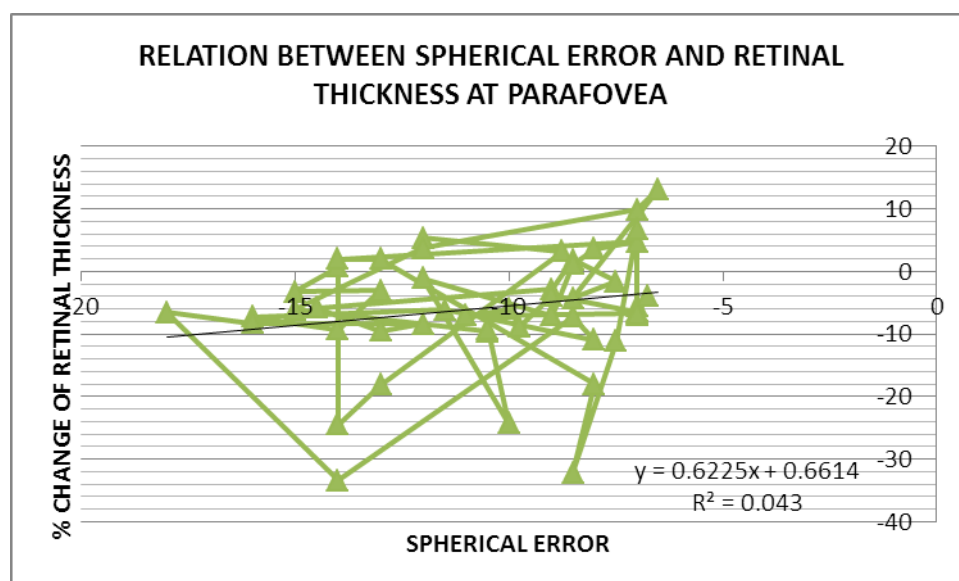
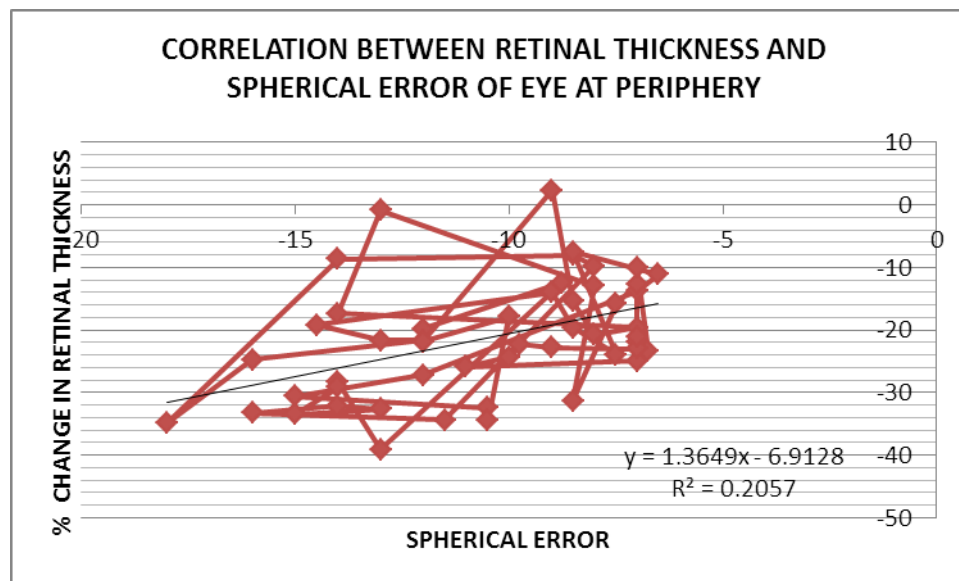
Graph I: Correlation between Retinal Thickness and Spherical Error of Eye at Periphery

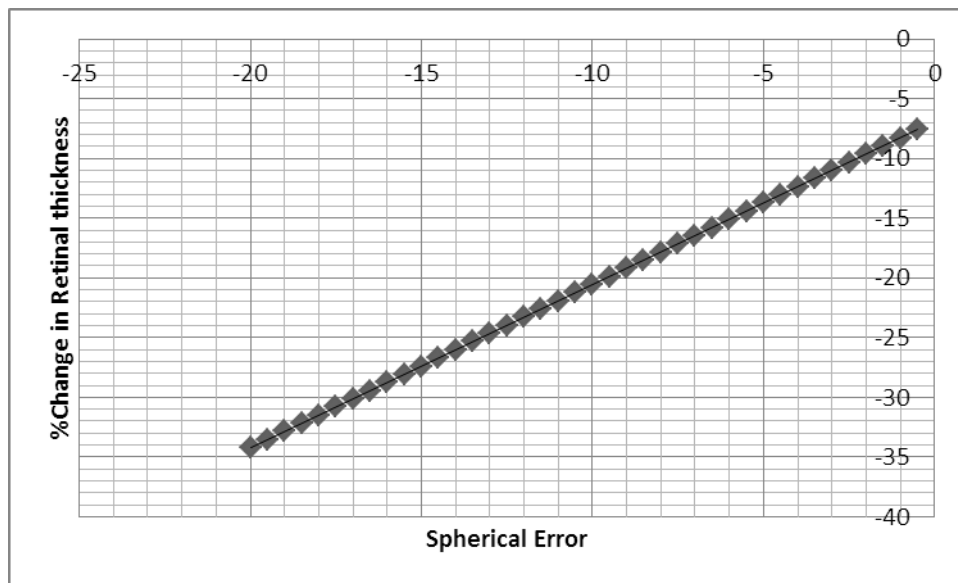
Graph II: Relation between Spherical Error And Retinal Thickness at Parafovea

Graph III: Normogram of Percentage Loss of Peripheral Retinal Nerve Fiber Layer Thickness versus Spherical Error (Myopia)

Table 1: Retinal nerve fibre thickness in Group I (Myopia) and Group II (Emmetropia)

RNFL Thickness	Group I Mean±SD (µm)	Group II Mean±SD (µm)	95% CI (µm)	P value
Average	87.89±10.37	111.64±12.6	-28.59 to -18.91	= 0.0000...
Temporal	70.06±14.13	81.30 ±10.51	-16.57 to -05.90	=0.000068
Superior	109.47±19.83	137 ±23.64	-36.63 to -18.42	=0.0000...
Nasal	67.06±17.37	86.80 ±14.95	-26.63 to -12.85	=0.0000...
Inferior	104.74±14.05	141.5±19.63	-43.81 to -29.68	=0.0000...





Graph: III

DISCUSSION

Average RNFL thickness in myopia is debatable. Hoh et al. reported no correlation between these parameters, whereas many other researchers reported that the average RNFL thickness decreased with myopia and with an increase in the axial length. Retinal thinning in myopia has been demonstrated with OCT analysis in human studies and also with histology analysis in various species.^[18-25, 26]

Kang et al., reported that the mean of average peripapillary RNFL thickness of the myopic subject was $98.247 \pm 8.586 \mu\text{m}$. Linear regression analysis revealed that the average peripapillary RNFL thickness correlated significantly with the SE and the axial length ($P < 0.001$). The regression coefficients determined by linear regression analysis for the SE was $1.310 \mu\text{m/D}$ ($R^2 = 0.123$ $P < 0.01$).^[27] Leung et al., (2012) measured the mean RNFL thickness in 189 healthy myope was $90.46 \pm 7.19 \mu\text{m}$ and significantly correlated with spherical error having regression coefficient 2.60, intercept 135.12 and $r^2=0.1$ $p<0.001$ for RNFL distribution angle.^[18] Choi et al. reported the mean RNFL thickness in high myopia is $100.74 \pm 9.15 \mu\text{m}$ and strongly correlated with spherical error ($y=2.122X+113.214$, $r^2=0.1925$, $p<0.001$).^[17] Kremser et al. studies on 129 myopic eye and found significant reduction in retinal thickness and well correlated with spherical error ($y=4.8318x+234.21$, $r^2=0.2064$, $p<0.001$).^[16] Abbott et. al. documented in their study on animal (tree shrew) that retina from myopic eyes (mean -15.9 D) showed comparable mean thinning of $15 \pm 5\%$ ($32 \mu\text{m}$) with the OCT method and $17 \pm 3\%$ ($24 \mu\text{m}$) with the histology method in the superior nasal quadrant.

The absolute values of retinal thickness measured by the histological method are smaller than the values measured by OCT, due to shrinkage during dehydration.^[26] The similarity between the results from OCT and histology methods validates OCT as a useful tool for in vivo measuring and monitoring of retinal thickness changes in myopia. Our finding is almost similar with above literatures. In high myopic subjects, mean retinal thickness was 87.89 μ m and mean thinning of RNFL is 21.22 \pm 9.27 % at periphery and 14.42 \pm 9.03 % at parafovea. The relation is linear having regression formula is % loss of RNFL thickness= 1.365X spherical error-6.91 with correlation coefficient $r^2=0.2075$. **(Graph-III)** The high myopia is strongly correlated with loss of RNFL thickness ($r=0.46$). These finding corroborate with above findings.

High myopia leads to around 30% of loss of retinal thickness at periphery. Loss of more than 30% of retinal thickness needs to exclude other associated pathology like glaucoma. Because high myopia leads to both symmetrical thinning and elongation of globe so, normative data based on regression formula can be generated to assess loss of retinal thickness. The retinal nerve fibre layer thinning in high myopes may be confused with open angle glaucoma, a disease also highly prevalent in high myopia. So, normative data will help to scrutinize with reference of spherical error to avoid wrong interpretation. But due to small sample size and inadequate comparison, there is scope of further study on larger sample size among three groups: High myopia, open angle glaucoma and high myopia with open angle glaucoma.

REFERENCES

1. Fledelius HC. Myopia prevalence in Scandinavia. A survey with emphasis on factors of relevance for epidemiological refraction studies in general. *Acta Ophthalmologica Supplementum.*, 1988; 185:44–50.
2. Goh, WS, Lam CS. Changes in refractive trends and optical components of Hong Kong Chinese aged 19–39 years. *Ophthalmic and Physiological Optics.* 1994; 14(4):378–382.
3. Lin LL, Shih YF, Tsai CB, Chen CJ, Lee L A. Hung, P T, et al.: Epidemiologic study of ocular refraction among schoolchildren in Taiwan in 1995. *Optometry and Vision Science.*, 1999; 76(5):275–281.
4. Saxena R, Vashist P, Menon V. Is myopia a public health problem in India. *Indian J Community Med.*, 2013; 38(2): 83-85.
5. Curtin BJ, Karlin DB. Axial length measurements and fundus changes of the myopic eye. *American Journal of Ophthalmology.*, 1971; 71(1): 42–53.

6. Kempen JH., Mitchell P, Lee KE, Tielsch, JM., Broman AT, Taylor HR. et al. The prevalence of refractive errors among adults in the United States, Western Europe, and Australia. *Archives of Ophthalmology.*, 2004; 122(4): 495–505.
7. Celorio, JM., Pruett RC. Prevalence of lattice degeneration and its relation to axial length in severe myopia. *American Journal of Ophthalmology.*, 1991; 111(1): 20–23.
8. Yannuzzi LA, Sorenson JA. Risk factors for idiopathic rhegmatogenous retinal detachment. The Eye Disease Case-Control Study Group. *American Journal of Epidemiology.*, 1993; 137(7): 749–757.
9. Chiang, L. M., Ho TC, Lin L L, Yang C M, Liu KR. Chen, M. S.: Prevalence of retinal detachment and peripheral retinal degeneration in high myopia college students in Taiwan. *Investigative Ophthalmology and Visual Science.*, 1993; 34: 937.
10. Grossniklaus HE, Green WR. Pathologic findings in pathologic myopia. *Retina.* 1992; 12(2): 127–133.
11. David T, Smye S, Dabbs T, James T. A model for the fluid motion of vitreous humour of the human eye during saccadic movement. *Physics in Medicine and Biology.*, 1998; 43(6): 1385–1399.
12. McBrien NA, Moghaddam HO, Cottrill C., Leech EM., Cornell LM. The effects of blockade of retinal cell action potentials on ocular growth, emmetropization and form deprivation myopia in young chicks. *Vision Research.*, 1995; 35(9): 1141–1152.
13. Yanoff, M., & Fine, B. S. *Ocular pathology* (5th ed.), 2002 St. Louis: Mosby.
14. Hee, MR., Izatt, JA, Swanson EA, Huang D, Schuman JS, Lin CP. Optical coherence tomography of the human retina. *Archives of Ophthalmology.*, 1995; 113(3): 325–332.
15. Huang D, Swanson, EA. Optical coherence tomography. *Science.*, 1991; 254(5035): 1178–1181.
16. Kremser B, Troger J, Baltaci M, Kralinger M, Kieselbach GF. Retinal Thickness Analysis in Subjects with Different Refractive Conditions *Ophthalmologica.*, 1999; 213: 376–379.
17. Choi S, Lee S. Thickness changes in the fovea and peripapillary retinal nerve fiber layer depend on the degree of myopia. *Korean J Ophthalmol.*, 2006; 20: 215–219.
18. Leung CK, Yu M, Weinren RN, Mak HK, Lai G, Ye C, Lam DS; Retinal Nerve Fiber Layer Imaging with Spectral-Domain Optical Coherence Tomography: Interpreting the RNFL Maps in Healthy Myopic Eyes. *Invest Ophthalmol Vis Sci.*, 2012; 53: 7194–7200.
19. Lim MC, Hoh ST, Foster PJ, Lim TH, Chew SJ, Seah SK, Aung T. Use of optical coherence tomography to assess variations in macular retinal thickness in myopia. *Invest Ophthalmol Vis Sci.*, 2005; 46: 974–978.

20. Leung CK, Mohamed S, Leung KS, Cheung CY, Chan SL, Cheng DK et al. Retinal nerve fiber layer measurements in myopia: an optical coherence tomography study. *Invest Ophthalmol Vis Sci.*, 2006; 47: 5171–5176.
21. Hoh ST, Lim MC, Seah SK, Lim AT, Chew SJ, Foster PJ, Aung T. Peripapillary retinal nerve fiber layer thickness variations with myopia. *Ophthalmology.*, 2006; 113: 773–777.
22. Liew SH, Gilbert CE, Spector TD, Marshall J, Hammond CJ. The role of heredity in determining central retinal thickness. *British Journal of Ophthalmology.*, 2007; 91(9): 1143–1147.
23. Luo HD, Gazzard G. Myopia, axial length, and OCT characteristics of the macula in Singaporean children. *Investigative Ophthalmology and Visual Science.*, 2006; 47(7): 2773–2781.
24. Wolsley CJ, Saunders KJ, Silvestri G, Anderson RS. Investigation of changes in the myopic retina using multifocal electroretinograms, optical coherence tomography and peripheral resolution acuity. *Vision Research.*, 2008; 48(14): 1554–1561.
25. Lam DS, Leung KS, Mohamed S, Chan WM, Palanivelu MS, Cheung C. Regional variations in the relationship between macular thickness measurements and myopia. *Investigative Ophthalmology and Visual Science.*, 2007; 48(1): 376–382.
26. Abbott CJ, Grünert U, Pianta MJ, McBrien NA. Retinal thinning in tree shrews with induced high myopia: Optical coherence tomography and histological assessment. *Vision Research.*, 2011; 51: 376–385
27. Kang SH, Hong SW, Im, SK, Lee SH, Ahn MD. Effect of Myopia on the Thickness of the Retinal Nerve Fiber Layer Measured by Cirrus HD Optical Coherence Tomography. *IOVS.*, 2010; 51(8): 4075-4093.