



**HEPATOPROTECTIVE AND ANTIOXIDANT EFFECT OF
ETHANOLIC AND PURIFIED FLAVONOID EXTRACTED FROM *C.
ROTUNDUS* AGAINST CARBON TETRACHLORIDE INDUCED
LIVER DAMAGE IN MICE (*IN VIVO*)**

Essam F. Al-Jumaily* and Jameelah K.T. Al-Isawi

*Biotechnology Dept, Genetic Engineering and Biotechnology Institute for Post Graduate
Studies. Baghdad University, Baghdad / Iraq.

Chemistry Dept, College of Education for Pure Science- Ibn-Al-Haithem / Baghdad
University, Baghdad, Iraq.

Article Received on 24/07/2015

Article Revised on 16/08/2015

Article Accepted on 08/09/2015

***Correspondence for**

Author

Dr. Essam F. Al-Jumaily

Biotechnology Dept,
Genetic Engineering and
Biotechnology Institute for
Post Graduate Studies.
Baghdad University,
Baghdad / Iraq.

ABSTRACT

In this study an interaction was carried out between one dose of CCl_4 (3.2 mg/Kg) and the two doses (150 and 300 mg/kg) of ethanolic and purified flavonoid extract *C. rotundus* and one dose of vitamin C (180 mg/kg) were evaluated in mice (*in vivo*) given injection for 14 days inducing biochemical function of three antioxidant enzymes (Catalase, Superoxide dismutase and Glutathione) in liver homogenate, liver function enzymes and histopathological changes of liver. The results showed that the antioxidants glutathione (GSH) and Superoxide

dismutase (SOD) and catalase (CAT) has increased significantly ($P < 0.05$) after the animals has been injection mice CCl_4 , and that each of the purified flavonoids and ethanolic extract at a concentration (150 and 300 mg / kg) has led to decreased Glutathione enzyme (GSH) activity significantly ($P < 0.05$) in compared to the ct. The ethanolic extract for *C. rotundus* concentration of 150 mg / kg and vitamin C concentration of 180 mg / kg has increased significantly ($P < 0.05$) when compared with the treatment of control group. Either Superoxide dismutase (SOD) has led purified flavonoids from *C. rotundus* (150 and 300 mg / kg) to increase significantly at ($P < 0.05$) level compared to the treatment of tetrachloride carbon an which the enzyme declines significantly at ($P < 0.05$) level, when injection them for 14 days. Either enzyme catalase (CAT) has led purified flavonoids extract and ethanolic

extract of *C. rotundus* (150 and 300 mg / kg) to decrease significantly ($P < 0.05$) compared to treatment tetrachloride carbon. Examination of liver tissue confirmed potential histopathological treatment with CCl_4 and purified flavonoid extract shows necrosis of hepatocyte cells with inflammatory cells infiltration. Furthermore, the liver of animal that treatment with CCl_4 and ethanolic extract shows depletion of glycoprotein granules with dispersed necrosis of hepatocyte cells.

KEYWORDS: ethanolic, *rotundus*, histopathological, ethanolic.

INTRODUCTION

Cyperus rotundus rhizome is one of the worst weed plants in the world, although *Cyperus rotundus* causes serious problems in more crops in more countries than any other weed.^[1] In Asian countries, *Cyperus rotundus* (Cyperaceae) is a traditional herbal medicine used the treatment of stomach and bowel disorders, and inflammatory diseases, analgesic, stomach disorders and to relieve diarrhea.^[2] However, the antioxidant activity of phenolic compounds depends largely on the chemical structure of these substance.^[3] Among the phenolic compounds with known antioxidant activity, flavonoids, tannins chalcones and coumarins as well as phenolic acid are highlighted. Compounds such as carotene, ascorbic acid have demonstrated to have antioxidant and synergistic activity in despite of their non-phenolic structure.^[4] Health benefits of vitamin C are antioxidant, anti-atherogenic, anti-carcinogenic, immunomodulation. The positive effect of vitamin C resides in reducing the incidence of stomach cancer, and in preventing lung and colorectal cancer. Vitamin C works synergistically with vitamin E to quench free radicals and also regenerates the reduced form of vitamin E. However, the intake of high doses of vitamin C (2000 mg or more /day) has been the subject of debate for its eventual pro-carcinogenic property.^[5,6]

The present study focused on evaluating the antioxidant activity of flavonoid purified and ethanolic extract on mice compared to that caused by carbon tetrachloride as a hepatotoxic model.

MATERIALS AND METHODS

Collection samples of plant

Firstly obtained on the tubers of *C. rotundus* Rhizomes from local Baghdad market and farms Basrah has been diagnosed by the College of Science / Baghdad University. Cleaned it after that broke and grinded it by using Electric grinder. The extract has been prepared according

to the method used by Ozaki *et al.*,^[7] with some modification by Al-Jumaily and Al-Isawi,^[8]. In this method used powder tubers of the rhizomes of *C. rotundus* which extracted using petroleum ether solvent in the flask of extraction and the extraction conducted by using Soxhlet extractor at the temperature 50°C for 6 hours. After that took the second material after removing the oily material from it and stock in the second solvent 70% ethanol and left it at room temperature for 48 hours, the solution have been filtered and evaporated to dryness under vacuum at 40°C., the dried extract (which called ethanol extracted) and stored at 4 °C.

The flavonoid purified extract was prepared by using Sephadex LH-20 gel according to Al-Jumaily *et al.*^[9] the flavonoid compound was separated from ethanol extracted had been preceded using glass column (1.75 x 49) cm . Five ml of ethanol extracted of the rhizoms of *Cyperus rotunds* was subjected to column and eluted with ethanol solution, and the flow rate regulated to be 60 ml/min. The elusions had been collected and tested by ferric chloride solution 1%. Fractions containing flavonoid compound were pooled and concentrated to the required volume. (which called flavonoids extracted)

Forty –five mice (25-30 gm) of about six weeks old were obtained from the national center for drug control and research and Infertility Treatment / Al-Nahrain University and bred in the animal house of Biotechnology Researches Center / Al-Nahrain University were used in this study. They were randomly selected and kept in nine groups of 5 mice per group. Each group was kept in a separate cage. All animals were fed with commercially formulated mice feed and tap water *ad libitum* that supplied by the center. Their cages were cleaned daily; food and water have been changed daily. The animals were allowed to acclimatize for 2 weeks.

Treatment schedule of animals

Forty-five mice have been used to study the possible antioxidant effect of different injection of flavonoid purified extract and ethanolic extract compared to CCl₄-induced liver and blood damage allocated,^[10] as follows:

Group One

five mice treated with daily oral injection diet and drank tap water for 14 days. The animals were killed by anesthetic ether on the day 15. The group served as control.

Group Two

five mice treated this group carbon tetrachloride (3.2 mg / kg) the first day and the eighth. The animals were killed by anesthetic ether on the day 15 The group served as positive control.

Group Three

five mice had been treated with oral daily injection of flavonoid purified extract 150mg/kg/day for 14 day and treated with CCl₄ first and eight day ; the animals were killed by anesthetic ether on the day 15.

Group Four

five mice had been treated with oral daily injection of flavonoid purified extract 300mg/kg/day for 14 day and treated with CCl₄ first and eight day ; the animals were killed by anesthetic ether on the day 15.

Group Five

five mice had been treated with oral daily injection of ethanolic extract 150mg/kg/day for 14 day and treated with CCl₄ first and eight day ; the animals were killed by anesthetic ether on the day 15

Group Six

five mice had been treated with oral daily injection of ethanolic extract 300mg/kg/day for 14 day and treated with CCl₄ first and eight day ; the animals were killed by anesthetic ether on the day 15.

Group Seven

five mice had been treated with oral daily injection of with vitamin C 180mg/Kg/day for 14 day and treated with CCl₄ first and eight day; the animals were killed by anesthetic ether on the day 15.

Group Eight

five mice had been treated with oral daily injection of flavonoid purified extract 300mg/kg/day for 14 day; the animals were killed by anesthetic ether on the day 15.

Group Nine

five mice had been treated with oral daily injection of ethanolic extract 300mg/kg/day for 14 day; the animals were killed by anesthetic ether on the day 15.

Samples collection from the tissue homogenate

After sacrifice the animals by anesthetic ether, Prior to dissection either perfused or rinse tissue with a PBS (phosphate buffer saline) solution, pH 7.4, to remove any red blood cells and clots homogenize the tissue in 5 ml of cold buffer (50 mM MES or phosphate , pH 6-7, containing 1mM EDTA) per gram tissue centrifuge at 10,000^x g for 15minutes at 4C° remove the supernatant and store on ice the supernatant will have to be deproteinated before assaying if not assaying in the same day the sample will still have to be deproteinated and then stored at -20C° the sample will be stable for at least six months.

Estimation of glutathione (GSH)

Glutathione (GSH) was determined according to the modified by Jollow *et al.*^[11] Which depend on using {5,5dithio-bis(2-nitrobenzoic acid)}which reduced by sulfhydryl (SH-group)to yellow compound .The absorbance of the reduced chromogen was detected at absorbance=412nm and is directly proportional to the GSH concentration in serum.

Determination of Catalase

Catalase (hydrogen peroxide) is an important cellular antioxidant enzyme that defends against oxidative stress.^[12] It is found in the peroxisomes of most aerobic cells.It serves to protect the cell from toxic effect of highy nconcentrations of hydrogen peroxide (H₂O₂) by catalyzing its decom- position into molecular oxygen and water, without the production of free radicals.

Determination of superoxide dismutase (SOD)

Superoxide dismutase (EC 1.15.1.1) was determined using the method Of Crapo *et al.*^[13] using ready-made kit. Results were analyzed statistically using completely randomized design (CRD) within the Statistical Analysis System.^[14] The least significant difference- (LSD) test as used to comparatives significant between means in this study.^[15]

RESULTS AND DISCUSSION

Carbon tetrachloride –treated mice (group two) showed a significant (p<0.05) increase in the liver tissue activity level of glutathione (GSH) to (16.32 µmol/min/L) as compared to control mice (14.09 µmol/min/L).(Figure 1) and Table (1). Mice treated with 150mg/kg and 300mg/kg of purified flavonoid (with CCl₄) showed a significant (p<0.05) decrease in the liver tissue activity level of GSH to (13.25 µmol/min/L,12.7 µmol/min/L) (group three-group four) as compared to control group, but significantly (p<0.05) less than CCl₄-treated group.

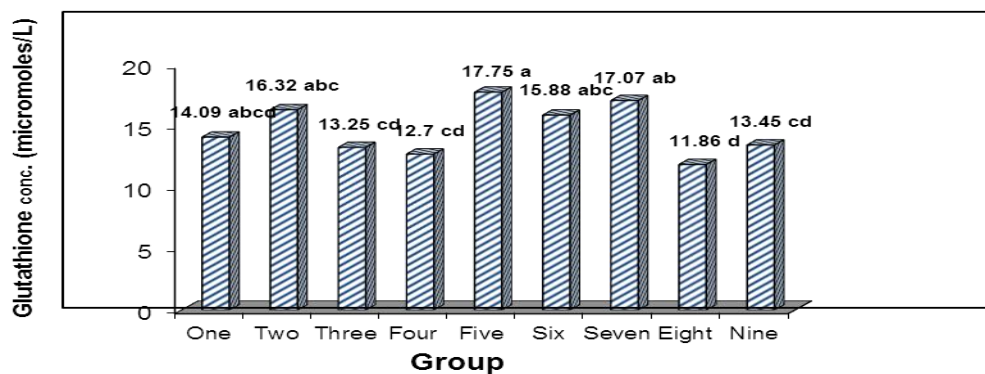


Figure 1: The effect of different dose of purified flavonoid and ethanolic extract *C. rotundus* rhizomes on the activity of serum Glutathione (GSH).

Group One – Control.

Group Two – Mice were treated with CCl₄.

Group Three – Mice were treated with purified flavonoid extract 150mg/kg + CCl₄.

Group Four – Mice were treated with purified flavonoid extract 300mg/kg + CCl₄.

Group Five – Mice were treated with ethanolic extract 150mg/kg + CCl₄.

Group Six – Mice were treated with ethanolic extract 300mg/kg + CCl₄.

Group Seven – Mice were treated with vitamin C + CCl₄.

Group Eight – Mice were treated with purified flavonoid extract 300mg/kg.

Group Nine – Mice were treated with ethanolic extract 300mg/kg

Mice treated with 150mg/kg of ethanolic extract (with CCl₄) showed a significant increase in the liver tissue activity level of glutathione (GSH) to (17.75 μmol/min/L) (group five) at (P<0.05) level as compared to control mice (14.09 μmol/min/L) (group one), but significantly more than CCl₄-treated group at (P<0.05) level.

Mice were treated with 300 mg/kg of ethanolic extract (with CCl₄) showed a significant (p<0.05) increase in the liver tissue activity level of glutathione (GSH) to (15.88 μmol/min/L) (group six) as compared to control mice (14.09 μmol/min/L), but significantly (p<0.05) less than CCl₄-treated group. Mice treated with 180mg/kg of vitamin C (with CCl₄) showed a significant (p<0.05) increase in the liver tissue activity level of glutathione (GSH) to (17.07 μmol/min/L)(group seven) as compared to control mice (14.09 μmol/min/L), but significantly (p<0.05) more than CCl₄-treated group.

Mice were treated with 300mg/kg of purified flavonoid showed a significant (p<0.05) decrease in the liver tissue activity level of GSH to (11.86 μmol/min/L) (group eight) as compared to control group, but significantly (p<0.05) less than CCl₄-treated group.

Mice were treated with 300 mg/kg of ethanolic extract (group nine) showed a significant ($p < 0.05$) decrease in the liver tissue activity level of glutathione (GSH) to (13.45 $\mu\text{mol}/\text{min}/\text{L}$) as compared to control group (14.09 $\mu\text{mol}/\text{min}/\text{L}$) but significantly ($p < 0.05$) less than CCl_4 -treated group.

The results show that the best treatment is the purified flavonoid (with CCl_4) 150mg/kg, 300gm/kg group three and group four. Purified flavonoid were able to modulate these effects, and showed their ability in reducing the level of liver function enzymes.

Table 1: Effect of purified flavonoids and ethanolic extract *C. rotundus* rhizomes on serum GSH,SOD,and Catalase in control , CCl_4 treated mice at different concentration. (mean \pm SE)

Group	Mean \pm SE		
	Glutathione conc. (micromoles/L)	SOD- Inhibition (%)	Catalase –Activity (IU/ml)
One	14.09 \pm 1.25	42.95 \pm 0.22	10.70 \pm 0.59
Two	16.32 \pm 1.11	48.48 \pm 3.04	13.46 \pm 1.26
Three	13.25 \pm 0.98	34.84 \pm 3.89	14.35 \pm 0.83
Four	12.70 \pm 0.33	27.87 \pm 1.84	11.51 \pm 1.56
Five	17.75 \pm 2.26	83.74 \pm 3.80	11.86 \pm 0.45
Six	15.88 \pm 0.67	82.84 \pm 2.47	11.98 \pm 0.25
Seven	17.07 \pm 2.01	13.94 \pm 1.21	11.95 \pm 0.25
Eight	11.86 \pm 0.53	27.27 \pm 5.19	16.40 \pm 1.72
Nine	13.45 \pm 0.84	38.41 \pm 2.45	11.38 \pm 1.34
LSD value	3.684 *	10.310 *	3.085 *
* ($P \leq 0.05$).			

The effect of flavonoids and ethanolic extract on serum catalase (CAT)

Figure (2) and table (1) showed that the CCl_4 treated mice increase a significant ($p < 0.05$) in the liver activity level of catalase to (13.46 IU/ml) as compared to control mice (10.7 IU/ml). Mice treated with 150mg/kg of purified flavonoid (with CCl_4) showed a significant ($p < 0.05$) increase in the liver tissue activity level of catalase to (14.35 IU/ml) (group three) as compared to control group, but significantly ($p < 0.05$) more than CCl_4 -treated group. But when the mice treated with 300mg/kg of purified flavonoid and (150,300mg/kg) of ethanolic extract, 180mg/kg vitamin C (with CCl_4) showed a significant ($p < 0.05$) increase in the liver tissue activity level of catalase to (11.51, 11.86, 11.98, 11.95 IU/ml) (four, five, six and seven groups, respectively) as compared to control group, but significantly ($p < 0.05$) less than CCl_4 -treated group. Therefore, this treatment is considered the best in terms of addressing the damage caused due to CCl_4 .

Mice were treated with 300mg/kg of purified flavonoid showed a significant ($p<0.05$) increase in the liver tissue activity level of catalase to (16.4 IU/ml) (group eight) as compared to control group, but significantly more than CCl₄-treated group at ($P<0.05$) level.

Mice were treated with 300 mg/kg of ethanolic extract showed a significant ($p<0.05$) increase in the liver tissue activity level of catalase to (11.38 IU/ML)(group nine) as compared to control mice (10.7 IU/), but significantly ($p<0.05$) less than CCl₄-treated group.

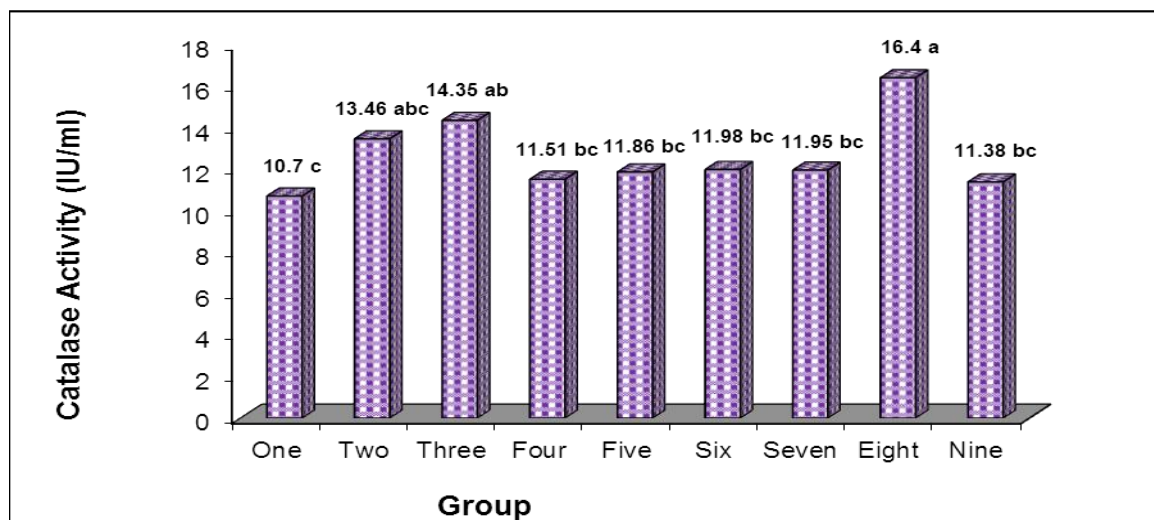


Figure 2 : The effect of different dose of purified flavonoid and ethanolic extract *C. rotundus* rhizomes on the activity of serum catalase.

Group One – Control.

Group Two – Mice were treated with CCl₄.

Group Three – Mice were treated with purified flavonoid extract 150mg/kg + CCl₄.

Group Four – Mice were treated with purified flavonoid extract 300mg/kg + CCl₄.

Group Five – Mice were treated with ethanolic extract 150mg/kg + CCl₄.

Group Six – Mice were treated with ethanolic extract 300mg/kg + CCl₄.

Group Seven – Mice were treated with vitamin C + CCl₄.

Group Eight – Mice were treated with purified flavonoid extract 300mg/kg.

Group Nine – Mice were treated with ethanolic extract 300mg/kg.

The effect of flavonoids and ethanolic extract on superoxidase dismutase (SOD)

CCl₄- treated mice (group two) showed a significant ($p<0.05$) increase in the liver tissue activity level of SOD to (48.48 unit/ml) as compared to control mice (42.95unit/ml) (figure 3 and table 1).

Figure-(3) shows a significant ($p<0.05$) decrease in the liver tissue activity level of SOD in mice treated with (150 and 300mg/kg) of purified flavonoid (with CCl_4) (three and four group) (34.84 and 27.87 unit/ml) as compared to control mice (42.95 unit/ml), but significantly ($p<0.05$) less than CCl_4 -treated group.

Mice treated with (150 and 300mg/kg) of ethanolic extract (with CCl_4) showed a significant ($p<0.05$) increase in the liver tissue activity level of SOD to (83.74 and 82.84 unit/ml) (five and six group) as compared to control mice (42.95 unit/ml) (group one), but significantly ($p<0.05$) more than CCl_4 -treated group.

Mice treated with 180mg/kg of vitamin C (with CCl_4) showed a significant ($p<0.05$) decrease in the liver tissue activity level of SOD to (13.94 unit/ml) (group seven) as compared to control mice (42.95 unit/ml) (group one), but significantly ($p<0.05$) less than CCl_4 -treated group.

Also there was a significant ($p<0.05$) decrease in the liver tissue activity level of SOD in mice treated with 300mg/kg purified flavonoid (group eight) to (27.27 unit/ml) as compared to control mice (42.95 unit/ml) (group one), but significantly ($p<0.05$) less than CCl_4 -treated group.

Mice treated with 300 mg/kg of ethanolic extract showed a significant ($p<0.05$) decrease in the liver tissue activity level of SOD to (38.41 unit/ml) (group nine) as compared to control mice (42.95 unit/ml) (group one), but significantly less than CCl_4 -treated group at ($P<0.050$)

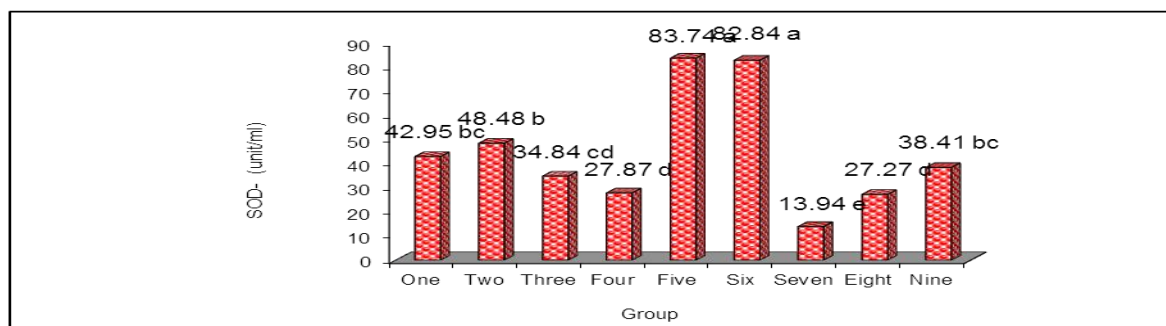


Figure 3 : The effect of different dose of purified flavonoid and ethanolic extract *C.rotundus* rhizomes on the activity of serum SOD.

Group One – Control.

Group Two – Mice were treated with CCl_4 .

Group Three – Mice were treated with purified flavonoid extract 150mg/kg + CCL₄.

Group Four – Mice were treated with purified flavonoid extract 300mg/kg + CCL₄.

Group Five – Mice were treated with ethanolic extract 150mg/kg + CCL₄.

Group Six – Mice were treated with ethanolic extract 300mg/kg + CCL₄.

Group Seven – Mice were treated with vitamin C + CCL₄.

Group Eight – Mice were treated with purified flavonoid extract 300mg/kg.

Group Nine – Mice were treated with ethanolic extract 300mg/kg.

In the present study showed a significant decrease in hepatic tissue SOD activities in mice with CCL₄-treated compared with control group (Figure 4). Szymonik-Lesiuk *et al.*^[16] reported that in the kidney of rats exposed to CCL₄, CCL₄ would reduce SOD and CAT activities and that oxidative stress in the liver was induced by CCL₄ in oxidant cause a decrease in SOD and GPx activities or that reactive intermediary product occurred during the bio-activation of CCL₄ could inactivate SOD and GPx enzymes.

The results showed that the enzyme antioxidant (SOD) has increased significantly ($P < 0.05$) in that ethanolic extract 150mg/kg, 300mg/kg with CCL₄ (five and six group) compared to the control group and after feeding for 14 days. Antioxidant enzyme activity such as SOD, CAT and GPx may sometime decrease.^[17] or increase.^[18]

In the current study the significant decrease in the antioxidant enzyme activities (CAT, SOD and GSH) in liver tissue suggested that CCL₄ induced oxidative stress this results agreement with Atessanin *et al.*^[19] who reported that administration of propolis has been shown to produce oxidative stress by generating reaction oxygen species and reducing the antioxidant.

Histological examination of the liver sections

Section of mice control group showed normal appearance of liver tissue which consist of threab of hepatocyte cell with control vein and partial tract (Figure 4).

Figure (5) shows section of mice treated with CCL₄ (first and eight day) the congestion, dispersed hepatocyte cells necrosis with mild inflammatory cells infiltration near portal area and slight necrosis with sinusoidal dilatation of sinusoids (Figure 5). Hepatocellular necrosis leads to very high level of AST and ALT.

In blood released from liver to blood. However, alanine transaminase is a better index of injury, as its activity represents 90% of total enzymes present in the body. The decrease in

serum transaminase concentration in indicates the stabilization of plasma membrane and protection of hepatocytes against the damaged caused by carbon tetrachloride.^[20]

Histopathological examination of liver section from each animal treated with CCl₄ and 150mg/kg purified flavonoid extract shows degenerative changes and necrosis of hepatocyte cells with infiltration of inflammatory cells (Figure 6). Section of mice treated with CCl₄ and 300mg/kg purified flavonoid for 14 day has showed necrosis of hepatocyte cells with inflammatory cells infiltration. (Figure 7).

While the histopathological section in the liver of animal treated with CCl₄ and 150mg/kg ethanolic extract shows depletion of glycoprotein granules with dispersed necrosis of hepatocyte cells (Figure 8). Section of mice treatment with CCl₄ and 300mg/kg ethanolic extract shows reaccumulation of glycoprotein granules inside the hepatocyte cells with slight sinusoidal dilatation (Figure 9).

Histopathological examination of liver section from each animal treated with CCl₄ and Vitamin C shows slight depletion of glycoprotein showing granules with slight sinusoidal dilatation (Figure 10).

Also in other section degenerative changes and depletion of glycoprotein granules inside the hepatocyte cells near portal area and central veins in group eight (treated by purified flavonoid extract 300mg/kg) (Figure 11).

Histopathological examination of liver section from each animal treated with 300mg/kg ethanolic extract shows dispersed necrosed hepatocyte cells with infiltration of inflammatory cells and slight widening of sinusoids (Figure 12).

C. rotundus extract is an effective free radical scavenger showing antioxidant activity against reactive oxygen production and protecting the damage caused by free radicals.^[21]

The intake of antioxidants from *C. rotundus* works to the improvement of the animals of the through presence of free radical scavenging substances such as flavonoid oil.^[22] Ahmed *et al.*^[23] reported that the effects of extract of *C. rotundus* (1000 mg/kg) in rats sample, Liver enzymes were found normal and statistically non-significant. A nonsignificant ($p < 0.05$) increase in serum bilirubin, γ -GT and SGPT was also observed with respect to its control. Extract of *C. rotundus* produced slight but non-significant decrease in the serum alkaline

phosphate (ALP) but this increase was also non significant , and the result Histopathological examination of different organs (heart, kidney, liver and spleen), were obtained histopathological examination showed normal histology and pathology in both control and treated animals.

The results obtained are very interesting as they provide evidence in favour of the protective effects of *C. rotundus*, Ascorbic acid, against carbon tetrachloride-induced hepatotoxicity in mice.

The present study an agreement with Sailor *et al.*^[24] as both reached to the results that *Leucas cephalotes* methanolic extract possesses significant hepatoprotective activity and prevent chemically (CCl₄) induced hepatic damaged in rat.

Up to the present time, the etiology and treatment of most liver diseases are not known. The liver is the commonest site affected during the toxic manifestation of many drugs.

In the present study, as *C. rotundus* was used as a drug, it was proved that flavanoids were in the ethanolic extract and purified extract. *C. rotundus* protects the liver from the impact of CCl₄, which is a toxic substance that affects the liver function.^[25] The hepatotoxicity of CCl₄ has been reported to be due to the formation of the highly reactive trichloro free radical, which attacks polyunsaturated fatty acids. It produces hepatotoxicity by altering liver microsomal membranes in experimental animals.^[26]

Both trichloromethyl and its peroxy radicals are capable of binding to proteins and lipids, or of abstracting a hydrogen atom from an unsaturated lipid, initiating lipid peroxidation and liver damage and by doing so plays a significant role in pathogenesis of disease (Sampathkumar *et al.*, 2005). The results of this study demonstrated that *C. rotundus* hepatoprotective activity reduced the effect of CCl₄ on the damage of the livers of the mice.

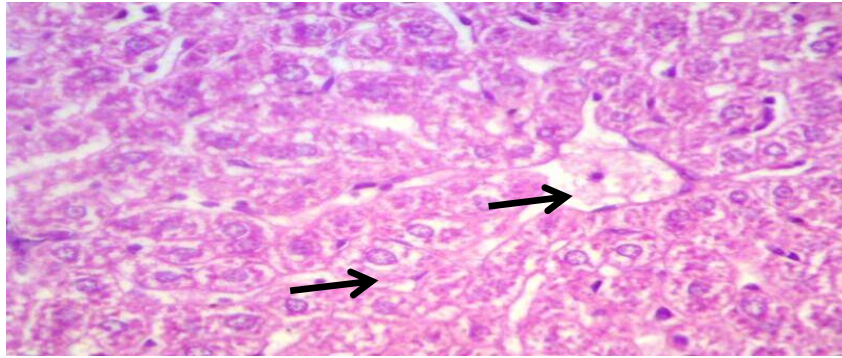


Figure (4): Histopathological section in the liver of normal animals shows look like normal appearance of liver tissue contain central vein and hepatocyte cell (black arrow). (H&E stain X200).

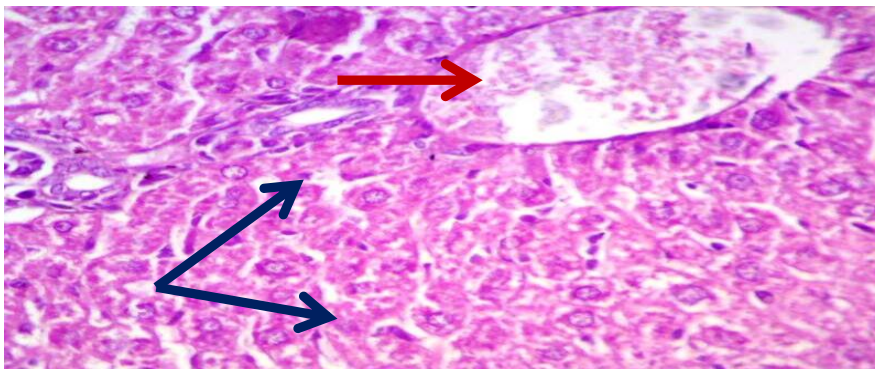


Figure (5): Histopathological section in the liver of animal at 14 days post –treatment with CCl₄ (first and eight day) shows congestion (red arrow) ,dispersed hepatocyte cells necrosis (blue arrow) with mild inflammatory cells infiltration near portal area and slight necrosis with sinusoidal dilatation of sinusoids .(H&E stain X200).

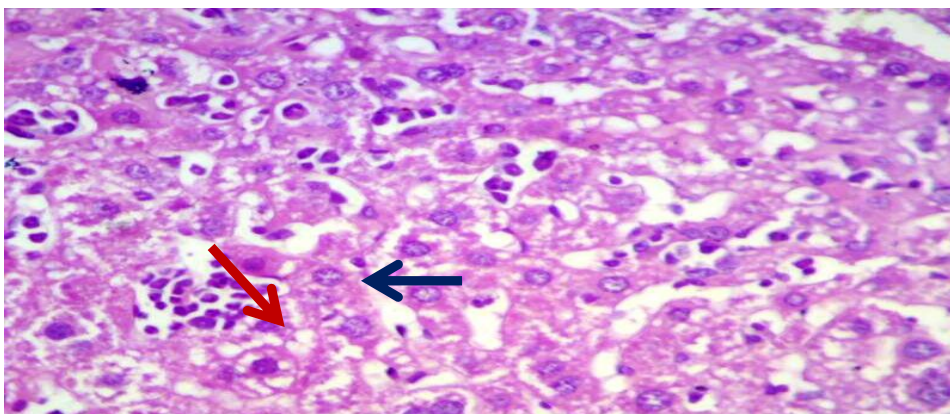


Figure (6): Histopathological section in the liver of animal at 14 days post –treatment with CCl₄ and 150mg/kg purified flavonoid extract shows degenerative changes(red arrow) and necrosis of hepatocyte cells with infiltration of inflammatory cells (blue arrow) .(H&E stain X200) .

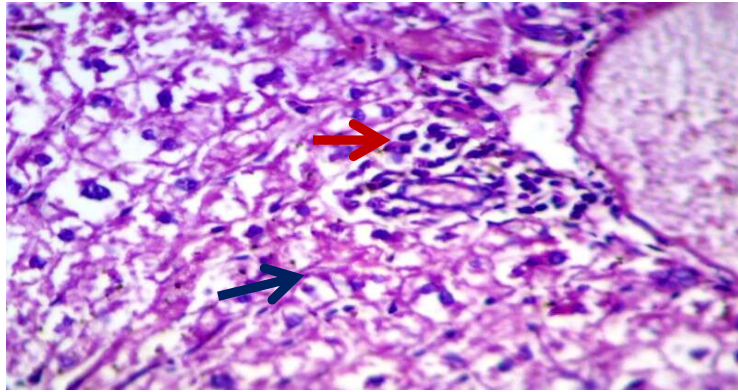


Figure (7): Histopathological section in the liver of animal at 14 days post –treatment with CCl_4 and 300mg/kg purified flavonoid extract shows necrosis of hepatocyte cells (red arrow) with inflammatory cells infiltration (bule arrow) . (H&E stain X200).

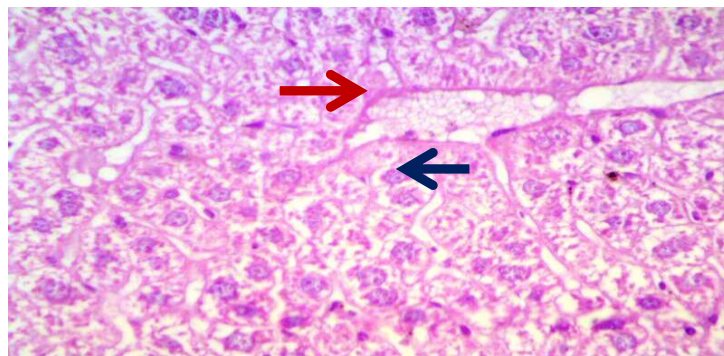


Figure (8): Histopathological section in the liver of animal at 14 days post –treatment with CCl_4 and 150mg/kg ethanolic extract shows depletion of glycoprotein granules (red arrow) with dispersed necrosis of hepatocyte cells (blue arrow). (H&E stain X200).

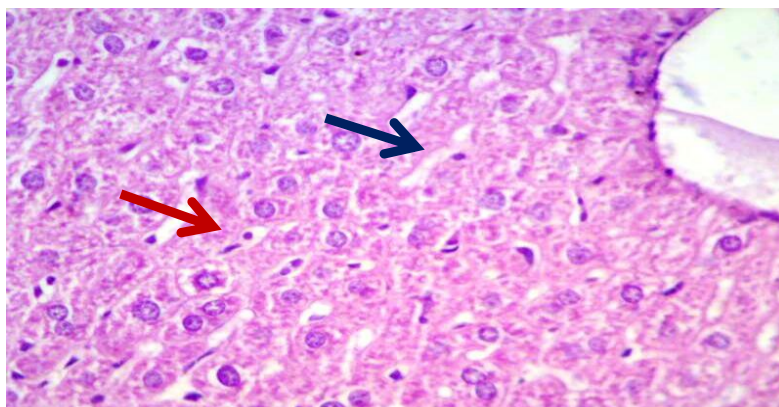


Figure (9): Histopathological section in the liver of animal at 14 days post –treatment with CCl_4 and 300mg/kg ethanolic extract shows reaccumulation of glycoprotein granules inside the hepatocyte cells (red arrow) with slight sinusoidal dilatation (blue arrow). (H&E stain X200).

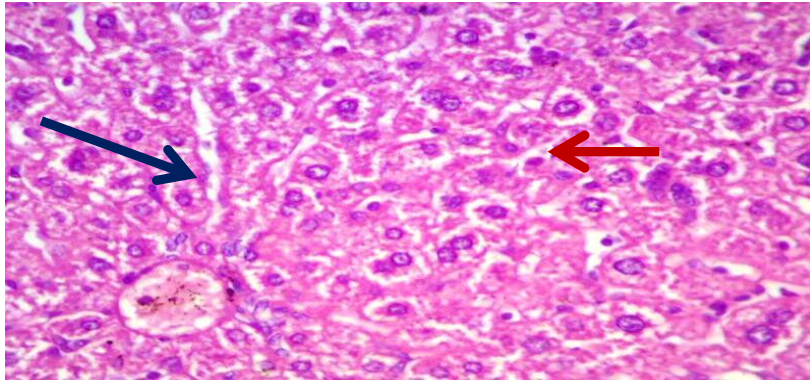


Figure (10): Histopathological section in the liver of animal at 14 days post –treatment with CCl₄ and Vitamin C shows slight depletion of glycoprotein (red arrow) showing granules with slight sinusoidal dilalation (blue arrow). (H&E stain X200).

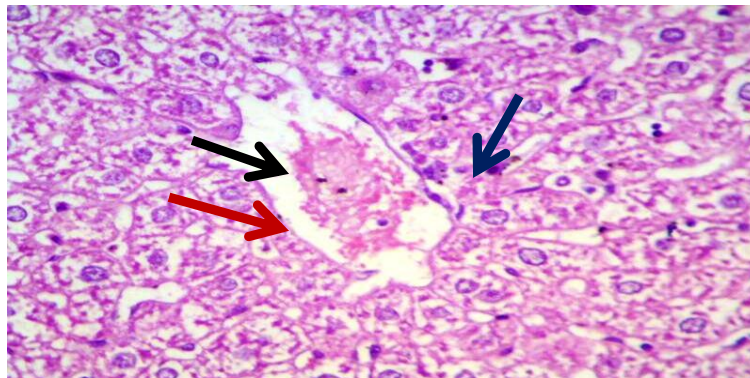


Figure (11): Histopathological section in the liver of animal at 14 days post–treatment with 300mg/kg purified flavonoid extract shows degenerative changes (red arrow) and depletion of glycoprotein granules inside the hepatocyte cells near portal area (blue arrow) and central veins (black arrow). (H&E stain X200).

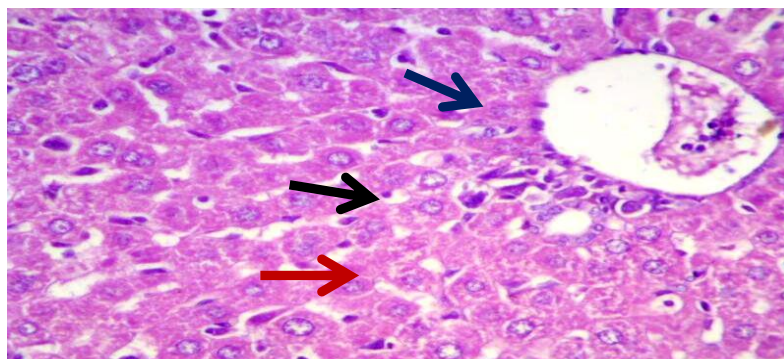


Figure (12): Histopathological section in the liver of animal at 14 days post –treatment with 300mg/kg ethanolic extract shows dispersed necrosed hepatocyte cells (blue arrow) with infiltration of inflammatory cells (red arrow) and slight widening of sinusoids. (black arrow)(H&E stain X200).

ACKNOWLEDGEMENT

The Authors wish to acknowledge to all staff of Institute of Genetic Engineering and Biotechnology for post graduate studies, Baghdad University, as well as the Enzymology Laboratory for providing the necessary facilities to carry out this study.

REFERENCES

1. Kadir J, Charudattan R. *Dactylaria higginsii*, a fungibioherbicide agent for purple nutsedge (*Cyperus rotundus*). *Biological control: theory and applications in pest management.*, 2000; 17: 113-124.
2. Ardestani A, Yazdanparast R. *Cyperus rotundus* suppresses AGE formation and protein oxidation in a model of fructose-mediated protein glycoxidation. *International Journal of Biological Macromolecules.*, 2007; 41: 572–578.
3. Scalbert A, Williamson G. Dietary intake and bioavailability of polyphenols. *Journal of nutrition.*, 2000; 130: 2073S-2085S.
4. Trombino S, Serini S, Di Nicuolo F, Celleno L, Andò S, Picci N, Calviello G, Palozza P. *J. Agric. Food Chem.*, 2004; 52: 2411.
5. Li Y, Schellhorn HE. New developments and novel therapeutic perspectives for vitamin C. *Critical Review. J Nutr.*, 2007; 137: 2171-84.
6. Naidu AK. Vitamin C in human health and disease is still a mystery ? An overview. *Nutr J.*, 2003; 2: 1-10.
7. Ozaki Y, Soedigdo S, Wattimena YR, Suganda AG. Antiinflammatory effect of mace, aril of *Myristica fragrans* Houtt. and its active principles. *Japan J. Pharmacol.*, 1989; 49: 155-163.
8. Al-Jumaily EFA, Al-Isawi JKT . Evaluation of antioxidant activities of *Cyperus rotundus* (Ethanol extract and purified flavonoid) Against Tetrachloride-Induced Hepatic Damage in Mice. *IOSR- J. of Pharmacy.*, 2015; 5,1: 48-53.
9. AL- Jumaily EA, AL – Mosawe EHA, Ad 'hian AH. The Extraction and Purification of Apigenin from the sage *Salvia Officinalis* .L. Duhok J. Univ., 2010; 3.1: 375 -380.
10. Sulamin GM, Sammarrae KWA, Ad'hiah AH. Chemical characterization of Iraqi propolis sample and assessing their antioxidant potentials. *Food and chemical toxicology.*, 2011; 4419: 2415-1412.
11. Jollow D J, Mitchell JR, Zampoglione N, Gillete JR . *Pharmacology.*, 1974; 11: 151-169 .

12. Shangari N, O'Brien PJ. Catalase activity assays. Current Protocols. Wiley online library. 2006.
13. Crapo JD, McCord JM, Fridovich I. Methods Enzymol., 1978; 53: 382.
14. SAS. Statistical Analysis System, User's Guide. Statistical. Version. 7th ed. SAS. Inst. Inc. Cary. N.C. USA.2010.
15. Sinha MM, Sil PC. Aqueous extract of terminal injury prevent carbontetra-chloride induce hepatic and renal disorder" BMC Complementary and Native Medicine., 2006; 6, 33: 1472.
16. Szymonic-Lesiuk S, Chechowska G, Stryjecka M. Catalase, superoxide dismutase, and glutathione peroxidase activities in various rat after carbon tetrachloride intoxication. J Hepatobiliary Pancreat Surg., 2003; 10: 309-15.
17. Ozkaya YG, Agar A, Yargicoglu P, Hacioglu G, Bilmen-Sarıkcioglu S, Ozen I, Aliciguzel Y. The effect of exercise on brain antioxidant status of diabetic rats. Diabetes Metab., 2002; 28: 377-384.
18. Aliciguzel Y, Ozen I, Aslan M, Karayalcin U. Activities of xanthine oxidoreductase and antioxidant enzymes in different tissues of diabetic rats. J Lab Clin Med., 2003; 142: 172-177.
19. Atessahin A, Yilmaz S, Karahan I, Tasmedir PB. The effects of vitamin E and selenium on cypermethrin induced oxidative stress in rats. Turk. J. Vet. Anim. Sci., 2005; 29: 385-91.
20. Chandrashekar VM, Abdul Haseed TS, Habbu PV, Nagappa AN. Hepatoprotective activity of *Wrightoa tinctoria* (Roxb) in rats. Indian Drugs., 2004; 41: 366.
21. Kilani S, Ledauphin J, Bouhlel I, Ben Sghaier M, Boubaker J, Skandrani I, Mosrati R, Ghedira K, Barillier D, Chekir-Ghedira L. Comparative study of *Cyperus rotundus* essential oil by a modified GC/MS analysis method. Evaluation of its antioxidant, cytotoxic, and apoptotic effects. Chemistry & Biodiversity., 2008; 5: 729-742.
22. Necib Y, Bahi A, Zerizer S, Abdennour C, Boulakoud MS. Hepatoprotective role of sodium selenite against oxidative damage induced by mercuric chloride in rat albinos wistar. Journal of Stress Physiology and Biochemistry., 2013; 9,4: 230-240.
23. Mahayrookh AM, Mehjabeen, Rehman AB, Jahan N. Toxicological and Biochemical Evaluation of Ethanolic crude extract of *Cyperus rotundus*. International Journal of Pharmacy and Pharmaceutical Sciences., 2013; 5: 0975-1491.

24. Sailor GU, Dudhrejiya AV, Seth AK, Maheshwari R, Nirmal S, Aundhia C .Hepatoprotective effect of *Leucas Cephalotes* Spring on CCl₄ induced Liver Damaged in Rats. Pharmacology on Line., 2010; 1: 30-38.
25. Al-Jumaily EFA, Al-Isawi, JKT. Chemical Composition and Antioxidant Potential of Polyphenol Compounds of *Cyperus rotundus* L. Rhizomes. American J. of Phytomedicine and Clinical Therapeutics., 2014; 11: 1277-1286.
26. Ashok SK, Somayaji SN, Bairy KL. Hepatoprotective effects of *Ginkgo biloba* against carbon tetrachloride induced hepatic injury in rats. Ind. J. Pharmacol., 2001; 33: 260–266.
27. Sampathkumar R, Sivakumar T, Sivakumar P, Nethaji R. Hepatoprotective and *in vivo* antioxidant effect of *Careya arborea* against carbon tetrachloride induced liver damage in rats. Inter. J. of Molecular Medicine and Advance Sciences. 2005. 1.4. 418-424.