



**RECURRENT GIANT FIBROSARCOMA ARISING IN  
DERMATOFIBROSARCOMA PROTUBERANS WITH DISTANT  
LUNG METASTASIS**

**<sup>1\*</sup>Ozinko M.O., <sup>2</sup>Otei, O.O., <sup>3</sup>Ekpo R.G., <sup>4</sup>Asuquo M., <sup>5</sup>Ofutet E.O**

<sup>1,2,3</sup>Burns and Plastic Surgery Unit, Department of Surgery, University of Calabar Teaching Hospital, Calabar, Cross River State, Nigeria.

<sup>4</sup>General Surgery Unit, Department of Surgery, University of Calabar Teaching Hospital, Calabar, Cross River State, Nigeria.

<sup>5</sup>Department of Physiology, Faculty of Basic Medical Sciences, College of Medical Sciences, University of Calabar, Calabar, Cross River State, Nigeria.

Article Received on 27/07/2015

Article Revised on 18/08/2015

Article Accepted on 09/09/2015

**\*Correspondence for**

**Author**

**Dr. Ozinko M.O.**

Burns and Plastic Surgery Unit, Department of Surgery, University of Calabar Teaching Hospital, Calabar, Cross River State, Nigeria.

**ABSTRACT**

Dermatofibrosarcoma protuberans (DFSP) is a rare skin tumor which typically arises in the dermis as a multi-nodular mass, and then spreads into the subcutaneous tissues and muscles but rarely metastasize. Only few cases of gluteal dermatofibrosarcoma protuberans have been reported to metastasize to the lungs. This is a histologically proven case of fibrosarcoma arising from DFSP of the gluteal area with deep muscle extension and distant metastasis to the lungs, evaluated with

chest x-ray and abdominal ultrasound. Treatment is by surgery, radiotherapy and immunotherapy.

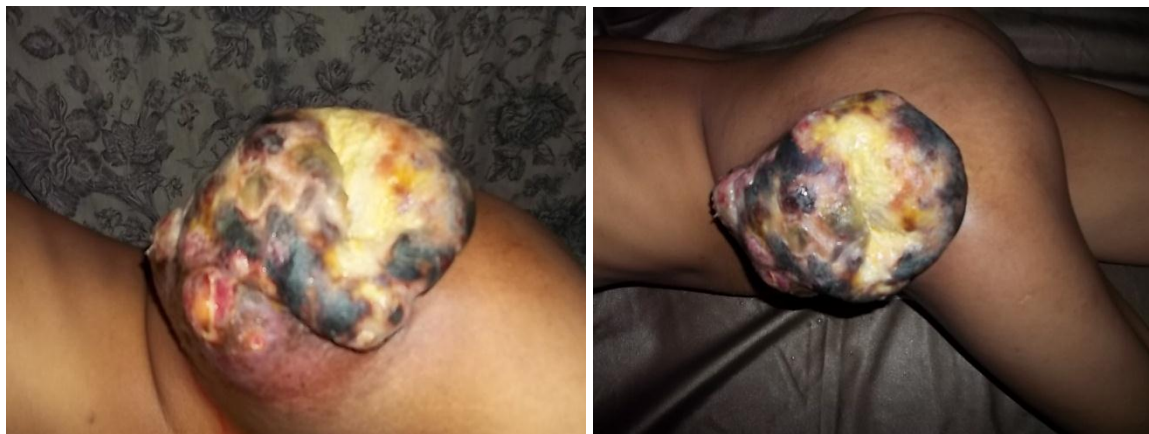
**KEYWORDS:** Dermatofibrosarcoma protuberans, lung metastasis, muscle extension, immunotherapy

**INTRODUCTION**

Dermatofibrosarcoma protuberans (DFSP) is a relatively uncommon slow growing locally aggressive fibrous skin tumor (Sinha *et al.*, 2001 and Asuquo *et al.*, 2014). Regional and distant metastasis from DFSP does occur, but rare probably less than 1% (Ah-weng *et al.*, 2002). The term “dermatofibrosarcoma protuberans” was coined by Hoffman (1925). This condition is a type of soft tissue sarcoma which are cancers that affect skin, fat, muscle and

similar tissues. The recognition of this tumor is important because of the excellent prognosis after adequate surgical excision (Sinha *et al.*, 2001). The case report is done because of its rapid aggressive growth, high recurrence rate and distant metastasis to the lungs in our patient.

### CASE REPORT



**Fig. 1. A huge fungating tumor of the left gluteal area**

A 24 year old female student who presented with the history of recurrent, fungating mass in the left gluteal area for eight months duration. She initially had a small gluteal swelling which was painless and grew to the size of the patient's fist before it was excised in a private clinic and she was not told what the lesion was. Later she noticed multiple nodular swellings at the same site. The tumor progressively increased in size over four months and then ulcerated with haemorrhagic, foul smelling discharge. She also had spontaneous bleeding from the ulcer, weight loss and nausea. She started having unproductive cough, chest pain, and difficulty in breathing two months prior to presentation. No history of neither jaundices nor bone pain.

Prior to presentation, she sought treatment in a healing home of a church where she had multiple scarification marks and topical herbal preparation. Examination revealed a patient who was chronically ill looking, pale, anicteric, with a huge fungating irregular multi-nodular mass, measuring 24x16x8cm. The ulcer measures 8x6cm, nodular with raised edge. Excessive contact bleeding on change of dressings. Regional lymph nodes were not enlarged. Chest examination showed trachea central, fine crepitation and reduced air entry. On investigation, full blood count showed marked anemia with haemoglobin of 5 g/dl and features of iron deficiency anemia. Chest x-ray showed cannon ball metastasis and abdominal

ultrasound scan did not reveal liver spread. Incision biopsy for histopathological report showed fibrosarcomatous type of dermatofibrosarcoma protuberans. She was optimized with erythropoietin, hematinics and adequate nutrition. Informed consent was obtained and she was told about the risk of surgery, the possibility of recurrence and the need for check-up. The tumor was excised with tumor free margin of 4cm using frozen sections. She was referred to another hospital for radiotherapy and immunotherapy

## DISCUSSION

Dermatofibrosarcoma protuberans is a rare neoplasm in the population. It is a low grade sarcomatous tumor resembling keloid as it has a marked tendency to recur locally if inadequate margins are obtained (Asuquo *et al.*, 2007; Hoffman, 1925). The incidence of DFSP occurs from birth to the 6<sup>th</sup> decade with the maximum incidence in the 2<sup>nd</sup> and 3<sup>rd</sup> decades (Asuquo *et al.*, 2007). This tumor has been reported in newborn, children and elderly individuals. Studies reveal almost equal sex distribution or a slight male prevalence (Asuquo *et al.*, 2007). Most of the lesions occur over the trunk or proximal extremities, but cases of the scalp, hand and foot have been reported (Cakir *et al.*, 2003; Williams *et al.*, 2002). Lesions ranging from 1cm to more than 25cm have been described in literature.

The clinical presentation was that of painless, multi-lobulated mass which ulcerated with spontaneous as well as contact bleeding in a recurrent tumor. There was history of unproductive cough, chest pain, easy fatiguability but no jaundice or bone pain. Examination showed chronically ill-looking patient, pale, anicteric with a huge fungating non tender, hard mass with an ulcer measuring 8x6cm with raised edge and severe contact bleeding. The tumor was tethered to the skin and underlying tissues. No regional lymphadenopathy which was in keeping with other studies (Kadic *et al.*, 2000; Ani *et al.*, 1976).

Chest x-ray revealed cannon ball metastasis. No evidence of liver metastasis, ascites nor peritoneal deposit detected on magnetic resonance imaging of the abdomen. Excision biopsy for histopathology revealed a multinodular lesion with increased cellularity, irregular, short intersecting bands of tumor cells forming a storiform pattern and cells radiating from a central hub of fibrous tissues forming a cartwheel pattern. Focal fibrosarcomatous changes with characteristic herring bone pattern were seen. MRI showed a tumor with subcutaneous and muscular infiltration as well as subcutaneous linear extension suggestive of the diagnosis. Differential diagnosis of superficial soft tissue masses included benign tumors like lipoma, hemangioma, peripheral nerve sheath tumors and malignant tumors like malignant fibrous

histiocytoma, liposarcoma, leiomyosarcoma and epithelioid sarcoma and metastasis. Histological variants identified include; Bednar tumors (pigmented DFSP) contain dark coloured cells called melanin containing dendritic cells. Bednar tumors account for approximate 1-5% of all DFSP cases. Myxiod DFSP tumors contain an abnormal type of connective tissue that is called myxiod stroma. This type of tumors is uncommon, presents a diagnostic challenge and is important to recognize in order to prevent both under- and over-treatment. Giant cell fibrosarcoma, referred to as juvenile DFSP because it typically affects children and adolescents, is characterized by giant cells in the tumor. Rarely, the tumors involved in the different types of DFSP can have regions that look familiar to fibrosarcoma and more aggressive type of soft tissue sarcoma. In this case, the condition is called fibrosarcomatous (DFSP). These tumors are more likely to metastasize than tumors in the other types of DFSP (Kadic *et al.*, 2000).

Dermatofibrosarcoma protuberans is associated with a rearrangement of genetic material between chromosomes 17 and 22. It is the result of a new mutation that occurs in the body's cells after conception and is found only in the tumor cells. Immunohistochemistry using CD 34 is a useful marker for the differentiation of DFSP from dermatofibroma. Immunostaining using CD34 is also helpful in identifying tumor cell at the surgical margins especially when treating recurrent DFSP where tumor cells are often interspersed within the scar tissues (Van Deweyer *et al.*, 2002). Surgery is the mainstay of treatment, wide excision with a safety margin of 3-5cm including the underlying fascia is recommended, emphasis is on histology free margin for local control. Computerized tomogram is helpful in deciding the line of incision and avoiding inadequate excision which leads to recurrence or metastasis (Gupta *et al.*, 2001). Moh's micrographic surgery has the advantage of high oncologic effectiveness and maximal tissue saving and is increasingly accepted as the treatment of choice which is 98% curative (Ah-weng *et al.*, 2002). Chemotherapy is not a treatment of choice (Asuquo *et al.*, 2007). Radiation has a limited role, recently has been used as adjunct to surgery. Post operative radiotherapy is an effective treatment to decrease the recurrence rate for the patients with positive microscopic margin or the patient without suitable surgical treatment (Shimali *et al.*, 2002). Immunotherapy using imatinib may provide an alternative treatment for unresectable tumors or adjunctive treatment to surgery (Asuquo *et al.*, 2007). An outpatient follow up care is very important as the tumor has the inclination to recurrence. Poor prognosis is characterized by its late presentation, aggressive local invasion, histologic type

and distant metastasis as in our index patient. However, as a local disease, prognosis is excellent.

## CONCLUSION

DFSP is a rare tumor. Painless, cutaneous and multilobulated tumor that should arouse suspicion. This case illustrates a very rare case of DFSP of the gluteal region with deep and extensive muscle infiltration and distant metastasis to the lungs as evidenced on chest radiograph. The histological evidence of fibrosarcomatous type of DFSP which was demonstrated could account for its aggressive nature in our patient.

## REFERENCES

1. Ah-weng A., Marden J.R., Sanders D.S.A and Waters R. DFSP treated with micrographic surgery. *British Journal of Cancers.*, 2002; 87: 1356-1389
2. Ani A.N., Attah E.B., and Ajaji O.O. Dermatofibrosarcoma protuberans: Analysis of eight cases in an African population. *Ann surg.*, 1976; 42: 934-940
3. Asuquo M.E., Umoh M.S., and Ebghe G. Dermatofibrosarcoma protuberans: case reports. *Annals of African medicine.*, 2007; 6: 80-83
4. Cakir B., Misirihoglu A., Gideroglu K., and Akoz. Giant fibrosarcoma arising in dermatofibrosarcoma protuberans on the scalp during pregnancy. *Dermatol Surg.*, 2003; 29: 297-299.
5. Gupta K.A., Singh, Manelel A.M. and Jaiswal N.K. A rare case of scalp dermatofibrosarcoma protuberans with intracranial extension and distant soft tissue and liver metastasis. *Calicut Med Journal.*, 2001; 9(2): 8.
6. Hoffman E. Dermatofibrosarcoma protuberans. *Dermatol Journal.*, 1925; 43: 1-28.
7. Kadic M., Padovase V., and Stan Kovic R. Recurrent DFSP treated with Mohr's micrographic surgery. *Dermatol venological.*, 2000; 9: 1-8.
8. Shimali R., Garg L., Sativa V. and Jani S. Dermatofibrosarcoma protuberans DFSP-CT Findings in DFSP-A rare skin tumor. *Indian Journal Radio imaging.*, 2002; 12: 357-358.
9. Sinha, V. D., S. R. Dharker and G. S. Kalra. "Dermatofibrosarcoma protuberans of scalp: a case report." *Neurology India.*, 2001; 49(1): 81.
10. Van Deweyer E., De Saint A.S.N, and Gebhad M. DFSP: How wide in surgical excision. *Act chir Belgium.*, 2002; 02: 455-458.
11. Williams C., Torreggiani Khalid Al-ismali., and Peter L M. DFSP: MR imaging features. *Am Journal Roentgenol.*, 2002; 178: 989-993.