

EVALUATION OF ANTIULCER ACTIVITY OF RED PEPPER AND GARLIC BULB AGAINST INDOMETHACIN- INDUCED GASTRIC ULCER IN RATS: BIOCHEMICAL AND HISTOPATHOLOGICAL STUDY.Gehan Salah Eldin Moram^{1*}, Nadia Ragheb Ali Abouzeid² and Manal I Salman³¹Biochemistry and Nutrition Department, Women's College Ain Shams University, Egypt.²Electron Microscope Lab., Ain Shams Specialized Hospital, Ain Shams University, Cairo, Egypt.³Pathology Department, Faculty of Medicine Ain Shams University, Egypt.***Author for Correspondence: Dr. Gehan Salah Eldin Moram**

Biochemistry and Nutrition Department, Women's College Ain Shams University, Egypt.

Article Received on 09/12/2015

Article Revised on 30/12/2015

Article Accepted on 21/01/2016

ABSTRACT

The objective of this study was to evaluate the antiulcer effects of pretreatment with red chilli pepper (RCP) and garlic (GA) bulb juices at a dose(8ml/kg body weight) against indomethacin--induced gastric ulcer in rats(40 mg/Kg body weight) and was compared with ranitidine (RAN) as reference drug at a dose (100 mg/kg b.wt.). **Methods:** Animals were divided into five groups; namely, healthy rats (Control (-ve)), ulcerated rats (Control (+ve)), RAN Protection (Ranitidine+Indomethacin),RCP Protection(RCP + Indomethacin)and GA Protection(GA + Indomethacin). **Results:** The results revealed that oral administration of RCP or GA juices as pretreatment showed a significant reduction in lesion index. The mechanism of its gastro protective activity may be attributed to significant reduction in volume gastric juice, total acidity of gastric juice, gastric ulcer index, malondialdehyde level, serum interleukin-1, serum tumor necrosis factor-alpha, gastric cyclooxygenase activity and gastric total nitric oxide concentration along with significant elevation gastric prostaglandin level and gastric cytochrome P₄₅₀ reductase activity compared with ulcerated control (+ve) group. The juice extracts also markedly attenuated the reduced of gastric antioxidant enzymes as well as pH and mucin content in the ulcerated rats. Microscopic and histopathological examinations confirmed the above results and revealed that pretreatment with RCP or GA juices improved the gastric mucosal damage induced by indomethacin. **In conclusion:** These findings indicated that pretreatment with RCP and GA juices could be used for healing acute gastriculcer disease, the probable mechanisms are via cytoprotective effect coupled with antisecretory activity.

KEYWORDS: Indomethacin, Gastric ulcer, Red chilli pepper, Garlic, Antioxidants, Histopathological changes.**INTRODUCTION**

Gastric ulceration is a benign lesion on the mucosal epithelium upon exposure of the stomach to excess acid and aggressive pepsin activity.^[1] Stress, smoking, nutritional deficiencies and frequent intake of non-steroidal anti-inflammatory drugs(NSAIDs)develop the gastric ulcer prevalence in the world.^[2] There is a balance in the stomach between the aggressive digestive capabilities of acid plus pepsin and the mucosal barrier. Ulceration occurs when there is a disturbance of the normal equilibrium caused by either enhanced aggression or diminished mucosal resistance. Several factors are implicated in the pathogenesis of gastric ulcer. These include increased acid-pepsin secretion, impaired bicarbonate neutralization, impaired mucus secretion and precipitate lesions on the mucosal layer.^[3] Acid and pepsin secretion must be considered together because in practice it is difficult to distinguish the effects of each alone.^[4]

Many factors such as gastric acid and pepsin secretion, gastric microcirculation, prostaglandin E₂ (PGE₂) content,^[3] and proinflammatory cytokines interleukin-1(IL-1) and tumor necrosis factor (TNF- α)play important roles in the genesis of gastric mucosal damage, and its subsequent development.^[5,6] It has been reported that increases in nitric oxide synthase (NOS) activity is involved in the gastric mucosal defense and also in the pathogenesis of mucosal damage.^[7,8]

The ideal aims of treatment of gastric ulcer disease are to relieve pain, heal the ulcer and delay ulcer recurrence. To date, no drug meets all the goals of therapy. A wide range of drug is currently available for treatment of gastric ulcer which includes proton pump inhibitors, H₂-blockers, antacids and anticholinergics. The most common adverse effects of these drugs are hypergastrinemia, hypersensitivity, gynecomastia, impotence, arrhythmia and blood dyscrasias such as thrombocytopenia.^[9,10,11] These effects sire the rationale

for the development of new antiulcer drugs. For this reason, the hunt is still on to discover a natural medicine having antiulcerogenic properties.

Plants medicine is fast emerging as alternative synthetic drugs for treatment of ulcer possibly due to lower costs, availability, lower adverse effects and perceives effectiveness. Many tropical plants have been scientifically reported to possess potent antiulcer activity.^[12,13]

Capsicum annum linn commonly known as Red pepper belonging to family Solanaceae, red pepper popularly known as Chilli. Red pepper are usually consumed as food and used as additives in the food industry. In fact, in Indian, Native American, and Chinese traditional medicine, *Capsicum* species have been used for the treatment of arthritis, rheumatism, skin rashes, dog/snake bites, and flesh wounds.^[14, 15] Red pepper may prevent cancer, heart disease, stroke, blood clots, obesity, high blood pressure, high cholesterol, bronchitis, emphysema, coughs and colds.^[16-19]

Furthermore, red pepper benefit in dealing with diabetes and reducing the risk of type 2 as they improve insulin regulation. These therapeutic applications are related to the capsaicinoid, phenolic compound, and carotenoid content of red peppers. The active principle in red peppers is capsaicin (8-methyl-N-vanillyl-6-noneamide), which considered one of many alkaloids that is referred to as a Capsaicinoid.^[20]

Allium sativum Linn commonly known as garlic belongs to family Liliaceae. Garlic contains water-soluble and oil-soluble organosulfur compounds (OSCs) such as diallyl sulfide (DAS), diallyl disulfide (DADS), diallyl trisulfide (DATS) and ajoene are produced during the decomposition of alliin, which is released upon crushing garlic.^[21,22] Apart from its use as spice, garlic is reported to possess a wide variety of pharmacological actions, among which, the best known are its effect on cardiovascular system and in prevention of gastric cancer.^[23,24] Garlic has proven beneficial health effects including antibacterial, anti-inflammatory, antifungal, hypolipidemic, and hypoglycemic properties. Since, garlic is widely used as spice and also as medicine for the treatment of various diseases.^[25]

Popularly known that the consumption of garlic and red pepper in excessive amounts leads to gastric ulcers in view of its irritant and likely acid secreting nature. Persons with ulcers are advised either to limit or avoid its use.

On the other hand, other scientists found that some spices especially red chillis pepper and garlic have a good medicinal effect on healing ulcers. They found that red chillis pepper involves functional substances called capsaicin which has a gastroprotective effect against experimental gastric mucosal injury in animals.^[26] Also,

they found that garlic contains functional substance called organosulfur compounds which has anti-inflammatory activity against ulcers.^[27,28] On the contrary, other scientists^[29,30] remarked that hot and spicy food as long use of aspirin is the main cause of chronic gastritis leading to ulcer disease. In this respect, red pepper and garlic incriminated in the increase of acid secretion.^[31]

For as much as this clash, this study carried out to elucidate the antiulcerogenic activity using fresh juices of raw red pepper and garlic bulb in animal models.

MATERIALS AND METHODS

1- Chemicals

1-1Indomethacin (Liometacen)®: Each ampoule contains 50 mg indomethacin (The NILE Co. for Pharm. & Chemical Ind.). The dose for rat was 40 mg/kg body weight orally given to induce ulcer.^[32]

1-2Ranitidine (Zantac)®

Each tablet contains 150 mg of ranitidine hydrochloride (Glaxo Smith Kline Industries.) that inhibits gastric ulcer. Ranitidine drug was dissolved in distilled water in dose 100 mg/kg body weight of rat using a stomach tube.^[33]

2- Plant materials

The raw Red Chilies Pepper (*Capsicum annum linn*), and garlic (*allium sativum*) were obtained from the local vegetable market (Cairo, Egypt). Both samples of raw Red Chills Pepper and Peeled garlic bulbs were washed, dried, cut and squeezed using juicer. The juice that came out was collected and filtered. Each one of them was administered at dose 8ml/kg body weight of rats orally by stomach tube.

3-Animals

Thirty female wistar albino rats of Sprague Dawley strain were obtained from Laboratory Animal Colonies, Helwan, Egypt. The average weight was 150±10g. They were maintained under standard conditions of temperature, humidity and light (12 h dark, 12 h light) and provided with standard commercial pellets diet and having free access to water. Before testing, the animals were fasted for 36 h with access to water ad libitum.

Experimental design

The animals were divided into five groups of six rats each. Gastric ulcers were induced in rats by a single oral dose of indomethacin (40 mg/Kg b.wt).^[32] The animals were sacrificed eight hours after treatment. The standard drug (Ranitidine) and fresh juices of red pepper and garlic were given orally 30 minutes prior to indomethacin treatment.

Group I healthy rats (Control (-ve)): Rats in this group were considered as control and received only saline 1ml/100 gm b.wt.

Group II ulcerated rats (Control (+ve)): Rats in this group were orally received indomethacin at dose (40 mg/Kg b.wt) to induced ulcer.

Group III RAN Protection (Ranitidine +Indomethacin): Rats in this group were orally given ranitidine at dose (100 mg/Kg b.wt) 30 minutes before administration of indomethacin.

Group IV RCP Protection (RCP + Indomethacin): Rats in this group were orally given fresh juice of red pepper at dose (8 ml/Kg b.wt) 30 minutes before administration of indomethacin.

Group V GA Protection (GA + Indomethacin): Rats in this group were orally given fresh juice of garlic bulb at dose(8 ml/Kg b.wt)30 minutes before administration of indomethacin.

On completion of experimental period, the animals were sacrificed. Blood samples were collected via cardiac puncture. Blood was allowed to stand for 15 minutes at temperature of 37°C, then was centrifuged at 4000 rpm for 20 min by EBA8 centrifuge (obtained from china) for the separation of serum. Serum was removed and kept in plastic vials at -20°C until used for biochemical analyses.

Methods

1-Assessment of Gastric Secretion

1-1 Measurement of volume and Ph of gastric juice

At the end of the experimental period, the rats were sacrificed and the stomach was removed. The gastric content was collected and centrifuge for 10 min at 3000 rpm and the supernatant was separated. The volume and pH of centrifuged gastric juice were measured by graduated cylinder and digital pH meter. The volume was expressed as ml.^[34]

The gastric juice decrease percentage was calculated for each treated group according to the method described by Parmar and Desai^[31] by using the following equation:

$$\text{Decrease ratio (DR)} = (\text{VC} - \text{VT}/\text{VC}) \times 100.$$

where:

VC = Volume of gastric juice in control positive group.

VT = Volume of gastric juice in treated group

1-2 Determination of free acidity^[35]

An aliquot of 1ml gastric juice diluted with 1ml of distilled water was taken into a 50 ml conical flask and 2-3 drops of topper's reagent as indicator was added to it and titrated with 0.01N NaOH until a canary yellow colour was observed.

The volume of 0.01N NaOH consumed was noted. The free acidity was calculated by using the following formula:

$$\text{Acidity} = \frac{\text{Vol. of NaOH} \times \text{Normality} \times 100 \text{ mEq/L}}{0.1}$$

1-3 Determination of total acidity

Titration was further continued against 0.01N NaOH using phenolphthalein as indicator, until a permanent

pink colour was observed. The volume of 0.01N NaOH consumed was noted. Total acidity was also calculated by using the same formula as that of free acidity.

2-Determination of Gastric mucin^[36]

After the collection of gastric juice, the glandular portion excisions that opened the lesser curvature were opened. The everted stomachs were soaked for 2 h in 0.1% alcian blue 8GX dissolved in 0.16 M sucrose buffered with 0.05 M sodium acetate adjusted to a pH with hydrochloric acid. Uncomplexed dye was removed by two successive washes of 15 and 45 min in 0.25 M sucrose solution. Dye complex with mucus was diluted by immersion in 10 ml aliquots of 0.5 M magnesium chloride for 2 h. The resulting blue solutions were shaken briefly with an equal volume of diethyl ether and the optical density of the aqueous phase was measured at 605 nm using spectrophotometer. The mucin content of the sample was determined from the standard curve of mucin, which has been expressed in microgram/gram of wet gland tissue.

3-Determination of pepsin^[37]

Aliquots of 20 µl of the gastric content were incubated with 500 µl of albumin solution (5 mg/ml in 0.06 N hydrochloric acid) at 37°C for 10 min. The reaction was stopped with 200 µl of 10% trichloroacetic acid and the samples were centrifuged at 1500 rpm for 20 min. The supernatant was alkalinized with 2.5 ml of 0.55 M sodium carbonate and 400 µl of 1.0 N Folin's reagent was added to the tubes, which were incubated for 30 min at room temperature. The absorbance of the samples was determined by spectrophotometry at 660 nm. The concentration of pepsin is determined by a standard curve.

4-Determination of Gastric Mucosa

Gastric mucosal of cyclooxygenase (Cox-2) activity, prostaglandin E₂ (PGE₂) level, cytochrome P₄₅₀ reductase (Cyto P₄₅₀) activity and total nitric oxide (TNO) concentration were determined according to Hemler and Lands,^[38] Hamberg and Samuelsson,^[39] Mc-Lean and Day^[40] and Griess et al.^[41] respectively.

5-Determination of Gastric oxidative stress markers

Oxidative stress markers were measured in gastric tissue homogenates included super oxide dismutase (SOD)^[42] activity, catalase (CAT)^[43] enzyme activity, nonprotein sulfhydryl (NP-SH)^[44] and malondialdehyde (MDA)^[45] concentration.

6- Measurement of Serum Parameters

Interleukin-1(IL-1), Tumor necrosis factor-alpha (TNF-α) were determined according to Grassi et al.^[46] and Beutler et al.,^[47] respectively.

7-Determination of degree of ulceration (ulcer index)

The surface area (A) mm² covered by each lesion was measured^[48] and the sum of erosion areas per rat stomach was calculated. Percentage ulcerated surface (US) was calculated as

$$\% \text{ US} = \frac{\text{Total area covered by ulcer}}{\text{Total corpus mucosal surface}} \times 100$$

Ulcer index was calculated from percentage ulcerated surface, The following score was used in order to calculate ulcer index:

0. No ulcer	6. 15 - 20
1. US <0.5	7. 20 - 25
2. 0.5 - 2.5	8. 25 - 30
3. 2.5 - 5	9. 30 - 35
4. 5-10	10. US >35
5. 11-15	

$$\text{U.I.} = [\text{Ulcerated area/total stomach area}] \times 100.$$

$$\% \text{Ulcer inhibition} = \frac{[\text{U.I. in control} - \text{U.I. in test}]}{100/\text{U.I. in control}} \times 100.$$

8-Histopathological Examination

For the light microscopic examination, the stomach tissues were collected from all the animals' groups, fixed in 10% neutral buffered formalin (pH=7.0), dehydrated in ascending grades of ethyl alcohol, cleared in xylene, impregnated in paraffin wax and sections of 5–7 μm thickness were taken. Sections were stained with Harri'shaematoxylin & eosin according to Bancroft and Stevens,^[49] and examined for any structural changes under light microscope.

9-Statistical Analysis

Data were analyzed using one-way analysis of variance (ANOVA) using the Statistical Package for Social Science (SPSS) program, version 17.0 followed by Newman–Keuls post hoc test for multiple comparisons. Differences were considered significant at ($p < 0.05$) level.

3. RESULTS

The statistical data in Table (1) show the effect of red Pepper and garlic juices on gastric secretions of indomethacin ulcerated rats. Indomethacin administration caused significant ($p < 0.05$) increase in free acidity and total acidity of gastric juice associated with significant ($p < 0.05$) decrease in pH value with a corresponding significant ($p < 0.05$) increase in gastric volume of gastric content. Pretreatment with the ranitidine drug or fresh juices of red pepper and garlic bulb produced significant decrease in gastric volume, free acidity and total acidity coupled with significant increase in pH value when compared with ulcerated control rats. The values of Decrease ratio (DR) were significantly decreased in all treated rat groups compared with control (+ve) group.

Indomethacin administration brought about a significant ($p < 0.05$) increase in specific pepsin activity as well as significant reduction ($p < 0.05$) in mucin content of gastric mucosa of ulcerated rats when compared with the normal (-ve) control (table 2). The observed changes in these parameters were significantly attenuated ($p < 0.05$) in the Pretreatment rats with juices test plants. Pretreatment with red pepper juice revealed more potent

efficacy in the modulation of both pepsin activity and mucin contents of gastric mucosa of ulcerated rats. (table 2)

Table (3) revealed the effects of juices test plants on the lipid peroxidation and antioxidant enzymes activities of gastric mucosal of indomethacin ulcerated rats. MDA level was significantly increased ($p < 0.05$) in gastric tissues associated with significant ($p < 0.05$) decrease in nonprotein sulfhydryl (NP-SH) content in the ulcerated animals. A significant reduction ($p < 0.05$) was also observed in the activities of SOD and catalase (CAT) enzymes in the indomethacin-induced animals. Commendably, both juices test plants regimen resulted in significant improvement ($p < 0.05$) in these parameters and the observable effects compared favorably well with both normal control and standard drug (ranitidine) employed in the study.

Inhibitory action of indomethacin on prostaglandin synthesis coupled with free radicals formation has been opined as critical biochemical events in the pathogenesis of gastric ulceration.

The statistical data in Table (4) presented that, ulcerated positive control group showed significant ($p < 0.05$) increase in gastric cyclooxygenase (COX2) activity and total level nitric oxide while, there were significant ($p < 0.05$) decrease in gastric prostaglandin E_2 and cytochrome P_{450} reductase activity compared to (-ve) control group. The pretreatment groups with ranitidine drug or fresh juices of red Pepper and garlic bulb showed a significant ($p < 0.05$) decrease in gastric cyclooxygenase (COX2) activity and total nitric oxide while, there were significant ($p < 0.05$) increase in gastric prostaglandin E_2 and cytochrome P_{450} reductase activity compared to ulcerated (+ve) control group.

As shown in Table (5), indomethacin administration rats led to significant ($p < 0.05$) increases in serum interleukin-1 and tumor necrosis factor-alpha levels compared to (-ve) control group. The pretreatment groups with ranitidine drug or fresh juices of red Pepper and garlic bulb showed significant ($p < 0.05$) decrease in serum interleukin-1 and tumor necrosis factor-alpha levels compared to ulcerated (+ve) control group.

Gross Examination of Gastric Lesions

Control group showed no gross mucosal lesions (Fig. 1 A). Indomethacin showed marked gross mucosal lesions, including long hemorrhagic bands of different sizes and petechial lesions (Fig 1B). Animals pretreated with RCP and GA showed very mild mucosal lesions (Fig 1C & D) while animals pretreated with ranitidine showed few minute mucosal lesions (Fig 1E).

The statistical data presented in table(6) show a significant increase in the mean percentage of ulcerated mucosal surface area and ulcer index in the indomethacin induced ulceration group as compared to the control

group ($P < 0.05$). There was also a statistically significant difference between the mean percentage of the ulcerated mucosal surface area and ulcer index in the pretreatment groups with ranitidine, garlic juice and red pepper as compared to the indomethacin induced ulceration group ($P < 0.05$). However, there was no statistically significant difference of the mean percentage of the ulcerated surface area in the pretreatment group with ranitidine as compared to the pretreatment groups with garlic juice or red pepper ($p < 0.05$).

Histopathological Results

(H&E) stained sections of the stomach of the healthy control group showed intact epithelial lining of the gastric mucosa with moderate mucin secretion. The lamina propria and the muscularis mucosa of the stomach appeared normal. (Fig. 2 A).

H&E-stained sections of the stomach of ulcerated rats (Control (+ve)) revealed that indomethacin-induced

severe degenerative changes in the stomach tissue, characterized by extensive deep mucosal ulceration involving more than half of mucosal thickness, necrosis of lamina epithelia, exposed muscularis mucosa, congestion of blood vessels associated with massive leukocyte cells infiltration, gastric pit damage and vacuolization of the glandular portion, particularly in mucus-secreting cells. (Figs. 2B,C). On the other hand, H&E stained sections of ranitidine Protection group showed leukocyte cells infiltration in sub mucosal layer, the gastric mucosa showed only few erosions and focal superficial mucosal ulceration involving less than one third of mucosal thickness. (Figs. 2D,E). While, in red Pepper and garlic Protection groups; the gastric mucosa showed focal superficial mucosal ulceration involving about one third of the gastric mucosal thickness, (Figs. 2F, G, H,I).

Table (1): Effect of fresh juices of red pepper and garlic bulb on gastric juice analysis against indomethacin - induced gastric ulcers in rats.

PARAMETERS GROUPS	Volume of gastric juice (ml)	DR (%)	PH of gastric juice	free acidity	Total acidity
Control (-ve)	2.95 ± 0.42 ^d	-----	4.93 ± 0.28 ^a	3.67 ± 0.18 ^d	4.82 ± 0.43 ^e
Control (+ve)	6.13 ± 0.43 ^a	-----	1.78 ± 0.12 ^e	11.70 ± 0.39 ^a	13.92 ± 0.43 ^a
RAN Protection	3.35 ± 0.24 ^c	45.37 ± 1.40 ^a	4.57 ± 0.14 ^b	4.58 ± 0.63 ^c	5.93 ± 0.37 ^d
RCP Protection	3.50 ± 0.13 ^c	42.81 ± 2.42 ^b	4.13 ± 0.33 ^c	4.98 ± 0.65 ^{bc}	6.67 ± 0.39 ^c
GA Protection	3.93 ± 0.16 ^b	35.73 ± 2.90 ^c	3.77 ± 0.22 ^d	5.43 ± 0.52 ^b	7.75 ± 0.48 ^b

Values are expressed as means ± S.D, n=6

There is no significant difference between means have the same letter in the same Column ($P < 0.05$)

Table 2: Effects of fresh juices of red pepper and garlic bulb on pepsin activity and mucin content against indomethacin -induced gastric ulcers in rats.

PARAMETERS GROUPS	Gastric wall mucus content (µg of alcian blue/g of wet gland)	Pepsin activity (µmole/ml)
Control (-ve)	235.78 ± 1.93 ^c	29.67 ± 0.83 ^e
Control (+ve)	187.14 ± 4.38 ^d	68.63 ± 0.82 ^a
RAN Protection	308.14 ± 3.75 ^a	31.21 ± 0.83 ^d
RCP Protection	303.87 ± 3.85 ^a	34.98 ± 0.78 ^c
GA Protection	297.34 ± 4.43 ^b	37.59 ± 0.75 ^b

Values are expressed as means ± S.D, n=6

There is no significant difference between means have the same letter in the same Column ($P < 0.05$)

Table 3: Effect of fresh juices of red pepper and garlic bulb on some oxidative stress markers against indomethacin -induced gastric ulcers in rats

PARAMETERS GROUPS	MDA (unit/g tissue)	SOD (Unit/mg protein)	CAT (Unit /g)	NP-SH µmol/g tissue
Control (-ve)	6.47 ± 0.15 ^c	81.75 ± 3.16 ^a	8.46 ± 0.67 ^a	3.71 ± 0.033 ^a
Control (+ve)	19.16 ± 2.16 ^a	42.67 ± 1.43 ^d	4.65 ± 0.47 ^d	1.68 ± 0.074 ^c
RAN Protection	7.80 ± 0.35 ^b	79.81 ± 2.20 ^a	8.37 ± 0.59 ^a	3.44 ± 0.026 ^a
RCP Protection	8.26 ± 0.52 ^b	76.39 ± 1.91 ^b	7.58 ± 0.54 ^b	3.19 ± 0.017 ^b
GA Protection	8.94 ± 0.50 ^b	70.03 ± 1.73 ^c	6.35 ± 0.54 ^c	2.91 ± 0.012 ^b

Values are expressed as means ± S.D, n=6

There is no significant difference between means have the same letter in the same Column ($P < 0.05$)

Table 4: Effect of fresh juices of red pepper and garlic bulb on gastric tissues total nitric oxide concentration, cytochrome P₄₅₀ reductase activity, cyclooxygenase activity and prostaglandin E₂ concentration against indomethacin -induced gastric ulcers in rats

PARAMATERS GROUPS	TNO (pg/mg)	Cox-2 (ng/mg)	PGE ₂ (pg/mg)	Cyto P ₄₅₀ Reductase (ng/mg)
Control (-ve)	36.74 ± 2.13 ^d	5.25 ± 0.36 ^e	544.49 ± 27.52 ^a	2.08 ± 0.15 ^a
Control (+ve)	67.93 ± 2.50 ^a	16.49 ± 0.45 ^a	310.92 ± 9.61 ^d	0.56 ± 0.06 ^d
RAN Protection	39.48 ± 1.16 ^c	6.41 ± 0.45 ^d	497.43 ± 24.61 ^b	1.97 ± 0.13 ^a
RCP Protection	40.71 ± 1.36 ^c	6.99 ± 0.43 ^c	467.47 ± 14.91 ^c	1.56 ± 0.08 ^b
GA Protection	46.41 ± 1.79 ^b	8.10 ± 0.35 ^b	447.60 ± 14.94 ^c	1.19 ± 0.06 ^c

Values are expressed as means ± S.D, n=6

There is no significant difference between means have the same letter in the same Column (P<0.05)

Table 5: Effect of fresh juices of red pepper and garlic bulb on serum Interleukin-1 and tumor necrosis factor- α against indomethacin- induced gastric ulcers in rats

PARAMATERS GROUPS	IL-1 (pg/ml)	TNF- α (pg/ml)
Control (-ve)	15.27 ± 0.55 ^e	3.91 ± 0.30 ^d
Control (+ve)	47.66 ± 1.18 ^a	14.90 ± 0.59 ^a
RAN Protection	17.73 ± 1.67 ^d	4.39 ± 0.46 ^d
RCP Protection	21.79 ± 1.35 ^c	5.65 ± 0.24 ^c
GA Protection	25.85 ± 1.23 ^b	7.06 ± 0.50 ^b

Values are expressed as means ± S.D, n=6

There is no significant difference between means have the same letter in the same Column (P<0.05)

Table 6: Effect of fresh juices of red pepper and garlic bulb on ulcer index and degree of protection against indomethacin - induced gastric ulcers in rats

PARAMATERS GROUPS	Ulcerated surface (%)	Ulcer Index	Ulcer inhibition (%)
Control (-ve)	0	0	-----
Control (+ve)	2.63 ± 0.40 ^a	3	-----
RAN Protection	0.12 ± 0.01 ^b	1	95.45
RCP Protection	0.69 ± 0.13 ^b	2	73.76
GA Protection	0.65 ± 0.17 ^b	2	75.29

Values are expressed as means ± S.D, n=6

There is no significant difference between means have the same letter in the same Column (P<0.05)

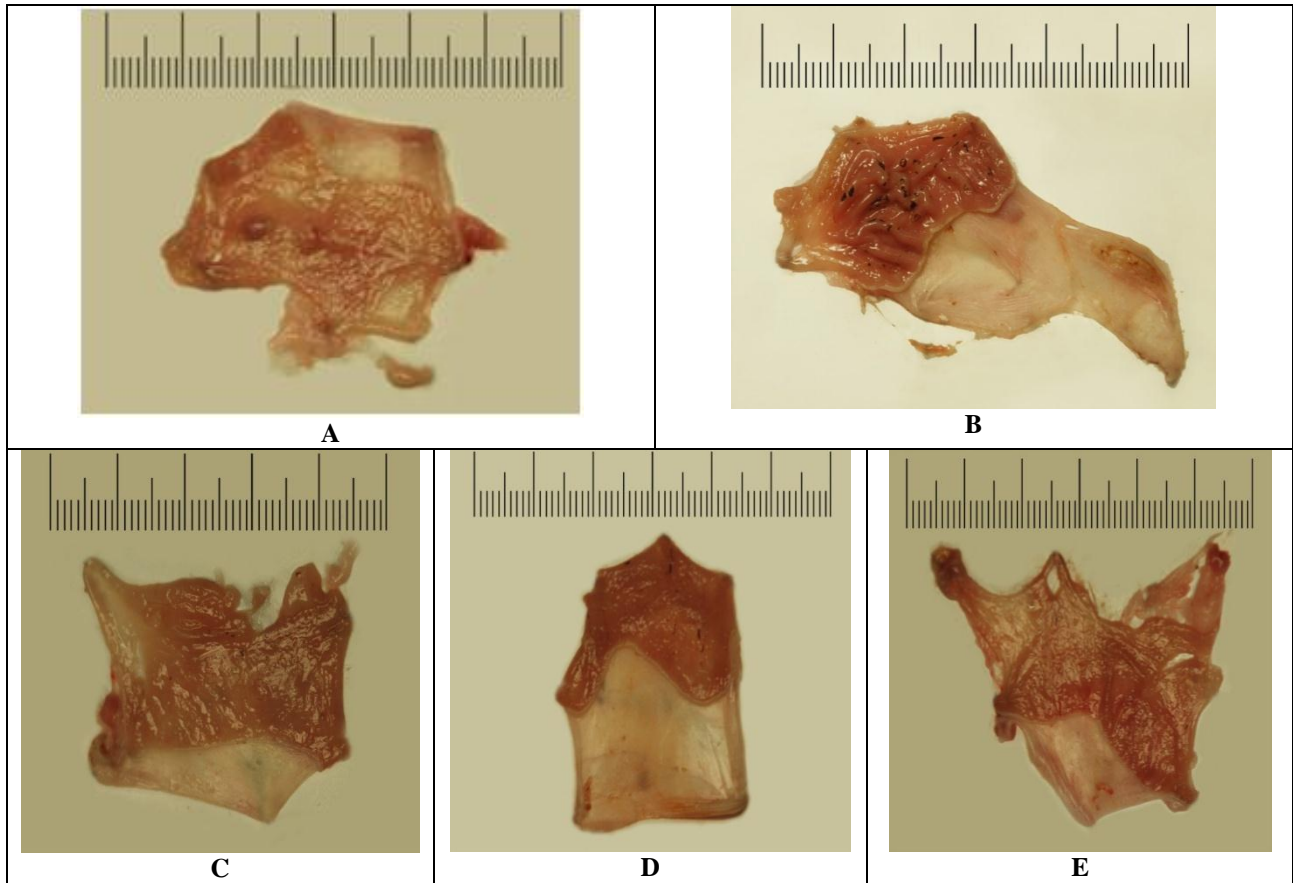


Figure 1: The gross appearance of rat stomachs (a) Macroscopic appearance of the gastric mucosa in healthy rats [Control (-ve)], (b) ulcerated rats [Control (+ve)], (c) RAN Protection group , (d) RCP Protection group(RCP + Indomethacin)and (e) GA Protection group (GA + Indomethacin).

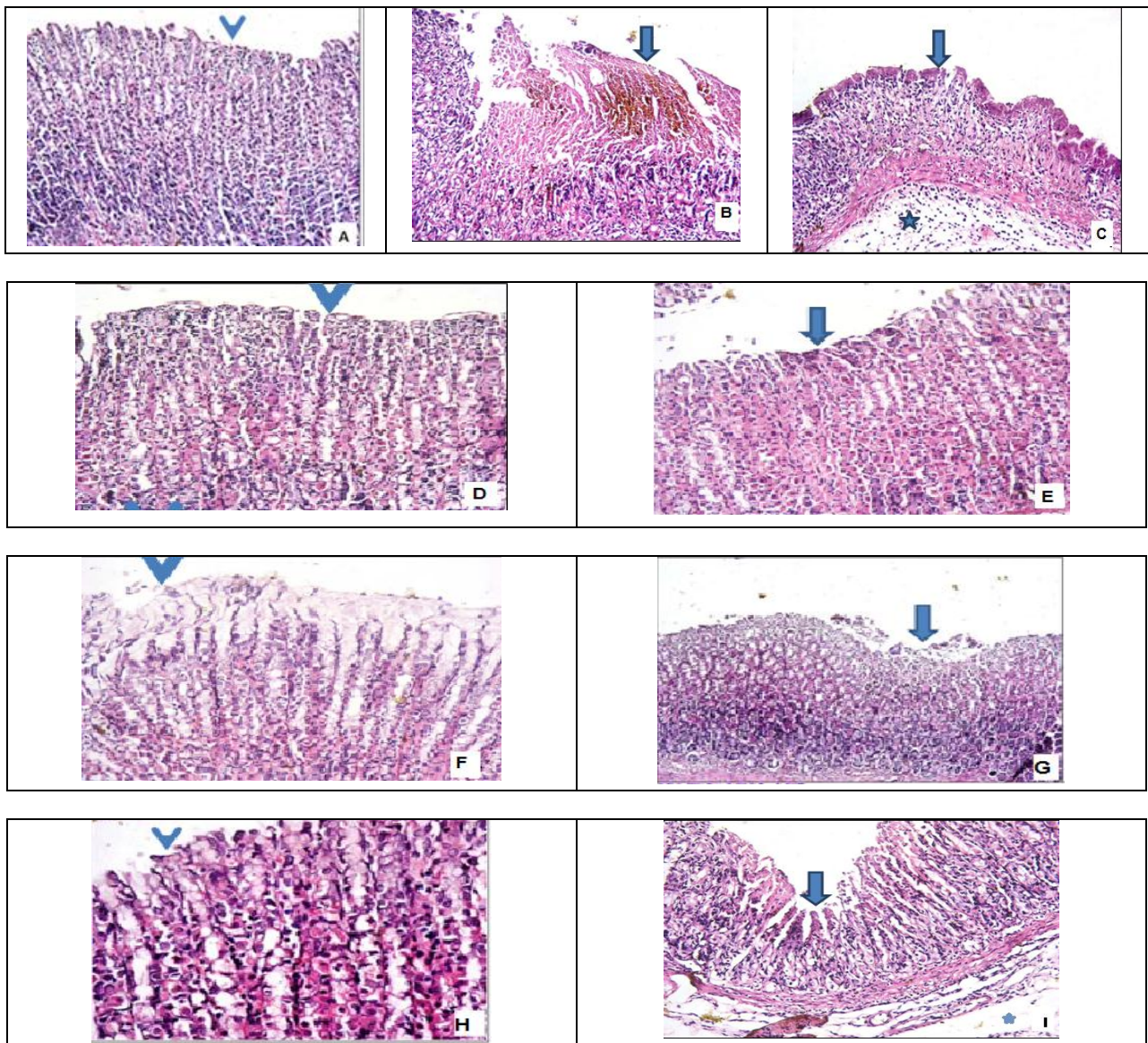


Figure 2: figures (A) Gastricmucosa of healthy rats [Control (-ve)]showing intact epithelial lining (arrow) (H&E X100)

Figures (B,C): Gastric mucosa of ulcerated rats [Control (+ve)]showing extensive epithelial ulceration covered by fibrin entangling neutrophils (arrow) involving about half of gastric mucosal thickening.The epithelium and underlying tissue are infiltrated by neutrophils and show congested blood vessels.The submucosa shows edema*(H&E X100).

Figures (D,E): Gastric mucosa of Ranitidine protected group showing intact epithelial lining (arrowhead) with focal epithelial ulceration covered by fibrin (arrow) involving less thanone third of gastric mucosal thickening.Few congested blood vessels are also seen.(H&E X100).

Figures (F,G): Gastric mucosa of Chilli pepper protected group showing intact epithelial lining with excess mucus secretion (arrowhead) with focal epithelial ulceration covered by fibrin (arrow) involving about one third of gastric mucosal thickening. Few congested blood vessels are also seen.(H&E , F X100, G:X40).

Figures (H,I): Gastric mucosa of Garlic protected group showing intact epithelial lining (arrowhead) with focal epithelial ulceration covered by fibrin entangling neutrophils (arrow) involving about one third of gastric mucosal thickening. Edema, inflammatory cells and congested blood vessels are also seen in the submucosa*(.H&E, HX100, IX40).

DISCUSSION

Chronic administration of non-steroidal anti-inflammatory drugs (NSAIDs) such as indomethacin, during the course of anti-inflammatory therapy, is often associated with the development of adverse

gastrointestinal disorders such as gastric erosions, gastric or duodenal ulceration and other severe complications such as gastrointestinal haemorrhage or perforation that often limited their wide spread clinical use.^[50] With the inherent adverse side effects and considerably high cost

of synthetic drugs, exploiting natural products of plant source which are believed to be non-toxic, efficacious and affordable will be most appropriate in the treatment of gastric ulcer.

In this study, we have evaluated the gastroprotective effects of juices of red pepper and garlic bulb against indomethacin-induced gastric ulcer in rats.

Biochemical analysis of gastric secretions (for pH, gastric volume, bicarbonate, pepsin) and mucosal integrity for stomach is usually employed to ascertain its status following exposure to pharmacological agents.^[51] The pH gives an idea of the level of acidity and volume of gastric secretions. Low pH value is a manifestation of decreased hydrogen ion concentration in gastric juice. This has been linked to pathogenesis of ulcer and gastric damage in experimental animals.^[52] Inas *et al.*^[53] have also attributed gastrointestinal injury to eroded mucin content. This erosion is facilitated by onslaughts of both internal (pepsin and oxidants produced in the gastric lumen) and external (drugs and chemicals) aggressive agents on mucosal epithelia.

In the present study, the significant increase in ulcer index and gastric volume following oral administration of indomethacin in the ulcerated rats may be attributed to either free radicals formation or inhibition of prostaglandin synthesis. Decreased prostaglandin level has been attributed to impaired gastro protection and increased gastric acid secretion which are important events in the etiology of mucosal ulceration. This agrees with the reports of Bech *et al.*,^[54] Biplab *et al.*^[51] and Muhammed *et al.*^[55] where indomethacin was reported to have caused alterations in gastric secretions of rats. Conversely, pretreatments with the two test plants significantly reduced these parameters. In fact the effects noticed for pH compared favorably well with both normal control and standard drug used in this study and indeed suggestive of their possible gastroprotective attributes.

A combination of events including release of preformed mucus, wound retraction and re-epithelialization is involved in ulcer-healing process after toxicological injury.^[56,57] Besides providing significant buffering capacity for the neutralization of luminal acid, the mucus also offers protection against both endogenous aggressors and exogenous gastro toxic agents such as indomethacin, thereby enhancing the rate of local healing process.^[58] In this study, the increased pepsin activity coupled with decrease in mucin secretion in the indomethacin-ulcerated rats reduced protective ability of the mucosal membrane against hemorrhage, thus, resulting in tissue damage. This implied decreased ability of the gastric mucosa to withstand the offensive onslaught of indomethacin. Besides antioxidant action that protects the mucus layer and arrests ulcer progression, drugs that increase the synthesis and secretion of gastric mucus would accelerate gastric ulcer

healing. Pretreatment with the two test plants however, facilitated ulcer healing process, which is associated with decreased pepsin activity and elevated mucin level in the gastric mucosa. This in turn has encouraged speedy wound healing of the ulcerated areas of the mucosal epithelia and shielded the gastric membrane, thus abrogating the catastrophic influence of indomethacin in the ulcerated rats.^[56] This is indicative of enhanced mucus secretory potential of the red pepper and garlic and suggestive of their significant role in ulcer healing process.

Previous epidemiological and clinical data suggested that chilli ingestion may have a beneficial effect on human peptic ulcer disease. Increased gastric mucus production has been suggested as one mechanism by which capsaicin and chilli exert their gastroprotective effect, and reduction in mucosal mucus depletion which has been found to act as secondary protective effect of capsaicin and chillis.^[59]

Cells or tissues are in a stable state if the rates of free radical formation and scavenging capacity are essentially constant and in equilibrium. However, an imbalance between them results in oxidative stress which further deregulates cellular functions leading to different pathological conditions.^[60] In the present study, the increased concentration of MDA as well as reduced activities of SOD and CAT with depletion NP-SH levels in the stomach of indomethacin-ulcerated rats is a manifestation of facilitated lipid peroxidation and over production of free radicals resulting in mucosal damage. Free radicals thwart antioxidant enzymes activities and initiate lipid peroxidation which is an important event in the toxicity mechanism of indomethacin.^[61] Indomethacin has previously been reported to decrease antioxidant enzymes (SOD, CAT and GST) activity in rat stomach thereby inducing gastric ulceration.^[62] This is associated with over powering of the cellular antioxidant defense systems by free radicals ravaging influence that subsequently results in stomach oxidative injury. Pretreatment of rats with fresh juices of red pepper and garlic bulb resulted in a significant depletion of the indomethacin induced MDA levels and restoration of the decreased NP-SH levels of the gastric tissue. Nonprotein sulfhydryl are endogenous antioxidants and protect the cells by different mechanisms, primarily by limiting the production of free radicals.^[51] Secondly, they protect the mucus by strengthening the disulfide bridges of its subunits. A decrease in these bridges reduces the mucus thickness and makes it more vulnerable to harmful agents.^[54] Changes in the SH levels may be crucial for ulcer formation, given that they help in the preservation of mucosal integrity, and their reduced levels in the gastric mucosa result in the formation of gastric ulcers.^[53] However, the significantly reduced concentrations of MDA coupled with marked increase in the NP-SH levels and activity of SOD and CAT in rats pretreated with fresh juices of both plants is an obvious

indication of antiperoxidative potential and thus antioxidative potential.

One of the mechanisms by which NSAIDs damages the gastric mucosa is the increased production of TNO due to the over expression of inducible nitric oxide synthetase(iNOS).^[63] TNO is a mediator not only of gastrointestinal mucosal defense, but also of its damage. It has been shown that different concentrations of TNO have completely opposite effects in the same tissue. In general, the mucosal and endothelial NOS isoforms produce low amounts of NO. However, the high quantity of NO produced by iNOS damages the epithelium.^[7] The excessive release of NO from gastric epithelial cells induced by NSAIDs has been reported to exert detrimental effects.^[64,65] Inhibiting indomethacin induced increases in iNOS expression in the gastric mucosa leads to a reduction in gastric mucosal damage.^[8] In the present study, fresh juices of red Pepper and garlic bulb reduced TNO content and inhibited the production of gastric ulcers, even in the presence of indomethacin.

Indomethacin is known to induce gastric ulcer by inhibition of prostaglandins which are cytoprotective to gastric mucosa,^[6] particularly due to the inhibition of cyclooxygenase pathway of arachidonic acid metabolism resulting in excessive production of leukotrienes and other products of 5-lipoxygenase pathway.^[50,66] In the stomach, prostaglandins play a vital protective role, stimulating the secretion of bicarbonate and mucus, maintaining mucosal blood flow, and regulating mucosal cell turnover and repair.^[67] Thus, the suppression of prostaglandins synthesis by indomethacin results in increased susceptibility to mucosal injury and gastric ulceration. Several studies have indicated that gastric protection by prostaglandins is due to increasing the mucosal resistance as well as the decrease in aggressive factors, mainly acid and pepsin.^[6,68] In the present study, the obtained data were in parallel line with these previous data, indomethacin significantly reduced gastric mucosal prostaglandin E2 (PGE2) level and gastric cyto P₄₅₀ reductase activity while elevated COX-2 activity compared to control(-ve). Pretreatment with red Pepper and garlic bulb juices significantly inversed these results when compared to indomethacin treated rats. This finding observed antiulcerogenic property of the Phytochemical contents of red Pepper and garlic on inhibit gastric ulcer.

A review of antiulcer drugs of plant origin shows that Capsaicin content of red peppers (because their ability to strengthen defensive factors such as stimulation of mucous synthesis or maintenance of the prostaglandins content of gastric mucosa at high levels) are potentially the compounds with antiulcer activity.^[26,57]

Inflammation and neutrophil infiltration are also important in the pathogenesis of the gastric damage induced by NSAIDs.^[69] The inflammation induced in the gastric mucosa by indomethacin is accompanied by

increased TNF- α production, which augments neutrophil-derived superoxide generation and stimulates IL-1 production, leading to neutrophil accumulation.^[15] Over production of TNF- α increases the risk of gastric ulcer and cancer.^[70] In the present study, the levels of TNF- α and IL-1 were increased by indomethacin administration, and the co-administration of fresh juices of red Pepper and garlic bulb inhibited the increases in TNF- α and IL-1 without ulcer formation progressing.

Histopathological studies on the gastric mucosa revealed that indomethacin administration induced a mucosal ulceration, associated with significant increase in lipid peroxidation. This was manifested as lamina epithelial necrosis, blood vessels congestion, and leukocytic infiltration. This effect on mucosal oxidative stress and histological derangement was in accordance with the reports of Valcheva-Kuzmanova *et al.*^[71] and El-Moselhy *et al.*^[72]

Furthermore, the development of the gastric mucosal lesions induced by indomethacin may also be mediated through generation of oxygen free radicals.^[73] Cellular infiltration was observed in the connective tissue corium of the basal part of the fundic mucosa in the indomethacin-treated group. This may be attributed to the neutrophil-endothelial cell interactions as a cause of gastric injury in this group. Also in the previous group, the fundic glands were dilated. This glandular dilatation might be an indication of hyper secretion, which might be related to inhibition of prostaglandin E2, a potent anti-secretory agent.^[74]

The present study revealed that, oral administration of indomethacin (40mg/kg b.wt.) induced gastric ulcer in rats; the mean length of gastric ulcer in control +ve group 2 was higher compared with in control -ve group 1. Oral administration of RCP extract at a dose of 8ml/kg b.wt., caused high decrease in the length of gastric ulcer. These results were in agreement with Kang *et al.*,^[75] who reported that chilli (*Capsicum frutescens*) may be expected to accelerate gastro-intestinal transit and hence to inhibit colonic carcinogenesis, while its active ingredient capsaicin protects against experimental gastric mucosal injury. Also, Yeoh *et al.*,^[59] found that capsaicin, the pungent ingredient of chilli, has a gastro-protective effect against experimental gastric mucosal injury in animals. Such an effect has not, however, been documented in humans to date, demonstrating a gastro-protective effect of chilli in humans subjects. In this respect, Shobana and Naidu^[76] reported that pepper has anti-oxidative activity, this can be applied for stomach preservation against ulcer and spices when included pepper in addition to impart flavor to the food, they possessed potential health benefits. Credence for this speech, Bombiket *et al.*,^[77] concluded that the extracts of some herbs including chamomile increased the concentration of zinc, copper and iron in blood serum which was helpful for the flowing of blood to the stomach mucosa causing treatment of the pain; according

to this action, these herbs were useful for healing of gastric ulcer. It has been shown that drugs such as indomethacin damage gastric mucosa by decreasing blood flow. It is known that hemorrhage, erosion and ulcers develop as a result of the decrease in mucosal blood flow. The best known vascular reaction in response to mucosal damage is hyperemia against irritant substances.^[7]

Generally, the protection offered by the fresh juices of red Pepper and garlic bulb against indomethacin-induced gastric ulceration may be linked to their beneficial medicinal attributes occasioned by phytometabolite constituents. These include ability to scavenge free radicals and regulate mucosal membrane permeability thereby countering the effect of indomethacin on gastric acid secretion. This is in agreement with the submissions of Yun *et al.*^[25] and Abdul Jawad *et al.*^[26] where gastroprotective potentials of test plant juices against NSAIDs-ulcerated rats were associated with their capsaicin and organosulfur compounds and other various bioactive principles. Since ranitidine is a proton pump inhibitor, then the effect produced by the two juices might have perhaps mimic its mechanism of action by modulating cells in the mucosal lining of the stomach against excess acid secretion.^[22,74]

CONCLUSION

Conclusion, overall, the attenuation of gastric affronts of indomethacin by administration of fresh juices of red Pepper and garlic bulb regimen is indicative of their excellent gastroprotective and antioxidative potentials in rats. Efforts are ongoing to investigate the exact antiulcerogenic principles in these test plants and also harness their possible synergistic efficacy against gastric ulcer.

REFERENCES

1. Khazaei M., Salehi H., Protective effect of *Falcaria vulgaris* extract on ethanol induced gastric ulcer in rat. *Iranian J Pharmacol Ther*, 2006; 5: 1–4.
2. Belaiche, J; Burette, A; De vos, M; Louis, E; Huybrechts, M; Deltenre, M; Belgian Study Group of NSAID-GI Complications Observational survey of NSAID related upper gastro-intestinal adverse events in Belgium *Acta gastro-enterologica Belgica* . 2002; 65: 65-73.
3. Laine, L., Takeuchi K. and Tarnawski A., Gastric mucosal defense and cytoprotection. *J. Gastroenterology*. 2008;135: 41-60.
4. Allen, A; Flemström, G; Garner, A; Kivilaakso, E . Gastro duodenal mucosal protection. *Physiological Reviews*, 1993; 73: 823-857.
5. Wang, G., G. Huang, G. Yin, G. Zhou, C. Guo and C. Xie., Aspirin can elicit the recurrence of gastric ulcer induced with acetic acid in rats. *Cell Physiol. Biochem.*, 2007; 20: 205-212.
6. Wallace, J., Prostaglandin, NSAIDs and gastric mucosal protection. *Physiol. Rev.* 2008; 88: 1547-1565.
7. Wallace, J., M. Miller and C. Keenan, Nitric oxide in mucosal defense: a little goes a long way. *Gastroenterology*, 2000; 119: 512-520.
8. Mari, H., N. Riina, V. Pia, H. Marina and M. Eeva, Anti-inflammatory effects of flavonoids inhibit iNOS expression and NO production in activated macrophages. *Mediators of Inflammation*, Article 2007; ID 45673: 1-10.
9. Akah P.A., Orisakwe O.E., Gamanies K.S., Shittu A., Evaluation of Nigerian traditional medicines: 11. Effects of some Nigerian folk remedies on peptic ulcer, *J Ethnopharmacol* 1998; 62(2): 123–127.
10. Hawkins C., Hanks G.W., The gastro duodenal toxicity of nonsteroidal anti-inflammatory drugs. A review of the literature, *J Pain Symptom Manage*, 2000; 20 (2) : 140–151.
11. Mota, K.S., Dias, G.E., Pinto, M.E., Luiz-Ferreira, A., Souza-Brito, A.R., Hiruma-Lima, C.A., Barbosa-Filho, J.M., Batista, L.M., Flavonoids with gastroprotective activity. *Molecules* 2009; 14: 979–1012.
12. Darbar, S., Antiulcer effect of livina, a herbal formulation against ethanol induced acute gastric ulcer in mice. *IJPRD*, 2010; 2(10): 0974-9446.
13. Samuel, A., O. Benjamin, A. Austin and O. Taiwo., Anti-ulcer and ulcer healing potentials of *Musa sapientum* peel extract in the laboratory rodents *Pharmacognosy Res.*, 2013; 5(3): 173-178.
14. Meghvansi M. K., Siddiqui S., Khan M. H., “Nagachilli: a potential source of capsaicinoids with broad-spectrum ethno pharmacological applications,” *Journal of Ethno pharmacology*, 2010; 132(1): 1–14.
15. Zimmer A. R., Leonardi B., Miron D., Schapoval E., Oliveira J.R., and Gosmann G., “Antioxidant and anti-inflammatory properties of *Capsicum baccatum*: from traditional use to scientific approach,” *Journal of Ethno pharmacology*, 2012; 139(1): 228–233.
16. Ahuja, K.D., &Ball, M.J. “Effects of daily ingestion of chillis on serum lipoprotein oxidation in adult men and women”. *Br J Nutr.*, 2006; 96(2): 239-242.
17. Barbanti, G., Maggi, C.A., Beneforti, P. Baroldi, P.&Turini, D.. “Relief of pain following intravesical capsaicin in patients with hypersensitive disorders of the lower urinary tract”, *Br J Urol*, 1993; 71: 686–91.
18. Bortolotti, M., Coccia, G., Grossi, G. &Miglioli, M., “The treatment of functional dyspepsia with red pepper”, *Aliment Pharmacol Ther.*, (2002-a); 16(6): 1075-1082.
19. Bortolotti, M., Coccia, G. &Grossi, G. “Red pepper and functional dyspepsia”, *N Engl J Med.*, (2002-b); 346(12): 947-948.
20. Alevizos, A., Mihas, C., Mariolis, A. &Larios, G. “Insulin secretion and capsaicin”, *Am J Clin Nutr.*, (2007) ; 85(4):1165-1166.
21. EI- Bayoumy K, Sinha R, Pinto JT, Rivlin RS. Cancer chemoprevention by garlic and garlic-containing sulphur and selenium compounds. *J Nutr* 2006; Mar; 136(3): 864S-69S.

22. Santhosha SG, Jamuna P, Prabhavathi SN. Bioactive components of garlic and their physiological role in health maintenance: A review. *Food Bioscience*, 2013; 3: 59-74.
23. Milner JA. Preclinical perspectives on garlic and cancer. *J Nutr*. 2006; Mar; 136(3): 827S-31S.
24. Yi L, Su Q. Molecular mechanisms for the anticancer effects of diallyl disulfide. *Food and Chemical Toxicology*, 2013; 57: 362–370.
25. Yun H, Bana JO, Park K, Lee CK, Jeong H, Han SB, Hong JT. Potential therapeutic effects of functionally active compounds isolated from garlic. *Pharmacology & Therapeutics*, 2014; 142: 183–195.
26. AbdulJawad, SohaH Hasanein, Manal A1 Header Eslam A . Influence of Aqueous Extract of Red Chillis Pepper as Curative for Gastric Ulcer in Albino Rats. *Journal of Natural Sciences Research*, 2013; 3: 78-88.
27. Mohammed Azamthulla, Mohammed Asad, and V. Satya Prasad. Antiulcer activity of allium sativum blub juice in rats. *Saudi Pharmaceutical Journal*, 2009; 17: 70-77.
28. Khosla P, Karan RS, Bhargava VK. Effect of garlic oil on ethanol induced gastric ulcer in rats. *Phytother Res* 2004 Jan; 18(1): 87-91.
29. Vasudevan, K., Vembar, S., Veeraraghavan, K. & Haranth, P.S. "Influence of intra-gastric perfusion of aqueous spice extracts on acid secretion in anesthetized albino rats", *Indian J. of Gastroenterol.*, 2000; 19(2): 53-56.
30. Ononiwu, I.M., Ibeneme, C.E. & Ebong, O.O. "Effect of Piperine on gastric acid secretion in albino rats", *Afr. J. of Med. Sci.*, 2002; 31(4): 293-295.
31. Hoshino.T, Kashimoto.N, Kasuga.S. Effects of garlic preparations on the gastrointestinal mucosa. *J Nutr* 2001; 131: 1109S-13S.
32. Williamson E, Okpako D, Evans F, *Pharmacological Methods in Phytotherapy Research*, John Wiley and Sons Ltd., Chichester., 1986; 25-45.
33. Hitesh K.R., Harish C.H. Verma, Ramesh K.R. Gupta. Antiulcer potential of ethyl cellulose floating microspheres containing Ranitidine hydrochloride in experimental rodents. *Asian J Pharm Clin Res*, 2012; 5(3): 205-209.
34. Parmar, N. and J. Desai, A review of the current methodology for the evaluation of gastric and duodenal antiulcer agents. *Indian J. Pharmacol.*, 1993; 25: 120-135.
35. A.R. Sanyal, O.K. Denath, S.K. Bhattacharya, K.D. Gode, The effect of cyproheptadine on gastric acidity, in: C.J. Pfeiffer (Ed.), *Peptic ulcer*, Scandinavian University Books, Munksgaard, 1971; 312–318.
36. S.J. Corne, S.M. Morrissey, R.J. Woods, *Proceedings: a method for the quantitative estimation of gastric barrier mucus*, *J Physiol*. 1974; 242(2): 116–117.
37. Anson ML. The estimation of pepsin, trypsin and catepsin with haemoglobin. *J General Physiol*. 1983; 22: 78–9.
38. Hemler, M. and W. Lands, Purification of the cyclooxygenase that forms prostaglandins: Demonstration of two forms of iron in the holo enzyme. *J. Biol. Chem.*, 1976; 251: 5575-5579.
39. Hamberg, M. and B. Samuelsson, Detection and isolation of an endo peroxide intermediate in prostaglandin biosynthesis. *Proc. Nat. Acad. Sci. USA*, 1973; 70: 899-903.
40. Mc-Lean, A. and P. Day, The use of new methods to measure: The effect of diet and inducers of microsomal enzyme synthesis on cytochrome P₄₅₀ in liver homogenates and on metabolism of dimethylnitrosamine. *Biochem. Pharm.*, 1974; 23: 1173-1180.
41. Griess, L., D. Wagner, J. Glogowski, P. Skipper, J. Wishnok and S. Tannenbaum, Analysis of nitrate, nitrite and [15 N] nitrate in biological fluids. *Anal. Biochem.*, 1982; 126(1): 131-138.
42. Nishikimi M, Roa NA, Yogi K. Measurement of superoxide dismutase. *Biochem. Biophys. Res. Commun*, 1972; 46: 449–454.
43. Aebi, H. Catalase. In: Bergmeyer, H. ed. *Methods in enzymatic Analysis*. vol. 3, New York, Academic Press, 1983; 276-286.
44. Sedlak J, Lindsay RH. Estimation of total protein bound and nonprotein sulfhydryl groups in tissue with Ellman's reagent. *Anal Biochem* 1968; 25: 192-5.
45. Satoh K. Lipid peroxide in cerebro vascular disorders determined by a new colorimetric method. *Clin Chim Acta*, 1978; 90(1): 37–43.
46. Grassi, J., C. Roberge and Y. Frobert, 45. Jainu, M. and C. Devi, 2006. Gastroprotective action Determination of IL-1, IL-1 and IL-2 in biological media using specific enzyme immunometric assay. *Immunol. Res.*, 1991; 119: 125-145.
47. Beutler, B., D. Greenwald and J. Hulmes, Identity of tumor necrosis factor and the macrophage secreted factor cachectin. *Nature*, 1985; 316: 552-554.
48. Murakami, S; Arai, I; Muramatsu, M; Otomo, S; Baba, K; Kido, T; Kozawa, M Inhibition of gastric H⁺, K⁺- ATPase and acid secretion by cassigalol A, a polyphenols from *Cassia garrettiana* Craib. *Biochemical Pharmacology* 1992; 44: 33-37.
49. Bancroft, J.D. and M. Gamble, 2008. *Theory and Practice of Histological Techniques*. 6th ed., (Churchill Livingstone, Elsevier, Philadelphia).
50. Villegas, I; La Casa, C; De La Lastra, C A; Motilva, V; Herrerias, J M; Martin, M J Mucosal damage induced by preferential COX-1 and COX-2 inhibitors: role of prostaglandins and inflammatory response. *Life Sciences* 2004; 74: 873-884.
51. A. Biplab, K.Y. Sudhir, R. Kshama, K.B. Sandip, C. Subrata, Black tea and the flavonoids assist healing of indomethacin-induced gastric ulceration in mice by antioxidative action, *Evid Based Complement Alt Med*. 2011; (11): 11–22.

52. H. Lüllmann, K. Mohr, A. Ziegler, D. Bieger, Color atlas of pharmacology, 2nd ed., Thieme Stuttgart, New York, 2000; pp. 166.
53. Inas Z.A., A.H. Abdallah-Hala, H. Khattab, H.H. Gehan, Gastroprotective effect of *Cordiamyxa* L. fruit extract against indomethacin-induced gastric ulceration in rats, *Life Sci J*, 2011; 8(3): 433–445.
54. Bech P.L, Xavier R., Lu N., Nanda N.N., Dinauer M., Podolsky D.K., Mechanisms of NSAID-induced gastrointestinal injury defined using mutant mice, *Gastroenterology*, 2000; 119(3): 699–705.
55. Muhammed A.V.K., Thamocharan G., Sengottuvelu S., Haja-Sherief S., Sivakumar T., Evaluation of antiulcer activity of *Ficus pumila* L. leaf extract in albino rats, *Glob J Res Med Plants Indig Med* 2012; 1(8): 340–351.
56. Naito Y., Yoshikawa T., Matsuyama K. a, Yagi N., Arai M., Nakamura Y., Effects of oxygen radical scavengers on the quality of gastric ulcer healing in rats, *J Clin Gastroenterol*, 1995; 21(1): 82–86.
57. Luo Xiu-Ju, Liu Bin, Dai Zhong, Yang Zhi-Chun, Peng Jun. Stimulation of calcitonin gene-related peptide release through targeting capsaicin receptor: a potential strategy for gastric mucosal protection. *Dig Dis Sci.*, 2013; 58: 320-325
58. Alanko J., A. Riutta, P. Holm, I. Mucha, H. Vapatalo, T. Metsä-Ketela, Modulation of arachidonic acid metabolism by phenols: relation to their structure and antioxidant/prooxidant properties, *Free Radic Biol Med*, 1999; 26(1–2): 193–201.
59. Yeoh, K.G., Kang, J.Y. Yap, I., Guan, R., Tan, C.C., Wee, A. & Teng, C.H. “Chilli protects against aspirin-induced gastro-duodenal mucosal injury in humans”, Singapore, *J. of Dig. Dis. Sci.*, 1995; 40(3): 580-583.
60. Sabiu S., A.M. Wudil, T.O. Sunmonu, Combined administration of *Telfaira occidentalis* and *Vernonia amygdalina* leaf powders ameliorates garlic-induced hepatotoxicity in Wistar rats, *Pharmacologia* 2014; 5(5): 191–198.
61. Halici M., F. Odabasoglu, H. Suleyman, A. Cakir, A. Aslam, Y. Bayir, Effect of water extract of *Usnealongissima* on antioxidant enzyme activity and mucosal damage caused by indomethacin in rats, *Phytomedicine*, 2005; (12): 656–662.
62. Odabasoglu F., A. Cakir, H. Suleyman, A. Aslam, Y. Bayir, M. Halici, Gastro protective and antioxidant effects of usnic acid on indomethacin induced gastric ulcer in rats, *J Ethno Pharmacol.* 2006; (103): 59–65.
63. Konturek, P., J. Kania, E. Hahn and J. Konturek, Ascorbic acid attenuates aspirin-induced gastric damage: role of inducible nitric oxide synthase. *J. Physiol. Pharmacol.*, 2006; 57: 125-136.
64. Whittle, B., Gastrointestinal effects of nonsteroidal anti-inflammatory drugs. *Fundam. Clin. Pharmacol.*, 2003; (7): 301-313.
65. Hsu, D. and M. Liu, Involvement of nitric oxide in gastric protection of epinephrine in endotoxin intoxication in rats. *Toxicology*, 2004; (204): 203-208.
66. Takeuchi K. Gastric cytoprotection by prostaglandin E2 and prostacyclin: relationship to EP1 and IP receptors. *J Pharmacol.*, 2014; (65): 3-14.
67. Hiruma-Lima, C., T. Calvo, C. Rodriguez, F. Andrade, W. Vilegas and Brito, Antiulcerogenic activity of *Alchorneacastaneaefolia*: effects on somatostatin, gastrin and prostaglandin. *J. Ethno pharmacol.*, 2006; 104(1-2): 215-224.
68. Ericson, A., Nur, E.M. Petersson, F. & Kechagias, S. “The effects of capsaicin on gastrin secretion in isolated human antral glands: before and after ingestion of red chilli”, *Dig Dis Sci.*, 2009; 54(3): 491-498.
69. Odashima, M., M. Otaka, M. Jin, K. Komatsu, I. Wada and Y. Horikawa, Attenuation of gastric mucosal inflammation induced by aspirin through activation of A2A adenosine receptor in rats. *World J. Gastroenterology*, 2006; (12): 568-573.
70. Jainu, M. and C. Devi, Gastroprotective action of *Cissus quadrangularis* extract against NSAID induced gastric ulcer: role of pro inflammatory cytokines and oxidative damage. *Chem. Biol. Interact.*, 2006; 161: 262-270.
71. Valcheva-Kuzmanova, S., Krasnaliev, I., Galunska, B. and Belcheva, A. Influence of DL-alpha-tocopherol acetate on indomethacin-induced gastric mucosal injury in rats. *Auton. Autacoid Pharmacol.*, 2007; 27(3): 131-136.
72. EL-Moselhy, M.A., Abdel-Hamid, N.M. and Abdel-Raheim, S.R. Gastroprotective effect of nicorandil in indomethacin and alcohol-induced acute ulcers. *Appl. Biochem. Biotechnol.*, 2009; 152(3): 449-459.
73. Kim JH, Kim BW, Kwon HJ, Nam SW. Curative effect of selenium against indomethacin-induced gastric ulcers in rats. *J Microbiol Biotechnol* 2011; 21: 400-404.
74. Ng CJ, Chen JC, Chiu DF, Chen MF, Chen HM. Role of prostacyclin on microcirculation in endotoxin-induced gastroprotection in rats: a microdialysis study. *Shock* 2002; 17: 334-38.
75. J.Y. Kang, B. Alexander, F. Barker, W.K. Man and R.C. Williamson, The effect of chilli ingestion on gastro-intestinal mucosal proliferation and azoxymethan - induced cancer in rats, London, *J. of Gastro-Enterol. Hepatol.*, 1992; 7(2): 194-198.
76. S. Shobana and K.A. Naidu, Anti-oxidant activity of selected Indian spices, *Indian J. of Prostaglandins Leukot. Essent. Fatty Acids.*, 2000; 62(2): 107-110.
77. E. Bombik, T. Bombik and L. Saba, The effect of herb extracts on the level of selected microelements in blood serum of calves, *J. of Biuletyn. Informacyjny. Instytut Zootechniki.*, 2002; 40(2): 279-285.