

PLACENTAL CHORANGIOSIS: THE ASSOCIATION WITH NEONATAL MORBIDITY
AND MORTALITY¹*Amulyajit Kaur, ²Dr. Kanwaljeet Singh Hura, ³Akanxa Bhatti, ⁴Dr. Neeraj Kaur¹Associate Professor, Department of Pathology, Command Hospital(WC), Chandimandir, Panchkula, Haryana 134107.²Assistant Professor, Department of Pediatrics, Pt. JNM Medical College, Raipur, CG 492001.³Medical Student, MBBS, MGM College, Navi Mumbai.⁴Assistant Professor, Department of Radiology, All India Institute of Medical Sciences (AIIMS) Raipur CG.***Correspondence for Author: Dr. Amulyajit Kaur**

Associate Professor, Department of Pathology, Command Hospital(WC), Chandimandir, Panchkula, Haryana 134107.

Article Received on 22/12/2015

Article Revised on 13/01/2016

Article Accepted on 03/02/2016

ABSTRACT

Aim: Chorangiomas and related placental vascular lesions (the entire spectrum being referred to as chorangiomas) have not been extensively studied and chorangiomas especially has been consistently underreported. This study aims to highlight the association of these vascular lesions with neonatal mortality and morbidity. **Material and methods:** Three hundred and forty seven consecutive placentas from abnormal maternal, fetal or neonatal outcomes received in a tertiary care hospital were studied with special emphasis on chorangiomas lesions as per defined criteria. Association with neonatal death, prematurity, pregnancy induced hypertension, placental ischemia and hypoxia was studied. **Results:** Among the 347 placentas received in a tertiary care hospital, 16 had evidence of chorangiomas. Overall incidence of chorangiomas in these cases was 4.6% and 43.7% of these cases were associated with a fatal outcome. This study shows a strong positive association of chorangiomas lesions with neonatal death, prematurity, pregnancy induced hypertension, placental ischemia and hypoxia. This underlines the significance of chorangiomas and related placental vascular lesions as signs of neonatal morbidity and mortality. The interplay of maternal, fetal and placental factors may combine to produce this pathologically distinct entity of potential clinical significance.

KEYWORDS: Placental chorangiomas, neonatal mortality, morbidity.**INTRODUCTION**

Chorangiomas, a significant placental sign of neonatal morbidity and mortality remains an enigma in the minds of pathologists and gynecologists, as very few studies have been conducted on the subject and the possibility of ignoring this pathology in routine pathology practice remains.^[1] Studies have revealed that premature and low birth weight infants usually have abnormal placentas.^[2,3] Hence, it is necessary to appreciate the clinicopathological implications of placental abnormalities. With better chances of survival of low birth weight, premature and seriously ill newborns today, our endeavour is to identify and study placental pathological changes which may be of potential clinical significance. In this study we have correlated maternal, fetal and placental factors with chorangiomas changes seen in the placentas.

MATERIALS AND METHODS

The placentas from poor maternal/neonatal/ fetal outcomes received at this tertiary care referral center between Jan 2010 and August 2014 were examined. Various maternal, fetal and placental data were obtained to unravel or associate these with chorangiomas. An ELISA TORCH (Toxoplasmosis, rubella,

cytomegalovirus and Herpes Simplex type 2) test was also done as an antenatal investigation in all these cases. The method of examination and processing were essentially those mentioned by Salafia CM and Popek EJ.^[4] The placentas received were fixed in 10 % formaldehyde, weighed after removal of blood clots, membranes and the umbilical cord. A minimum of six blocks were processed. One block included sections of umbilical cord and placental membranes; the other blocks were taken from the central, lateral, superficial and basal zones of placentas and any other suspicious areas. After processing and haematoxylin and eosin staining, the sections were subjected to histopathological scrutiny. The diagnostic criteria of chorangiomas were suggested by Altshuler in 1984.^[5] Our study was based on these criteria. A diagnosis of chorangiomas was made when on microscopic examination, with 10x objective, 10 villi, each with ten or more vascular channels were present in ten or more non infarcted areas of at least three different placental areas. These cases of chorangiomas were further divided into low or high grade chorangiomas change. A high grade chorangiomas change was assigned if more than 50% villi showed more than 15 vessels per villus and this change was present in 50 % or more of the placental sections examined.

Normal chorionic villi should contain no more than 5 vascular channels even when the same vessel is present in more than one plane of the section.^[6] Chorangiomas was differentiated from congestion in which the vessels were numerically normal and from tissue ischemia in which shrinkage of villi is discerned. The statistical analysis were done using graph pad prism. The percentage and frequency were calculated for all qualitative variable. The mean were calculated for quantitative variables.

RESULTS

A total number of 347 placentas were examined. Sixteen had chorangiomas. Amongst these, one was a case of multinodular chorangiomas. The average gestation period was of 37 weeks. Four (25%) cases had premature delivery with gestational ages between 28 and 30 weeks. Two of these cases had completed 40 weeks of gestation. The case associated with multinodular chorangiomas was of 28 weeks, hailed from a high altitude area where she had been since conception of her child. At around over 27 weeks she had loss of fetal movements. She delivered a macerated still born associated with fetal hydrops at 28 weeks.

Seven of these cases (43.7%), were associated with neonatal death. Pregnancy induced hypertension and pre eclampsia were present in 31.2%. Among the seven cases of neonatal mortality two had fetal congenital anomalies and another two were cases of maternal diabetes. Congenital anomalies in one case were of bilateral renal dysplasia with pulmonary hypoplasia. Whereas the other had hypoplastic heart and hydrops fetalis. The various maternal and fetal conditions associated with chorangiomas is demonstrated in **Table 1**. Amongst the associated histopathological features, four cases had high grade chorangiomas. Included in this was the case which was from high altitude. On gross examination, this specimen of placenta showed appreciable firm red nodular areas. On histopathology, multiple chorangiomas nodules, exhibiting an exuberant leash of vascular channels were seen. (**Fig 1**). Intervening villi also showed an increase of vascular channels. Areas of mild to moderate villitis could also be appreciated. Ischemic placental changes were the most commonly seen (50%), followed by high grade chorangiomas (25%), placentomegaly (18.7%) and chorioamnionitis with & without accompanying villitis. Placental conditions which were found to be associated with chorangiomas are enlisted in **Table 2**.

Table 1: Common maternal and fetal conditions associated with chorangiomas.

Common maternal and fetal conditions	Incidence Number(n)	(%)
Neonatal death	7	(43.7%)
Prematurity	4	(25%)
Congenital Anomalies	3	(18.7%)
Pregnancy Induced Hypertension	5	(31.2%)
Maternal Diabetes mellitus	2	(12.5%)

Table 2: Common histopathological findings associated with chorangiomas

Associated placental pathology	Incidence Number (n)	(%) (Total N=16)
Ischaemic placental changes	8	(50 %)
Chorioamnionitis & villitis	3	(18.7%)
Placentomegaly (weight > 50% expected for gestation)	3	(18.7%)
High grade chorangiomas	4	(25%)

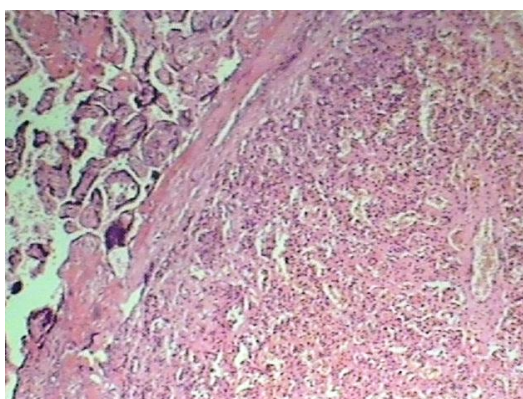


Fig 1. Photomicrograph of a chorangiomas nodule with exuberant vascular proliferation.(H&E x200)

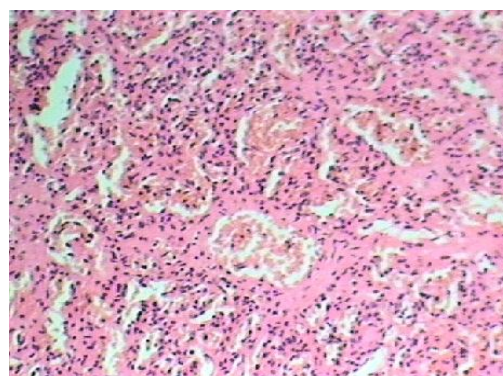


Fig 2. Photomicrograph showing chorangiomas with markedly increased number of vascular channels within the villi.(H& E x 400)

DISCUSSION

This study reveals that placental chorangiosis is associated with high neonatal morbidity, and mortality. It is also linked with pregnancy induced hypertension (PIH), and congenital anomalies. Therefore, this uncommon or underreported lesion is significant.

The association of chorangiomas lesions with high altitude, as elucidated in an earlier report highlights the link between this lesion and hypoxia.^[7-9] hypobaric hypoxia at high altitude could be the etiology. Overexpression of angiogenic cytokines such as vascular endothelial growth factor, which is known to be up-regulated by this factor in vitro, may mediate this effect. An almost similar explanation goes for its association with preeclampsia wherein placental tissue hypoxia causes villous capillary endothelial cell proliferation and capillary hypervascularity.^[10] Further, strengthening this association is the presence of ischemic changes and infarction in 50% cases.

Over three cases had a large for gestational age placenta, and two of these were known cases of uncontrolled maternal diabetes. The cases which exhibited significant degree of chorioamnionitis and villitis were found to be positive for antibodies to rubella, cytomegalovirus and Herpes simplex virus type 2. These microorganisms are well known to infect and affect the endothelial cells.^[6]

High grade chorangiosis was seen in 4 cases. The increase in the number of vessels was appreciated in most villi (definitely more than ten) in all cases beyond the defined number for chorangiomas. The numbers however varied in a range of 10-12 vessels to upto 16-18 vessels in some villi (Fig 2). The cases with chorangiomas nodules exhibited areas of maximum vascular proliferation. These observations suggest a transition from chorangiosis to chorangiomas as supported by some studies.^[10,11,12]

This study does involve a relatively small number of cases, however the clinicopathological associations is relevant. A larger spectrum of cases would make our observations more definitive. The diversity discerned in the morphological patterns of vascular proliferation maybe due to the double circulation present in this organ, however the exact etiopathogenesis remains obscure. We emphasize that a fair number of these lesions have potentially serious implications for fetal well being and affect the pregnancy outcome.

CONCLUSION

This lesion would probably be more commonly discernable and reported if kept in mind especially in high risk pregnancies and in seriously ill newborns. The rate of neonatal mortality and morbidity is alarming in developing countries. This exhorts pathologists to identify placental lesions that elucidate causes of death even if they do not directly contribute to it.

REFERENCES

1. Franciosi RA. Placental pathology casebook. Chorangiosis of the placenta increases the probability of perinatal mortality. *J Perinatol.*, 1999 Jul-Aug; 19(5): 393-4.
2. Garcia AG. Placental morphology of low-birth-weight infants born at term. *Contrib Gynecol Obstet.*, 1982; 9: 100-12.
3. Altshuler G. Role of the placenta in perinatal pathology. *Ped Pathol Lab Med.*, 1996; 16: 207-223.
4. Salafia CM, Popek EJ. Placenta . In : Damjanov I, Linder J, eds. *Anderson's Pathology* vol 2, 10th ed. St Louis Missouri : Mosby., 1996; 2310-48.
5. Altshuler G. Chorangiosis: an important placental sign of neonatal morbidity and mortality. *Arch Pathol Lab Med.*, 1984; 108: 71-74.
6. De La Ossa MM, Cabello-Inchausti B, Robinson MJ. Placental chorangiosis. *Arch Pathol Lab Med.*, 2001 Sep; 125(9):1258- 1261.
7. Reshetnikova OS, Burton GJ , Milovanov AP , Fokin EI. Increased incidence of placental chorangioma in high altitude pregnancies: hypobaric hypoxia as a possible etiologic factor. *Am J Obstet Gynecol.*, 1996 Feb; 174(2): 557-61.
8. Schwartz DA. Chorangiosis and its precursors: underdiagnosed placental indicators of chronic fetal hypoxia. *Obstet Gynecol Surv.*, 2001; 56(9): 523-525.
9. Soma H, Watanabe Y, Hata T. Chorangiosis and chorangioma in three cohorts of placentas from Nepal, Tibet, and Japan. *Reprod Fertil Dev.*, 1995; 7(6): 1533-1535.
10. Benirschke K. Recent trends in chorangiomas, especially those of multiple and recurrent chorangiomas. *Pediatr Dev Pathol.*, 1999; 2(3): 264-269.
11. Ogino S, Redline RW. Villous capillary lesions of the placenta: distinctions between chorangioma, chorangiomas and chorangiosis. *Hum Pathol.*, 2000; 31(8): 945-954.
12. Gersell DJ. Selected vascular lesions of the placenta. *Clin Lab Med.*, 1995; 15(3): 611-629.
13. Caldarella A, Buccoliero AM, Taddei GL. Chorangiosis: report of three cases and review of the literature. *Pathol Res Pract.*, 2003; 199(12): 847-850.