



**EPIDERMODYPLASIA VERRUCIFORMIS: A RARE CAESE PRESENTATION**

**Raj Kishor<sup>1</sup>, Kumar Prateek<sup>2\*</sup>, Shrenik Balegar<sup>3</sup>, Shyam Sundar Chaudhary<sup>4</sup>,  
Shweta Kumari<sup>5</sup> and Meena Rinoo Banwarilal<sup>6</sup>**

Department of Dermatology, Venereology & Leprosy, Rajendra Institute of Medical Sciences, Ranchi, Jharkhand,  
India, 834009.

**\*Corresponding Author: Kumar Prateek**

Department of Dermatology, Venereology & Leprosy, Rajendra Institute of Medical Sciences, Ranchi, Jharkhand, India, 834009.

Article Received on 19/05/2016

Article Revised on 09/06/2016

Article Accepted on 01/07/2016

**ABSTRACT**

Epidermodysplasia verruciformis (EV) is a rare genodermatosis characterized by a unique susceptibility to cutaneous infection by a group of phylogenetically related human papilloma viruses (HPVs). These patients show a defect in cell-mediated immunity specific toward the causative HPVs that lead to lifelong disease. The defect is usually inherited as autosomal recessive trait and presents clinically with plane warts, pityriasisversicolor-like lesions and reddish verrucous plaques. Dysplastic and malignant changes in the form of actinic keratoses, Bowen's disease and squamous cell carcinoma (SCC) are common but metastasis occurs rarely. A totally effective treatment against EV is as yet highly desirable. We report a case of epidermolysisdysplasiaverruciformis in a 13 year old female patient with confluent wart like lesions, pityriasisversicolor like lesions and reddish plaques. The case is being reported in view of rarity of disease.

**KEYWORDS:** Epidermodysplasia verruciformis, genodermatosis, pityriasisversicolor.

**INTRODUCTION**

Epidermodysplasia verruciformis (EV) is a rare genodermatosis characterized by wide spread and persistent infection with human papilloma viruses (HPVs), presenting clinically with characteristic combination of pityriasisversicolor-like lesions, reddish verruca-like and seborrheic keratosis-like plaques with a potential for malignant transformation.<sup>[1]</sup> To date >100 HPV types have been identified but mostly HPV 3, 5, 8, 9, 10, 12, 14, 17, 19-25, 28 and 29 are related to EV<sup>[1],[2],[3]</sup> and more than one HPV type may be present simultaneously in the same patient. HPV-5 and HPV-8 are found in 90% of skin cancers in EDV patients.<sup>[2]</sup> Impairment of cell mediated immunity, notably T helper cell function, is commonly but not invariably found.<sup>[3]</sup> A PubMed and IndMed search on 26 Oct 2009 revealed only 12 reports appearing between 1971 and 2009 in India.

**CASE REPORT**

A 13 year old female patient presented in our OPD with multiple discrete erythematous papules over the face and such lesions coalesced to form plaques mainly over forehead with skip areas in between. Multiple 2-3 mm scaly hypopigmented macules over ears, neck, anterior and posterior trunk and extensor aspect of upper and lower extremities. Multiple discrete verrucus warty papules over dorsum of both hands and feet. The child was born out of non-consanguineous marriage. No history of similar lesions in any of the family members.

The disease started in the form of hypopigmented macule over left cheek. The lesions gradually involves whole of the body in the course of 18 months. She complains of mild pruritus in the lesions after going out in the sun. Lesions were scantier in genital areas and extremities. Routine laboratory examinations including complete blood count, urine analysis, liver function test, renal function test, FBS, PPBS, HIV I&II, showed no abnormal finding. Histopathological examination of the skin lesions showed well circumscribed epidermal hyperplasia with gentle mammillation of the surface. The epidermis showed vacuolization of cells in spinous and granular layers with foamy appearance of cytoplasm. Granular layer was thickened and stratum corneum showed basket weave orthohyperkeratosis. There was nuclear atypia within keratinocytes.

On the basis of above constellation of symptoms (history, morphology of lesions, histopathological findings), a diagnosis of Epidermodysplasiaverruciformis was made.

Patient was managed with oral isotretinoin, emollients, and broad spectrum sunscreen lotion. She was advised for regular follow up in the view of increased risk of skin cancers.

**DISCUSSION**

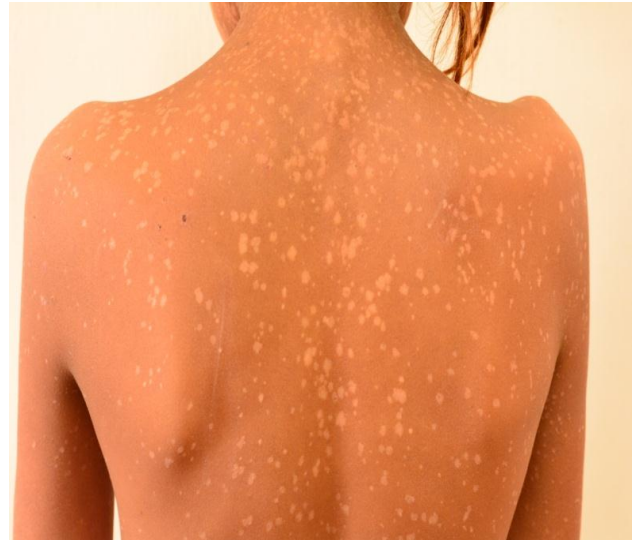EDV usually manifests in childhood with persistent and often widespread warts that do not regress due to unique

susceptibility to specific HPV types. Individual lesions typically have either the appearance of flat warts or flat scaly red-brown macules that resemble pityriasis versicolor, particularly if they occur on the trunk. The presence of warts on large areas of the body is suggestive but not necessary to consider this diagnosis. Involvement of the cervix and oropharynx is rare. Failure to clear lesions despite adequate treatment is another indication of potential EDV. Because warts in EDV almost always recur after treatment, this implies a failure to mount an effective immune response to the HPV infection. Individuals with EDV do not usually have frequent bacterial or other viral infections. Immunocompromised individuals, such as those with HIV infection, may have multiple warts that contain EV and other  $\beta$ -HPV types and are difficult to eradicate, but this susceptibility is acquired. SCCs in EV and immunosuppression usually arise in pityriasis-like lesions on sun-exposed areas. Regional and distant metastases may occur. Although pityriasis-like lesions caused by any EV type are at risk of becoming malignant, this is higher for those caused by HPV-5 and -8. Dysplastic and malignant changes occur most often on exposed skin, commonly as actinic keratoses and Bowen's disease, suggesting that ultraviolet radiation is an important factor. The combination of etretinate plus IFN- $\alpha$  may also produce a useful clinical effect.<sup>[4]</sup> Oral isotretinoin can also reduce the benign lesions.<sup>[5,6]</sup> The combination of etretinate plus IFN- $\alpha$  may also produce a useful clinical effect.<sup>[4]</sup> Oral isotretinoin can also reduce the benign lesions.<sup>[5,6]</sup> Other treatments that have been tried in individual cases or small numbers of patients and shown occasional but inconsistent benefit include topical imiquimod<sup>[7,8]</sup>, topical vitamin D analogue<sup>[6]</sup>, topical immunotherapy with squaric acid dibutylester<sup>[9]</sup> and oral cimetidine.<sup>[10,11]</sup>

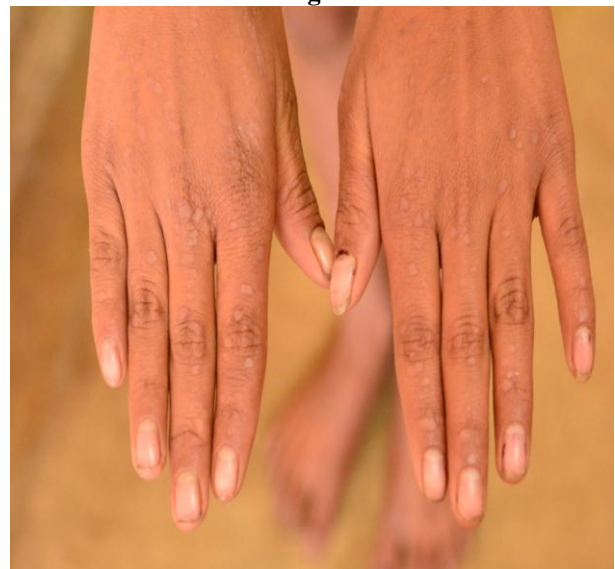We report this case due to its rarity and unique presentation.



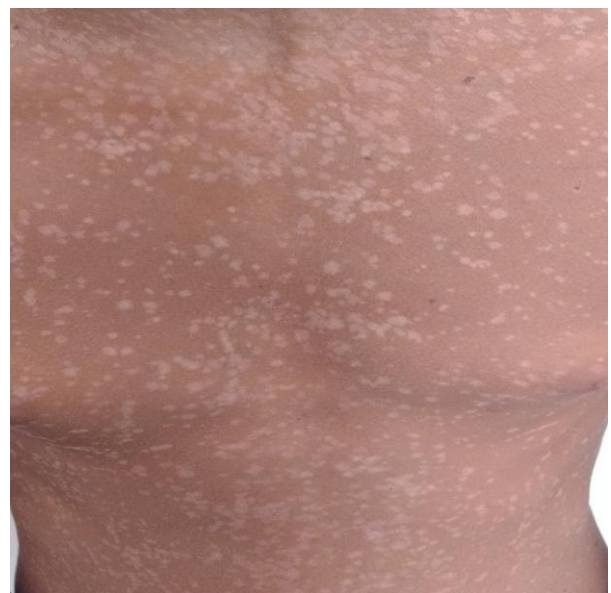**FIG-1**



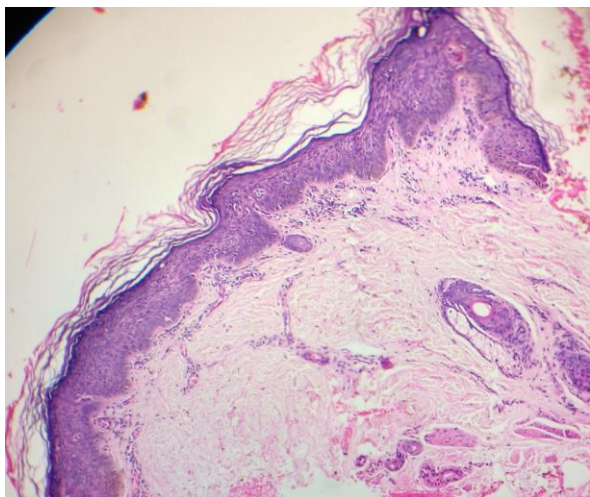
**fig2**



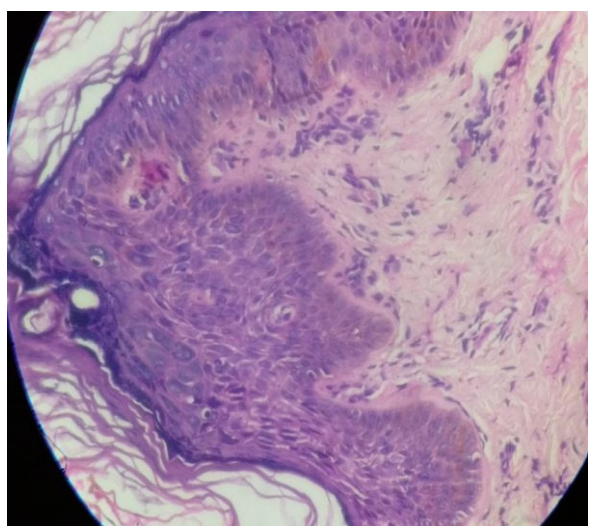
**fig 3**



**FIG 4**



HPE 10X



HPE 40x.

6. Hayashi J, Matsui C, Mitsuishi T *et al.* Treatment of localized epidermodysplasia verruciformis with tacalcitol ointment. *Int J Dermatol.*, 2002; 41: 817.
7. Berthelot C, Dickerson MC, Rady P *et al.* Treatment of a patient with epidermodysplasia verruciformis carrying a novel EVER2 mutation with imiquimod. *J Am Acad Dermatol.*, 2007; 56: 882–6.
8. Berthelot C, Dickerson MC, Rady P *et al.* Treatment of a patient with epidermodysplasia verruciformis carrying a novel EVER2 mutation with imiquimod. *J Am Acad Dermatol.*, 2007; 56: 882–6.
9. Ishiji T, Ibe M, Kawase M *et al.* Patients with epidermodysplasia verruciformis show no response to contact immunotherapy. *Dermatology.*, 2001; 202: 76–7.
10. Micali G, Nasca MR, Dall'Oglio F *et al.* Cimetidine therapy for epidermodysplasia verruciformis. *J Am Acad Dermatol.*, 2003; 48: S9–10.
11. De Oliveira WR, Neto CF, Rivitti EA. The lack of a clinical effect of cimetidine in the treatment of epidermodysplasia verruciformis. *J Am Acad Dermatol.*, 2004; 50: e14.

#### REFERENCES

1. Garcia-Rvo I, Garcia-F-Villalta MJ, Daudin E, Fraga J, Garcia-Dvez A. Epidermodysplasia verruciformis-like lesions in a patient with systemic lupus erythematosus. *Acta Derm Venereol.*, 2003; 83: 229-30.
2. Ostrow RS, Manias D, Mitchell AJ, Stawowy L, Faras AJ. Epidermodysplasia verruciformis. A case with primary lymphatic dysplasia, depressed cell-mediated immunity, and Bowen's disease containing human papilloma 16 DNA. *Arch Dermatol.*, 1987; 123: 1511-6.
3. Pfister H. Human papilloma viruses and impaired immunity vs epidermodysplasia verruciformis. *Arch Dermatol.*, 1987; 123: 1469-70.
4. Anadolu R, Oskay T, Erdem C *et al.* Treatment of epidermodysplasia verruciformis with a combination of acitretin and interferon alfa-2a. *J Am Acad Dermatol.*, 2001; 45: 296–9.
5. Rallis E, Pappazios V, Kyriakis K *et al.* Treatment of epidermodysplasia verruciformis in human immunodeficiency virus-positive patients. *J Eur Acad Dermatol Venereol.*, 2009; 23: 195–6.