

FRACTAL DIMENSION: A NEW METHOD TO QUANTIFY INTESTINAL HEALING IN DIABETES

Erika Veruska Paiva Ortolan*¹, Carlos Antônio Caramori², Pedro Luiz Toledo de Arruda Lourenção³, Simone Antunes Terra⁴, Marcos Curcio Angelini⁵ and César Tadeu Spadella⁶

¹PhD, MD, Associate Professor, Head of Surgery and Orthopedic Department, Botucatu Medical School, Unesp, Botucatu, São Paulo, Brazil.

²PhD, MD, Associate Professor, Department of Internal Medicine, Botucatu Medical School, Unesp, Botucatu, São Paulo, Brazil.

³PhD, MD, Assistant Professor, Surgery and Orthopedic Department, Botucatu Medical School, Unesp, Botucatu, São Paulo, Brazil.

⁴MD, Fellow Phd Degree, Department of Pathology, Botucatu Medical School, Unesp, Botucatu, São Paulo, Brazil.

⁵MD, Fellow Master Degree, Surgery and Orthopedic Department, Botucatu Medical School, Unesp, Botucatu, São Paulo, Brazil.

⁶PhD, MD, Chairman of Surgery and Orthopedic Department, Botucatu Medical School, Unesp, Botucatu, São Paulo, Brazil.

Corresponding Author: Prof. Erika Veruska Paiva Ortolan

PhD, MD, Associate Professor, Head of Surgery and Orthopedic Department, Botucatu Medical School, Unesp, Botucatu, São Paulo, Brazil.

Article Received on 01/06/2016

Article Revised on 22/06/2016

Article Accepted on 13/07/2016

ABSTRACT

Purpose: to investigate if experimental alloxanic diabetes could cause quantitative changes in intestinal anastomoses of the terminal ileum and distal colon in rats, as compared to controls, measured by fractal dimension.

Method: 96 male Wistar rats weighing ± 300 g were split into four groups, and were submitted to ileum and colon anastomoses after a 3 month pre op period of follow up: G1- control group with ileum anastomoses, G2- control group with colon anastomoses, G3-diabetic group with ileum anastomose and G4- diabetic group with colon anastomoses. After a three month post-op period, the animals were sacrificed on days 4, 14, 21 and 30, and fragments of the anastomoses were removed, and analyzed in the scanning electron microscope and the images obtained were used to calculate the fractal dimension of the anastomosis. **Results:** Ultrastructural analysis of the anastomoses revealed fewer wide collagen fibers that were narrower and disarranged, as compares to the control animals in all of the moments. The results of fractal dimension showed a tendency to higher complexity of the anastomosis in the diabetic animals, as compared to controls. **Conclusion:** experimental diabetes caused qualitative changes in scar tissue, seen at alterations in the structural arrangement of collagen fibers and a tendency to more complexity in fractal dimension.

KEYWORDS: alloxan Diabetes, wound healing, surgical anastomosis, fractals.

INTRODUCTION

Several experimental studies of healing alterations in chronic diabetes have been done using different parameters, such as breaking strength, measures of collagen types and hystopathogy. However, most studies have been conducted only in skin models.^[1] The results obtained therefore, cannot be applied to intestinal wounds. Few authors have studied the effects of diabetes in intestinal wound healing. Previous studies by our group have shown that chronic diabetes does not change the breaking strength and values of hydroxyproline and total tissue protein in ileum and colon fragments taken from rats before surgical injury.^[2] Another experiment from our group showed a significant decrease in anastomotic breaking strength following anastomosis of ileum and colon in diabetic animals, yet the values of

hydroxyproline and total tissue protein remained unchanged as compared to the controls.^[3] Other studies have revealed the same results in early-post-operative days following intestinal anastomosis in streptozotocin-diabetic rats.^[4-5] Thus, there is an agreement in literature that if there are not quantitative changes in the collagen of intestinal anastomosis from diabetic animals, probably qualitative changes may occur. A previous study from our group analyzed the ultrastructure of intestinal anastomotic healing using scanning electron microscopy.^[6] Trying to measure what was proved to be altered in a quantitative analysis, we decided to use the scanning electron microscope images to calculate the fractal dimension.

The term fractal was named by Mandelbrot, it is derived from the latin *fractus*, that means fractioned, irregular, and are applied to situations that cannot be measured in a single absolute scale.^[7] It is based on the principle that a complex non-linear pattern can produce self-similarity patterns in different scales.^[8] Therefore, the aim of this study was to analyze intestinal anastomosis using fractal dimension, which measures the complexity of the image, to measure what could be hard to be done using formulas from Euclidian Mathematic, introducing a new tool in the quantitative analysis of intestinal healing.

METHODS

1. Experimental protocol

Ninety-six male Wistar rats, three-months-old and weighing between 200 and 300g, were obtained from our own colony. Animals were housed four per cage, fed standard chow (Nuvilab, Curitiba, PR, Brazil), and given access to water *ad libitum*. After an observation period of one week, rats were randomly divided into a control and a diabetic group. The animals of the latter group were rendered diabetic three months before surgery by a single intravenous injection of alloxan 2% (Sigma Chemical Co., St Louis, MO, USA), at a dose of 42mg/kg body weight. The study included only animals with severe diabetes characterized by fasting glycemic indices higher than 200mg/dl and 3+ glycosuria, as measured using reagent sticks. Fast glycemia, glycosuria and seric insulin levels were measured before the surgery and at sacrifice.

Three months after diabetes induction, the control and diabetic groups were again randomly divided in 4 groups: one normal control group submitted to ileum anastomoses (G1), one normal control group submitted to colon anastomoses (G2), one diabetic group submitted to ileum anastomoses (G3) and the fourth diabetic group submitted to colon anastomoses (G4).

Surgery was performed under semi-sterile conditions. Rats were anaesthetized by intraperitoneal injection of sodium pentobarbital (Cristalia, Sao Paulo, Brazil) 30mg/kg body weight. A median laparotomy of approximately 5 cm was performed. After section of the terminal ileum 5cm proximal to the ileocecal junction, an ileoileal anastomosis was constructed using 8 equidistant single-layer interrupted 6-0 Ethilon (Ethicon, USA) sutures. A similar procedure was performed for the colonic anastomoses, 5 cm proximal to the peritoneal reflection. The abdomen was closed with interrupted 5-0 Ethilon (Ethicon, USA) for the musculofascial and skin layers. All surgical procedures were executed by the same surgeon (the corresponding author).

After surgery, 6 animals in each group of 24 animals were sacrificed on days 4, 14, 21 and 30. The abdomen was opened and inspected. The anastomotic segments were resected and washed in saline. Feces were removed carefully. The anastomotic fragments were submitted to scanning electron microscopy investigation and

subsequent fractal dimension analysis. Rats were sacrificed by aortic puncture.

The study was performed after approval by the São Paulo State University, Botucatu Medical School Ethics Committee for Experimental Research (359/2003).

2. Scanning electron microscope

For the ultrastructural studies, each anastomosed segment was placed on dry filter paper with the mucosal surface facing upwards and treated with 10% NaOH at 4°C for two days. In this way the cellular mucosa and muscular layers could be easily scraped off to expose the submucosa collagen layer. Specimens were fixed overnight in a 3% phosphate-buffered (pH 7.3) glutaraldehyde solution containing 5% sucrose. Following fixation, specimens were washed three times for one hour using phosphate buffer at ambient temperature. Each specimen was then dehydrated in increasing concentrations of ethanol in water, air dried and stored in a desiccator until it was coated with a gold-palladium alloy. Specimens were scanned in the QUANTA 200 scanning electron microscope at magnifications ranging from x90 to x3000. Fields used for scanning were chosen randomly from the entire healing zone.

3. Fractal dimension

The fractal dimension was obtained using the 700x scanning electron microscope images mentioned above and ImageJ 1.34p (NIH-USA-Java 1.5.0-03 – latest version issued 9/6/2005) to process and analyze the images. ImageJ is a public-domain Java image processor developed by Wayne Rasband (wayne@codon.nih.gov) at the Research Services Branch - National Institute of Mental Health - National Institute of Neurological Disorders and Stroke, Bethesda, Maryland, USA (<http://rsb.info.nih.gov/ij/index.html>). It can be downloaded from the Internet by accessing the Wright Cell Imaging Facility site (<http://www.uhnresearch.ca/wcif>).

Since the application detects only black pixels on a white background, or vice-versa, scanning electron microscope images of the anastomoses were processed and transformed into binary images using the thresholding method. This is a segmentation technique that groups different objects and regions of the image based on luminous intensity (similarity of tones). In the thresholding process, the software automatically assigns an average threshold value of T for luminous intensity, and proceeds to the cutoff point (binarization) of the image. Our images are made up of 256 tones of gray and, below the cutoff point T, all tones become background information (binary value of 0 or black). Values above the threshold become data corresponding to objects in the image (binary value of 1 or white). The method has proven to be valid when the images have good definition and contrast between the different regions, as is the case in our study. The binarized

images were skeletonized, a filtering process that repeatedly removes the pixels along the outline of binary images until it has been reduced to a thickness of one

pixel, thus producing a skeleton of the image, which is submitted to fractal analysis (figure 1).

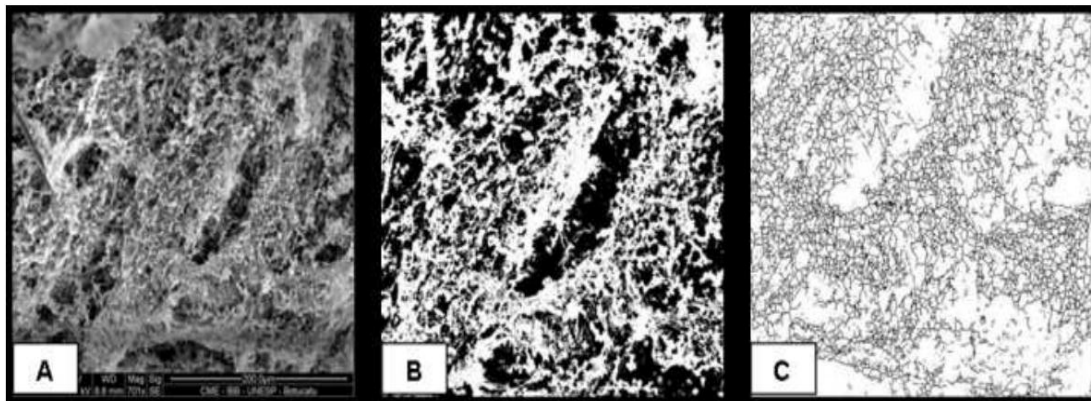


Figure 1: 700x scanning electron photomicrograph of the intestinal anastomosis (A), used for binarization or thresholding (B) and subsequent skeletonizing (C).

Of all the methods used to calculate fractal dimension, the most common is Box-Counting, which can be used for objects that have 0 to 2 dimensions. As structures become more complex, the fractal dimension approaches 2. Box-Counting consists of changing the scale of observation of a given object, analyzing how its density varies. To do so, the object to be analyzed is placed in a Cartesian plane upon which a grid of known scale is overlaid. The number of elements within each box is counted, the variation in scale with the number of boxes is an exponential function governed by an equation of the type $N=S^D$.

Bringing out D, we have $D = \frac{\log(N(a))}{\log\left(\frac{1}{S}\right)}$, where D is

the fractal dimension, N(a) is the number of boxes that contain the object and s is the scale factor.

For this calculation we used FracLac V2.3 (FracLac.java) version 2005, developed by A. Karperian at Charles Sturt University – Australia, a plug-in for the aforementioned ImageJ. FracLac produces the box counting fractal dimension by overlaying the image with a series of grids of decreasing box size, counting the number of boxes that fall on the image and the number of pixels per box for each box size.

This analysis can measure the degree of complexity of the collagen arrangement in the anastomoses. The result is presented graphically, with the average fractal dimension corrected by removing gaps (horizontal slope removed) and by the standard error in the average.

4. Statistical analysis

Statistical analysis was performed using the software SPSS v15.0 to compare the results between groups, in different moments. Mann-Whitney test or Student's T test was used, according to data distribution previously

determined by Shapiro-Wilk normality test. Probability values less than 5% were considered significant.

RESULTS

The results of the analyzed parameters (fast glycemia, glycosuria and seric insulin) of G3 (diabetic rats submitted to anastomosis of the ileum) and G4 (diabetic rats submitted to anastomosis of the colon) animals during the study period were quite similar, and contrasted sharply from the non diabetic groups. G3 and G4 rats showed clinical and laboratory parameters compatible with severe diabetes and on follow-up showed a progressive decline in overall well-being, a weight loss following induction and a significantly lower weight gain. Their fasting glycemias were over 300mg/dl with 3+ glycosuria as compared to the control groups. Alloxan injection significantly reduced the plasmatic insulin concentration and kept them at low levels throughout the study.^[6]

Qualitative scanning electron microscope analysis of the ileum and colon anastomosis showed similar results and were reported in a previous publication.^[6] On postoperative day 4, the anastomosis of control rats showed a fine network of primitive granulation tissue. Collagen fibrils were visible and covered with globular-formed macromolecules, which were proteoglycans. Diabetic animals, on the other hand, showed fewer collagen fibrils and a much larger quantity of proteoglycans. On postoperative day 14, the anastomotic healing zone of control group (non diabetic) animals were loosely bundled together in primitive organized collagen fibers, with few proteoglycans molecules. In the diabetic animals, the fibrils were irregular, random and loosely packed, with a large number of proteoglycans visible. On postoperative day 21, the density of collagen fibrils was higher in the control groups, with small fibers intimately attached to large wavy fibers crimped in register with fewer interspaces. This was not the case in diabetic animals, where proteoglycans molecules and

disarranged collagen fibers were still visible. On postoperative day 30, the control animals showed thicker collagen fibers that were intimately attached and oriented, and no visible proteoglycans. Diabetic rats showed a paucity of large fibers and those that existed were poorly attached by small collagen fibers, and visible proteoglycans groups were still present.

The 700x scanning electron microscope images used to calculate fractal dimension in animals from groups G1 and G3 (ileum anastomosis), showed statistically significant differences at M2 (14 days after surgery) (table 1), while animals whose colon had been operated on did not show statistically significant differences, with a tendency of higher values at M1 and M4 (4 and 30 days after surgery), in the diabetic groups (table 2).

Table 1: Values of fractal dimension in ileum groups, at the sacrifice moments.

Moments	G1 Control ileum	G3 Diabetic ileum	p
*M1	1,72 (1,65-1,78)	1,71 (1,63-1,8)	0,6310
**M2	1,71±0,03	1,82±0,03	0,0004
**M3	1,73±0,12	1,78±0,05	0,447
**M4	1,72±0,01	1,74±0,05	0,298

*Data expressed in median (min-max); Mann-Whitney test

** Data expressed in media ± standard deviation; test T.1

Table 2: Values of fractal dimension in colon groups, at the sacrifice moments.

Moments	G2 Control colon	G4 Diabetic colon	p
*M1	1,71 (1,67-1,75)	1,77 (1,69-1,78)	0,0547
**M2	1,69±0,05	1,73±0,05	0,1913
**M3	1,74±0,06	1,75±0,05	0,7708
*M4	1,73 (1,52-1,78)	1,77(1,72-1,8)	0,0547

* Data expressed in medians (min-max); Mann-Whitney test

** Data expressed in medias ± standard deviation; test T.

DISCUSSION

Restoration of tissue strength is an important aspect of wound healing. This process requires the deposition of adequate amounts of extra-cellular matrix components, particularly collagen fibers, in the wound area. Recently, this research group has found significantly reduced anastomotic strength in the ileum and colon in a chronic diabetes model^[2], which is identical to the one of the present study. However, biochemical analyses suggest that loss of strength is not accompanied by either reduced capacity for collagen synthesis or reduced collagen content in the anastomotic segments. Other authors have reported similar results in a short-term diabetic rat model.^[4-5]

Scanning electron microscopy has been used to investigate the effects of experimental diabetes on the retina, kidneys and bones.^[8-10] A previous study of our group showed the ultrastructural analysis using scanning electron microscopy in intestinal anastomosis in normal and diabetic animals^[6]. This method is a valuable aid to the study of anastomoses, as it enables analyzing and describing smaller samples and provides an overview of the ultrastructural collagen arrangement. In this previous study, the massive presence of finer collagen fibers that are not connected to thicker fibers, which themselves are present in a smaller number and in no definite arrangement, raises the hypothesis that the diminished rupture strength of anastomoses of diabetic animals, measured by biomechanical studies conducted in our laboratory^[3] and also reported by other authors^[4-5], is

directly involved in the genesis of this alteration. Besides its use to qualitative analysis, these images could be used to calculate the fractal dimension, in an attempt to measure what could be hard to calculate from a Euclidian Mathematic.

The fractal dimension has been used for the differential diagnosis of breast nodes^[11-12], pulmonary nodes^[13-14], colon polyps^[15], and for the diagnosis and staging of pulmonary emphysema^[16], diabetic retinopathy^[17-18] and arterial pressure^[19]. Recently was used as a new tool in a pilot study to differentiate colorectal cancers.^[20]

In the present study, qualitative scanning electron microscopy pictures of the intestinal anastomoses of normal and diabetic rats were analyzed with the Box-Counting calculation of the fractal dimension of the digitized images. In the animals submitted to ileum surgery, we found statistical differences at M2 (14 days after surgery); in animals submitted to colon surgery, differences were not found, with a tendency to higher values in diabetic group at M1 and M4 (4 and 30 days after surgery). Diabetic animals always had higher fractal dimension values than did the control groups, with statistically significant differences at the moment mentioned above. These findings may suggest a higher complexity of the anastomoses of diabetic animals, with values closer to 2. The qualitative electron microscopy analysis showed a lack of defined arrangements in diabetic animals, gaps in the anastomoses, a smaller number of thick collagen fibers and a larger number of

thinner fibers.^[6] Correlating these findings with the fractal dimension analysis lead us to hypothesize that the lack of defined, regular collagen arrangements in the anastomoses corresponds to higher complexity of the anastomosis as measured by the fractal dimension, and therefore lower tensile strength, as measured in previous biomechanical studies.

A single previous study analyzed colonic anastomosis healing using FD, to assess experimentally the effects of some chemotherapeutic drugs used to treat colon cancer in the colon's healing process. They found that the decreased results in the connective tissue FD were related to restoration of the connective tissue structure measured in other qualitative parameters.^[21]

FD is a parameter which reflects the complexity and irregularity of target tissues.^[22] Tissues submitted to remodeling due to any cause are characterized by an increased FD.^[21] There are no reports in the literature using fractal dimensions in intestinal anastomosis related to diabetes. Our results showed a tendency to higher values of FD in the diabetic animals, what is in agreement with the previous single study that obtained lower FD results in better quality colon anastomosis^[21]. Further studies are required in order to advance in this new field of applied knowledge.

REFERENCES

1. Andreassen TT, Oxlund H. The influence of experimental diabetes and insulin treatments on the biomechanical properties of rat skin incisional wounds. *Acta Chir Scand*, 1987; 153(7-8): 405-9. PMID:3314300
2. Ortolan EVP, Spadella CT, Machado JLM, Kobayasi S. The evaluation of healing parameters in the colon of diabetic rats without surgical injury. *Acta Cir Bras*, 2004; 19(3): 286-95. Doi: 10-1590/S0102-86502004000300011
3. Machado JLM, Ortolan, EVP, Spadella CT. Anastomotic healing in ileum and colon of alloxan-induced diabetic rats. *Acta Cir Bras*, 2009; 24 (1): 57-61. Doi: 10.1590/S0102-86502009000100012
4. Verhofstad MHJ, Hendriks T. Diabetes impairs the development of early strength, but not the accumulation of collagen, during intestinal anastomotic healing in the rat. *Br J Surg*, 1994; 81(7): 1040-5. PMID: 7922059
5. Onodera H, Ikeuchi D, Nagayama S, Imamura M. Weakness of anastomotic site in diabetic rats is caused by changes in the integrity of newly formed collagen. *Dig Surg*, 2004; 21(2): 146-51. PMID: 15133313. Doi: 10.1159/000078381
6. Ortolan EVP, Spadella CT, Caramori C, Machado JL, Gregorio EA, Rabello K. Microscopic, Morphometric and Ultrastructural Analysis of Anastomotic Healing in the Intestine of Normal and Diabetic Rats. *Exp Clin Endocrinol Diabetes*, 2008; 116(4): 198-202. PMID: 18072010. Doi:10.1055/s-2007-993147.
7. Manelbrot BB. The fractal geometry of nature. 3 ed. New York: WH Freeman and Company, 1983.
8. Hamilton CW, Chandler DBS, Klintworth GK, Machemer R. A transmission and scanning electron microscopic study of surgically excised preretinal membrane proliferations in diabetes mellitus. *Am J Ophthalmol*, 1982; 94(4): 473-88. PMID: 7137272
9. Makino H, Yamasaki Y, Haramoto T, Shikata K, Hironaka K, Ota Z, Kanwar YS. Ultrastructural changes of extracellular matrices in diabetic nephropathy revealed by high resolution scanning and immunoelectron microscopy. *Lab invest*, 1993; 68(1): 45-55. PMID: 8423676
10. Follak N, Kloting I, Wolf E, Merk H. Histomorphometric evaluation of the influence of the diabetic metabolic state on bone defect healing depending on the defect size in spontaneously diabetic BB/OK rats. *Bone*, 2004; 35(1): 144-52. PMID: 15207750. Doi: 10.1016/j.bone.2004.03.011
11. Pohlman S, Powel KA, Obuchowski NA, Chilcote WA, Grundfest-broniatowski S. Quantitative classification of breast tumors in digitized mammograms. *Med Phys*, 1996; 23(8): 1337-45. PMID: 8873030. Doi: 10.1118/1.597707.
12. Shahar K, Solaiyappan M, Bluemke DA. Quantitative differentiation of breast lesions based on three-dimensional morphology from magnetic resonance imaging. *J Comput Assist Tomogr*, 2002; 26(6): 1047-53. PMID: 12488759.
13. Kido S, Kuriyama K, Higashiyama M, Kasugai T, Kuroda C. Fractal analysis of small peripheral pulmonary nodules in thin-section CT: evaluation of the lung-nodules interfaces. *J Comput Assist Tomogr*, 2002; 26(4): 573-8. PMID: 12218822.
14. Kido S, Kuriyama K, Higashiyama M, Kasugai T, Kuroda C. Fractal analysis of internal and peripheral textures of small peripheral bronchogenic carcinomas in thin-section computed tomography: comparison of bronchioalveolar cell carcinomas with nonbronchioalveolar cell carcinomas. *J Comput Assist Tomogr*, 2003; 27(1): 56-61. PMID: 12544244.
15. De Felice C, Latini G, Bianciardi G, Parrini S, Fadda GM, Marini M, Laurini RN, Kopotic RJ. Abnormal vascular network complexity: a new phenotypic marker in hereditary non-polyposis colorectal cancer syndrome. *Gut*, 2003; 52(12): 1764-7. PMID: 14633958.
16. Chung H, Huang Y. Fractal analysis of nuclear medicine images for the diagnosis of pulmonary emphysema: interpretations, implications and limitations. *AJR Am J Roentgenol*, 2000; 174(4): 1055-9. PMID: 10749249. Doi: 10.2214/ajr.174.4.1741055.
17. Daxer A. Characterization of the neovascularization process in diabetic retinopathy by means of fractal geometry: diagnostic implications. *Graefes Arch Clin Exp Ophthalmol*, 1993; 231(12): 681-6. PMID: 8299974.
18. Cheng SC, Huang YM. A novel approach to diagnose diabetes based on the fractal characteristics

- of retinal images. *IEEE Trans Inf Technol Biomed*, 2003; 7(3): 163-70. PMID: 14518729.
19. Wagner CD, Nafz B, Pesson PB. Chaos in blood pressure control. *Cardiovasc Res.*, 1996; 31(3): 380-7. PMID: 8681325.
 20. Streba L, Fortofoiu MC, Popa C, Ciobanu D, Gruia CL, Magoanta SS, Streba CT. A pilot study on the role of fractal analysis in the microscopic evaluation of colorectal cancers. *Rom J Morphol Embryol*, 2015, 56(1): 191-6. PMID: 25826505.
 21. Letowska-Andrzejewicz K, Torres A, Torres K, Dobrowolski P, Piersiak T, Maciejewski R, Gawron A, Staskiewicz G, Plewa Z. The use of morphometric and fractal parameters to assess the effects of 5-fluorouracil, interferon and dexamethasone treatment on colonic anastomosis healing: an experimental study in rats. *Folia Histochem Cytobiol*, 2011; 49(1): 80-9. PMID: 21526493.
 22. Cross SS. Fractals in pathology. *J Pathol*, 1997; 182(1):1-8. PMID: 9227334. Doi: 10.1002/(SICI)1096-9896(199705)182:1<1::AID-PATH808>3.0.CO;2-B.