

**DELAYED NEUROLOGICAL SYNDROME DUE TO CARBON MONOXIDE  
POISONING: A CASE REPORT****\*Dr. Masaraf Hussain**

Assistant Professor Neurology Shillong Meghalaya India 793004.

**\*Correspondence for Author: Dr. Masaraf Hussain**

Assistant Professor Neurology Shillong Meghalaya India 793004.

Article Received on 03/06/2016

Article Revised on 23/06/2016

Article Accepted on 13/07/2016

Carbon monoxide is a highly toxic gas and is a by-product of incomplete combustion of hydrocarbons. Accidental carbon monoxide poisoning can occur due to faulty domestic heating appliances, exposure to car exhaust fumes in an enclosed space.<sup>[1]</sup>

**CASE REPORT**

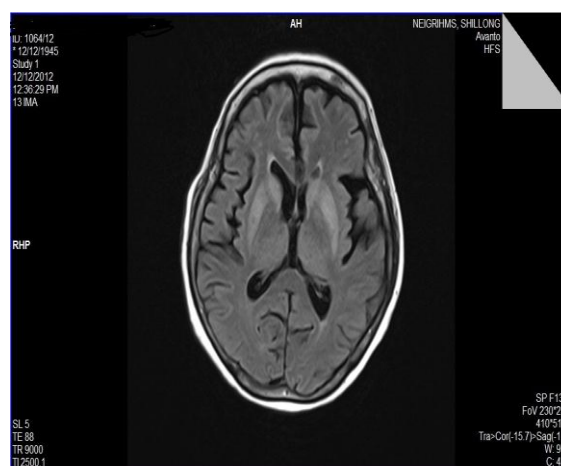
A 67 years old lady presented with history of tremors both hands, inability to walk and slurring of speech, since two weeks. She had fracture head of femur one month back. There was no history fever, seizure, substance abuse, or any medication intake prior to this episode. On admission, she was responsive, but disoriented to time and place, with dysarthria. Pupils were normal in size and well reacting to light. There was marked limb rigidity, with tremor of both hands. There was no sign of meningeal irritation.

Blood investigations revealed no abnormality. Brain MRI showed (Figure 1) hyperintense lesions of the caudate nucleus and putamen on T2-weighted sequences (hypointense on T1- weighted sequence).

On further history taking it emerged that the patient was lying in a small room with poor ventilation with a burning charcoal stove nearby.

Therefore a diagnosis of Carbon Monoxide poisoning with delayed neurological manifestation was made.

The patient gradually showed improvement of gait and reduction of tremors.



**Figure 1: Showing bilateral Basal ganglia hyperintensities in T2 Weighted sequences**

**DISCUSSION**

As the history of Carbon monoxide exposure was not available initially, there was some delay in diagnosis.

The clinical presentation of carbon monoxide poisoning may be acute or delayed neurological symptoms. Delayed neurological symptoms appear after 2 to 4 weeks of the exposure. The presentation include apathy, psychosis, movement disorders.<sup>[2]</sup> The incidence of delayed neuropsychiatric syndrome may be as high as 46% in carbon monoxide toxicity.<sup>[3]</sup>

The underlying pathophysiology of this delayed syndrome is controversial. Several hypotheses include post anoxic demyelination due to anoxically damaged cerebral blood vessels, or Carbon monoxide causing a direct myelinotoxic effect.<sup>[4]</sup> Cellular theories have proposed immunopathological damage by activation of polymorphonuclear leukocytes by carbon monoxide.<sup>[5]</sup>

Older age (>36 years), longer duration of carbon monoxide exposure (>24 hours), abnormal mental status

at presentation and more extensive brain imaging abnormalities, they all predict occurrence of delayed neuropsychiatric syndrome.<sup>[6]</sup>

Movement disorders can develop usually several weeks after the acute insult. Reported incidence of movement disorders is 13.2%.<sup>[7]</sup> The prognosis is usually good. Though there is no absolute correlation between the affected site on neuroimaging and the symptomatology, the globus pallidus is the commonest site of brain involvement in Carbon monoxide poisoning.<sup>[8]</sup>

Currently there is no specific therapy for the delayed neuropsychiatric syndrome, however in view of the role of inflammation, anti-inflammatory therapies may warrant further studies.<sup>[9]</sup>

### CONCLUSION

As the cause of recent onset extrapyramidal symptoms may be varied in the elderly, a high index of suspicion and a thorough history may reveal it to be a delayed manifestation of Carbon monoxide poisoning.

### REFERENCES

1. Crawford R, Campbell DGD, Ross J. Carbon monoxide poisoning in the home: recognition and treatment. *BMJ.*, 1990; 301: 977-9.
2. Min SK. A brain syndrome associated with delayed neuropsychiatric sequelae following acute carbon monoxide poisoning. *Acta Psychiatr. Scand.* 1986; 73: 80-6.
3. Ernst A, Zibrak JD. Carbon monoxide poisoning. *N Engl J Med*, 1998; 339: 1603-8.
4. Plum F, Posner JB, Hain RH. Delayed neurological deterioration after anoxia. *Arch Intern Med*, 1962; 110: 56-63.
5. Wing YK, Wong T, Kwok A. Delayed neuropsychiatric impairment after carbon monoxide poisoning from burning charcoal. *Hong Kong Med J.*, 2004; 10: 428-431.
6. Ku HL, Yang KC, Lee YC, Lee MB, Chou YH. Predictors of carbon monoxide poisoning induced delayed neuropsychiatric sequelae. *General Hospital Psychiatry*, 2010; 32: 310-14.
7. Saing Choi. Carbon monoxide poisoning: Systemic Manifestation and Complication. *J Korean Med Sci.*, 2001; 16: 253-61.
8. O'Donnell P, Buxton PJ, Pitkin A, Jarvis LJ. The magnetic resonance imaging appearance of the brain in acute carbon monoxide poisoning. *Clin Radiol*, 2000; 55: 273-80.
9. Weaver LK. Clinical practice. Carbon monoxide poisoning. *N Engl J Med.*, 2009; 360: 1217-25.