

RIGHT HEMIAGENESIS OF THYROID GLAND WITH APLASTIC ISTHMUS-A CASE REPORT

¹Dr. Kunaal Jain*, ²Dr. Rajesh Kuber, ³Dr. Arijit Ghosh, ⁴Dr. Shubham Singhal, ⁵Dr. Vigyat Kamal, ⁶Dr. Avadhesh chauhan

^{1,3,4,5,6}PG Student, Department of Radiology, Dr. DY Patil Medical College & Research Center, Pimpri, Pune.

²Professor, Department of Radiology, Dr. DY Patil Medical College & Research Center, Pimpri, Pune.

*Correspondence for Author: Dr. Kunaal Jain

PG Student, Department of Radiology, Dr. DY Patil Medical College & Research Center, Pimpri, Pune.

Article Received on 08/06/2016

Article Revised on 29/06/2016

Article Accepted on 19/07/2016

ABSTRACT

Hemiagenesis of thyroid gland with aplastic isthmus is a rare entity with limited cases documented. Left lobe is more commonly involved as compared to right lobe with female predominance. The actual incidence is not well documented as the patient is usually asymptomatic and is incidentally diagnosed on imaging modalities like ultrasonography, Computed Tomography Scan or Magnetic Resonance Imaging. Hemiagenesis may be of either one lobe or both lobes with or without aplastic isthmus. We shall be reporting a case of 25year old man with normal T3, T4 and TFT levels was incidentally diagnosed with right sided hemiagenesis of thyroid with complete absence of isthmus. It is important to diagnose since it is highly associated with various thyroid abnormalities.

KEYWORDS: Congenital thyroid anomalies, hemiagenesis, thyroid, aplastic isthmus.

INTRODUCTION

Congenital anomalies of thyroid gland are a rare entity. The anomalies are an end result of abnormal descent or abnormal genesis of part of thyroid gland and not due to abnormal development. Agenesis or hypoplasia of one or both lobes of thyroid with or without isthmic agenesis is a rare congenital developmental anomaly having prevalence rate of only 0.2% in non-symptomatic children. In 40-50% cases, agenesis of isthmus may be noted.^[1]

In 1866, Handfield-Jones reported the first case of thyroid hemiagenesis.^[2]

The first endocrine gland to develop in embryo is the thyroid, beginning to form at around 4th week (24 days) post fertilization in the floor of primordial pharynx from a median endodermal thickening which gradually forms the thyroid primordium.^[3]

CASE REPORT

A 25year old male patient came to OPD with complaints of breathlessness since 10 days associated with low grade fever. Patient presented with history of road traffic accident 10 days back followed by trauma to left hypochondrium. He was advised HRCT thorax for further evaluation.

On HRCT thorax, incidentally right lobe of the thyroid was not visualised, hence USG neck was suggested to confirm.

USG neck was performed using high frequency linear transducer. On USG multiple, subcentimetric sized round to oval, heterogeneously hypoechoic lymph nodes with maintained fatty hilum at level III were noted bilaterally. Great vessels of the neck appeared normal. Submandibular and parotid glands appeared normal bilaterally. Left thyroid lobe measured approximately 4.8 cm (length) x 2.1cm (anterior-posterior) x 1.8 cm (transverse). Right lobe of the thyroid and isthmus were not visualised. He did not have a past history of any thyroid surgery. Hence a diagnosis of hemiagenesis of right thyroid lobe with isthmus was given. (Figure 1)

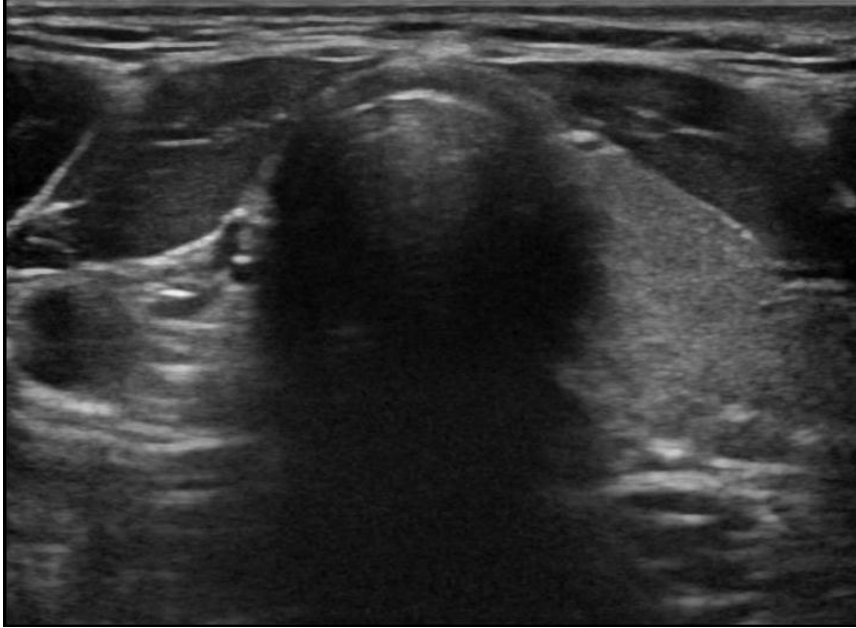


Figure 1: Ultrasonography transverse section of lower neck showing normal left thyroid lobe, absent right thyroid lobe and isthmus.

CT scan of neck revealed absence of right lobe of thyroid gland and isthmus. Left lobe of thyroid appeared normal. Rest of the findings were consistent with USG neck findings. (Figure 2 and 3)

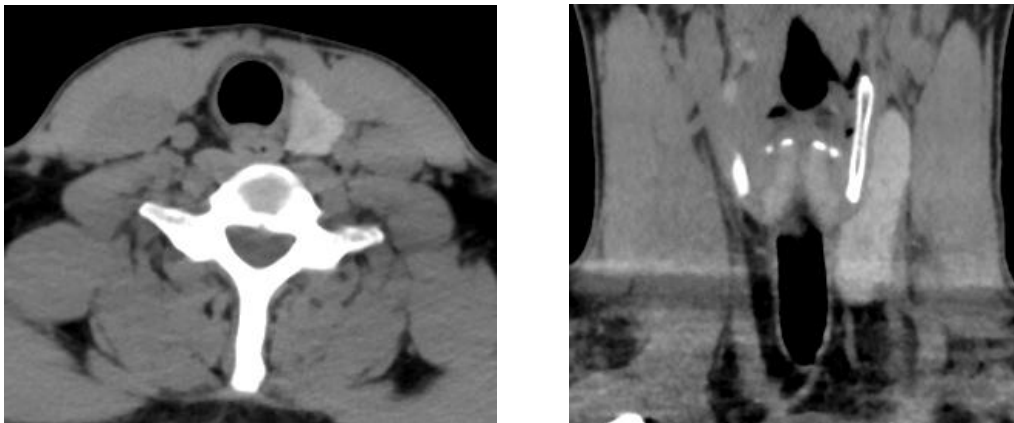


Figure 2: Non-contrast computed tomography scan axial and coronal section of lower neck showing normal left thyroid lobe, absent right thyroid lobe and isthmus.

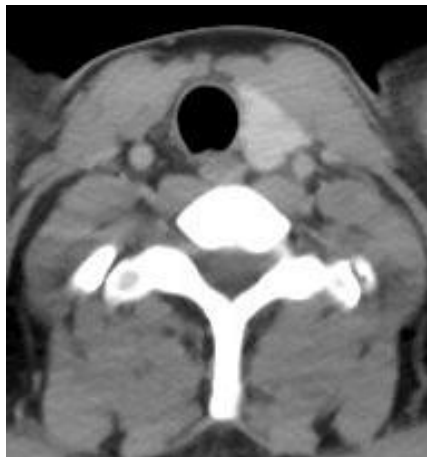


Figure 3: Contrast enhanced computed tomography scan axial section of lower neck showing normal left thyroid lobe, absent right thyroid lobe and isthmus.

DISCUSSION

Congenital anomalies of thyroid gland are a rare entity. In 1866, Handfield-Jones reported the first case of thyroid hemiagenesis.^[2]

The developmental anomalies are an end result of abnormal descent or abnormal genesis of part of thyroid gland and not due to abnormal development. Agenesis or hypoplasia of one or both lobes of thyroid with or without isthmus agenesis is a rare congenital developmental anomaly. Approximately 40-50% cases show agenesis of isthmus. Left thyroid gland hemiagenesis is more common as compared to right thyroid gland hemiagenesis having a left: right ratio of 4:1.^[1]

The true incidence and prevalence of this congenital anomaly is not well documented because hemiagenesis of thyroid gland is asymptomatic and is usually found incidentally. It is reported to have a prevalence rate of 0.025% to 0.16%.^[4] Thyroid hemiagenesis showed a female: male ratio of 3:1.^[5]

Development of thyroid gland occurs from a duct like endodermal invagination in the primitive pharynx between the 1st and 2nd pharyngeal pouches located dorsal to the aortic sac at gestational age of about 16-17 days. Ventrally it continues to extend with its distal tip showing accelerated proliferation, however being attached by the stalk to the pharyngeal floor which is also called as thyroglossal duct. The lumen of outpouching is obliterated by the progenitors of thyroid which later shows cords of cells within. There is lateral expansion of rudimentary thyroid tissue resulting into formation of bilobular appearance, which is its characteristic feature. The medial expansion of thyroid gland is associated with development of heart, thereby pulling the thyroid gland into its anatomical position at base of neck, anterior to pharynx.^[6]

Clinically, thyroid hemiagenesis can be diagnosed in any patient by palpation, however it has its own limitations. Thus, radiological imaging modalities play a vital role in diagnosis. Ultrasonography, CT scan and MRI, all help in confirmation of diagnosis. These modalities demonstrate absent, hypoplastic or ectopic thyroid tissue. Characteristic hockey stick sign is seen in patients of thyroid hemiagenesis on scintigraphy imaging.^[5]

Various clinical pathologies like unilateral or focal subacute thyroiditis; carcinomas of thyroid; Hashimoto's thyroiditis; a large solitary nodule compressing contralateral normal tissue may mimic as thyroid hemiagenesis. Thus radiological investigations play an important role in diagnosis.^[7]

CONCLUSION

Right sided hemiagenesis with absent isthmus in a male patient is a rare entity. However, the accurate incidence and prevalence of this anomaly is difficult to obtain in

asymptomatic patients. Screening of patients with imaging modalities like USG and CT scan and MRI if necessary, is important in diagnosis. Clinical and laboratory correlation should be considered post diagnosis of hemiagenesis of the thyroid and patient should be educated about its complications.

ACKNOWLEDGEMENT

We would like to thank our patient for his cooperation and willingness for additional investigations conducted to conclude our diagnosis.

REFERENCES

1. Tiwari PK, Baxi M, Baxi J, Koirala D. Right-sided hemiagenesis of the thyroid lobe and isthmus: A case report. *Indian J Radiol Imaging* 2008; 18: 313-5. PMID:19774189
2. Zachariah SK, Narayanan P, Mathew NV, Krishnankutty SL. Hemiagenesis of the right lobe and Isthmus of the thyroid presenting as multinodular goitre. *Res Endocrinol* 2014; 2014: 5.
3. Khatawkar AV, Awati SM. Thyroid gland - Historical aspects, Embryology, Anatomy and Physiology. *IAIM*, 2015; 2(9): 165-171.
4. Berker D, Ozuguz U, Isik S, et al. A report of ten patients with thyroid hemiagenesis: ultrasound screening in patients with thyroid disease. *Swiss Med Wkly* 2010; 140: 118-121. PMID:20033860
5. Melnick JC, Stenkowski PE. Thyroid hemiagenesis (hockey stick sign): a review of the world literature and a report of four cases. *J Clin Endocrinol Metab.* 1981; 52: 247-51. PMID:7462390
6. Pintar JE (2000) Normal development of the hypothalamic-pituitary-thyroid axis. In: Braverman LE and Utiger RD (eds) *Werner & Ingbar's The Thyroid. A Fundamental and Clinical Text.* Lippincott Williams & Wilkins, Philadelphia. &-19.
7. Erhamamcil S, Reyhanl M, Avci E. Thyroid Hemiagenesis with Hashimoto's Disease: A Case Report and Review of the Literature. *IJMMS* 2013; 1(3): 39-41.