

**PROSTATE CARCINOMA WITH METASTASIS TO THE CERVICAL LYMPH NODES
A RARE MANIFESTATION OF A COMMON DISEASE**

***Dr. Alharthi Adil Hamad MD, Dr. Patan Murthuza Khan MD, #Dr. Abaza Mohammed MD,
Dr. Alhazmi Abdulhameed Albarraq**

*Department of Medicine, #Department of Pathology,
King Fahad Armed Forces Hospital, P.O Box: 9862, Jeddah 21159 Saudia Arabia.

***Corresponding Author: Dr. Alharthi Adil Hamad**
Department of Medicine, King Fahad Armed Forces Hospital, P.O Box: 9862, Jeddah 21159 Saudia Arabia.

Article Received on 28/08/2016

Article Revised on 19/09/2016

Article Accepted on 09/10/2016

ABSTRACT

Patients presenting with generalized Lymphadenopathy for investigation is not uncommon in clinical practice. The common causes of generalized Lymphadenopathy are lymphomas, leukemias, tuberculosis, fungal infection and autoimmune diseases. Prostatic carcinoma presenting with generalized Lymphadenopathy is rarely described in the medical literature. A 60-year-old male patient was referred because of fever night sweats and weight loss with generalized Lymphadenopathy. Excisional biopsy of his left cervical lymph node revealed metastasis of prostatic adenocarcinoma. physicians should be aware of the of uncommon presentation of metastatic prostate carcinoma and include it in the differential diagnosis of generalized Lymphadenopathy.

KEYWORDS: Metastatic prostatic carcinoma. Generalized Lymphadenopathy. Metastatic Cervical Lymphadenopathy.

INTRODUCTION

Prostate Carcinoma is the second most common cause of cancer worldwide and the leading cause of death by cancer in males(Ref:1) Although Prostate cancer usually follows a predicted course with local invasion, followed by metastasis to the regional Lymph nodes and bone followed by lung liver brain and Epidural space.

Prostatic carcinoma may present with unusual ways and cause diagnostic challenge. one of the rare presentations of prostatic carcinoma is Metastasis to supradiaphragmatic Lymph nodes and cervical Lymph nodes which is described rarely in the medical literature. The present case demonstrates such a rare presentation of prostate cancer with metastasis to the supradiaphragmatic and

cervical lymph node. The pathogenesis of such presentation is discussed with review of Literature.

We present a 68 year old male a known case of Hypertension and benign prostatic hyperplasia referred to us because of a history of night sweats fever and weight loss with generalized Lymphadenopathy for further evaluation. On physical examination his blood pressure is 137/82 mm/Hg, a febrile, his general examination revealed multiple Lymph node masses in the left side of the neck and right inguinal region. the abdomen examination revealed soft lax abdomen with no organomegaly nor palpable Masses, rest of his systemic examination was normal. Laboratory investigations: Table,(1).

Table(1)

Variable	Value (in SI units)	Refrence
WBC	8 x10 ⁹	3.3-10.8
Hb	14 g/l	13.5-17.5
PLT	162 x10 ⁹	150-500
BUN	5.9 mmol/l	1.7-8.3
Serum Creatinin	101 mmol/l	62-106
LDH	136 u/l	135-225
ALP	195 u/l	40-129
PSA	>100 ng/ml	0-4

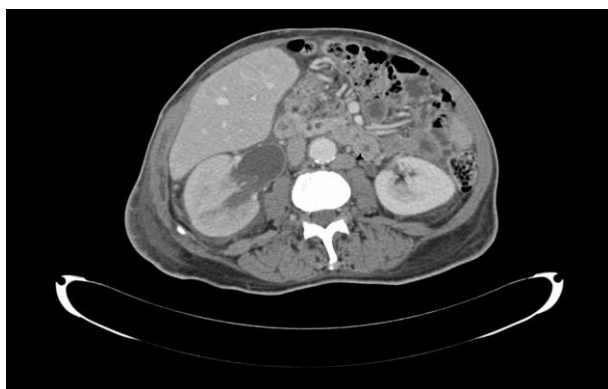CT abdomen shows multiple Lymph nodes retroperitoneal and Para-aortic deep pelvic region.(Image:1)

Ultrasound prostate showed the prostate volume 48.3 gm irregular contour with some foci of calcification.

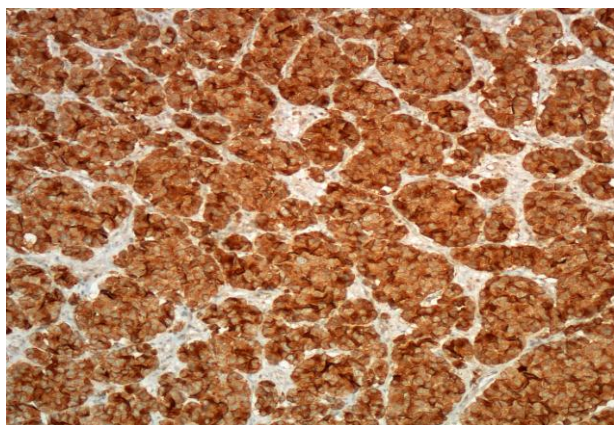
Excision biopsy of the left cervical lymph node showed metastatic prostatic carcinoma and immunochemistry for prostatic specific antigen(PSA) and AE3 where strongly positive image(2)

Trans rectal prostate biopsy shows poorly differentiated prostatic carcinoma Gleason score (4+5=9)

The patient presented with fever and night sweats weight loss and generalized Lymphadenopathy. His recent evaluation for prostatic symptoms revealed high PSA, abnormal Ultrasound report which gave a clue to the possibility of metastatic prostatic carcinoma spreading to the cervical lymph nodes. Cervical Lymph node biopsy was performed, Histopathology and immunochemistry confirmed the diagnosis of metastatic prostate adenocarcinoma. He was started on Androgen deprivation Therapy LHRH and referred to Urology for further treatment and follow up.



1. CT scan of the Abdomen with contrast enhancement showing Para-aortic lymph node (black arrow head image)



2. Biopsy specimen of the Left cervical lymph node showing strong immunohistochemical staining for PSA Immunoperoxidase.

DISCUSSION

The clinical presentation with systemic symptoms and generalized Lymphadenopathy is not uncommon in

clinical practice. The common causes of such presentation are lymphoma, leukemia Lymphoproliferative disease, Tuberculosis, Fungal infection and autoimmune diseases.

prostatic carcinoma metastasizing to mediastinal, supraclavicular and cervical Lymph nodes is uncommon (ref 2,3,4). The prostate carcinoma usually metastasis to regional Lymph nodes, bones, lung, brain, epidural space (ref 5). In a Large series of mediastinal masses only 6% appeared to be originally from Extra thoracic tumors and of those only 1% found originating from the prostate (Ref 3). Metastasis to the supraclavicular Lymph node are rare occurrence, only 0.33% of patients with prostatic cancer may have metastases to cervical lymph nodes(Ref 6). Supradiaphragmatic spread of prostatic cancer has been postulated to be hematological in rout. The direct spread from the tumor can gain access to the vertebral venous system and Batsons plexus and from there reach supradiaphragmatic lymphnodes(Ref 7,8).

The prostatic metastases to the Left supraclavicular lymph nodes are more common than the right side, as tumor cells lodge in the nodes which are close to the entry of the thoracic duct by the subclavian vein via retrograde spread (ref 9).

In conclusion distant metastases especially to cervical lymph nodes are rare at diagnosis of prostatic carcinoma. However like this case presented, In any male over 50 years of age with generalized Lymphadenopathy prostate carcinoma metastasis should be considered in the differential diagnosis.

Urological symptoms rectal examination, elevated PSA, Ultrasound prostate will give a clue to the diagnosis and lymph node histopathology and strongly positive PSA in immunohistology will confirm the diagnosis and facilitate the starting of treatment.

REFERENCES

1. World cancer report. World health organization pp chapter., 2014; 1.1.
2. Cho K.R and Epestien J.I: Metastatic prostatic carcinoma to supradiaphragmatic Lymph nodes: a clinic pathologic and immunohistochemical study: Am J Surg pathol., 1987; 11: 457-463.
3. Walsh Lm W, et. al. Mediastinoscopy for extrathoracic malignancies. Am. Otol. Rhin. Laryngo., 1982; 91: 659-665.
4. Lindell: M.M. et.al. Mediastinal metastasis from prostate carcinoma. J. Uro, 1982; 128: 331-334.
5. Oesterling J, Fuks Z, Lee C and Scher HI. Cancer of the prostate in cancer: Principles and practice of Oncology: 5th ed: (Devita V.T, Hellman S and Rosenberg SA eds), 1977; 1322-1386. Lippincott-Raven, Philadelphia.
6. Yardly MPJ, Investigation of cervical Lymphadenopathy presumed to be metastatic in

nature: A review of current clinical practice: J.Royal Coll Surg Edinb., 1992; 37: 319.

7. Batson O.V. The function of the vertebral viens and their role in the spread of metastasis. Clin ortho. Related res., 1995; 312: 4-9.
8. Melanham A.P et. al. Metastatic carcinoma : Incedence and location of unsuspected Lymphatic metastasis. J. Uroe., 1976; 115: 89-94.
9. Cody B: Lymph node metastasis indicators but not governors of survival. Itra Surg., 1984; 119: 1067-72.