

PHARMACOLOGICAL EVALUATION OF METHOTREXATE INDUCED  
HEPATOTOXICITY IN WISTAR RATSKumari Shalini<sup>1</sup> and Kumari Savita<sup>2\*</sup><sup>1,2</sup>Department of Pharmacology, CT Institute of Pharmaceutical Sciences, Shahpur, Jalandhar, India.

Corresponding Author: Savita Kumari

Department of Pharmacology, CT Institute of Pharmaceutical Sciences, Shahpur, Jalandhar, India.

Article Received on 03/09/2016

Article Revised on 23/09/2016

Article Accepted on 13/10/2016

## ABSTRACT

**Objective:** Drugs and chemicals are considered as one of the major causes for hepatotoxicity, inducing direct damage through multiple pathways including oxidative stress. Amlycure DS is a polyherbal hepatoprotective formulation indicated as liver protective. The present study was aimed to investigate the protective effect of Amlycure DS in methotrexate induced hepatotoxicity in wistar albino rats. **Method:** 30 rats of either sex were divided into 5 groups. Group-I serves as normal control receiving normal standard pellet diet and water *ad libitum*. Group-II serves as toxic control with methotrexate (100µg/kg *i.p.*) once daily for 40 days. Group-III serves as standard control receiving silymarin(63mg/kg) orally, daily for 40 days. Group IV and V received Amlycure DS at doses 1406 and 5608 mg/kg orally respectively for 40 days. At the end of 40 days methotrexate injection induces significant oxidative stress with rise in serum ALT, serum AST, BIT, BID, AST where as levels of serum albumin and serum protein were reduced, in addition Antioxidant glutathione, Catalase value was reduced. Treatment of rats with different doses of Amlycure DS (1406 and 5608 mg/kg) significantly ( $P<0.05$ ) ameliorated the alteration induced by methotrexate in oxidative stress and serum biochemical analysis. **Conclusion:** Based on these results, we conclude that Amlycure DS protects liver from oxidative damage induced by methotrexate.

**KEYWORDS:** polyherbal hepatoprotective, Amlycure DS.

## 1 INTRODUCTION

Methotrexate (MTX), as the most disease modifying anti-rheumatic drug used for Rheumatoid Arthritis (RA), has been available for clinical use since 1951.<sup>[1]</sup> It is one of the folic acid antagonists which is widely used in the therapy of various types of diseases such as cancers, immunologic disorders, psoriasis.<sup>[2]</sup> inflammation, arthritis biliary cirrhosis and Reiter's syndrome.<sup>[3]</sup> Methotrexate is actively accumulated in the liver where it is metabolized and stored in polyglutamated form. The major side-effect of chronic methotrexate administration is hepatotoxicity, which is characterized by fatty infiltration, inflammation, cellular necrosis and apoptosis, steatosis, fibrosis and cirrhosis.<sup>[3]</sup> Clinically, hepatotoxicity, which occurs in long-term use of methotrexate, remains one of the significant restrictions on its use in the doses desired<sup>[4]</sup>. This drug when used without follow up has many side effects like hepatotoxicity and bone marrow suppression. It seems that folic acid can reduce MTX side effects but it is not completely clarified. Clinicians use the drug frequently, so they would like to reduce its side effects especially its hepatotoxic effects.<sup>[5]</sup>

Studies have demonstrated that various anti-oxidants are protective against methotrexate hepatotoxicity<sup>[6]</sup>. 'Amlycure DS' is a poly-herbal formulation that ensures

the effective control of liver injury. Apart from hepatoprotective action, it also provides anti-oxidant, immuno-modulator, anti cholestatic, Anti-inflammatory, Cholagogue, Anti-fungal action.it brings progressive improvement in liver disorders and normalizes the biochemical parameters, histopathological pictures and relieves the clinical symptoms like loss of appetite, indigestion, nausea etc. The hepatoprotective & hepatocorrective actions of Amlycure D. S. make the formulation, the drug of choice for a variety of liver disorders. Amlycure D. S. is a Desired Strength, comprehensive polyherbal formula, in potent concentration of different vital herbs to exert potent corrective & protective effect in order to immediately check progression to severity and effectively restore liver functional parameters in severe liver disorders. It is used for therapeutic management of the hepatic diseases. Chemical examination of 'Amlycure D. S.' revealed the presence of flavonoids, tri-terpenoids, *saponins*, *tannins*, *steroids*, *proteins*, *amino acids* etc. It consist of many plants reported to have hepatoprotective activity such as *Occimum sanctum*.<sup>[7]</sup> *Picrorrhiza kurroa*.<sup>[7, 8]</sup> *Tephrosia purpurea*<sup>[9,10]</sup>. *Tinospora cordifolia* <sup>[11,12]</sup>, *Phyllanthus niruri*.<sup>[13,14]</sup> *Eclipta alba*<sup>[15,16]</sup> etc. These plants contains *secondary metabolites that promotes hepatotoxicity through different components such as saponins* (anti-oxidant and anti-microbial activity), *tannins* and

flavonoids (astringent, anti-microbial property and free radical scavengers), sterols & poly phenols (free radical scavengers, anti-oxidant and reduce lipid peroxidation).

## 2 MATERIALS AND METHODS

### 2.1 EXPERIMENTAL ANIMALS

Healthy adult Wistar rats of either sex, age between 4-5 months weighing 250-300g, procured from Panacea Biotech Ltd, Lalru (140501), India and were housed in polypropylene cage. They were maintained under standard laboratory conditions (temperature 25±2° C with 12/12h night/dark cycle), were fed with standard pellet diet (Sanjay Biological Museum, Amritsar) and water *ad libitum*. The study protocol was approved by the Institutional Animal Ethics Committee (IAEC) [Protocol no.: IAEC/2014/VI/0035(PCL-M)] of the Institute under the guideline of Committee for the Purpose of Control and Supervision on Experiments on Animals (CPCSEA), Ministry of Environment & Forests, New Delhi.

### 2.2 DRUGS

**Methotrexate injection** was purchased from Ipca laboratory Ltd. India, 'Amlycure DS' a polyherbal formulation was purchased from Aimil Pharmaceuticals India, Ltd and Silymarin was purchased from Micro labs Ltd. Reagent kits for assay of transaminases, ALP, total and direct bilirubin, cholesterol, HDL and LDL assay kit was purchased from ERBA Diagnostic Mannheim GmbH, (Germany). The work was done in accordance with the method prescribed in each diagnostic kit. **Thiobarbituric acid (TBA)** was obtained from Avarice Laboratories Pvt Ltd. (India), **Trichloroacetic acid (TCA)** from Thermo Fisher Scientific Pvt Ltd. (India).

### 2.3 PRELIMINARY PHYTOCHEMICAL SCREENING

Preliminary phytochemical screening of Amlycure DS was carried out to detect the presence of Glycosides, Flavonoids, Terpenoids, Alkaloids, Saponins, Tannins, Proteins, Amino acid, Carbohydrates, Steroids etc <sup>[17]</sup>.

### 2.4 EXPERIMENTAL HEPATOTOXICITY

Hepatotoxicity was induced in rats by single daily dose of methotrexate (100µg/kg/ip) for 40 days. Methotrexate injection is prepared by dilution of injection in injection for water. We used 5 ml of MTX (15 mg/1 ml) and diluted it in 99 ml of water for injection and then 1 ml of product was diluted in 9 ml of water for injection (100 µg/ml MTX). It was injected by insulin syringes <sup>[18]</sup>.

### 2.5 Evaluation of hepatoprotective activity

- 30 Wistar albino rats (either sex) will be used and divided into five groups, each containing six animals.
- Group I served as normal group and received standard pellet diet and water *ad libitum*.
- Group II served as negative control group and administered Methotrexate (100µg/kg i.p) according to standard procedure daily 40 days.

- Group III served as standard group received Silymarin (63 mg/kg po) for 40 days, and then After 4 hour of the induction of silymarin rats received Methotrexate once daily for 40 days.
- Group IV received pre treatment with test drug Amlycure DS (1402mg/kg) orally for 40 days, then after 4 hour of the induction of Amlycure DS rats received Methotrexate once daily for 40 days.
- Group V received pre treatment with test drug Amlycure DS (5608mg/kg) orally for 40 days, then after 4 hour of the induction of Amlycure DS rats received Methotrexate once daily for 40 days.

### 2.6 ASSESSMENT OF *IN-VIVO* BIOCHEMICAL ACTIVITY

At the end of the study after 40 days of experimental period, blood samples were collected by retro-orbital sinus puncture. Serum was separated by centrifuging of blood at 3000 rpm for 15 minutes using micro centrifuge and used for the enzyme level estimation of different markers enzymes.

#### 2.6.1 Assessment of liver function markers enzyme

The liver marker enzymes AST, ALT, ALP were assayed in serum using standard kits supplied from ERBA Diagnostic Mannheim GmbH, Germany. The results were expressed as IU/L.

#### 2.6.2 Protein determination

The levels of Total Protein and Albumin were determined in the serum of experimental animals by using the biuret method and the bromocresol green method, respectively. Kits purchased from ERBA Diagnostic Mannheim GmbH, Germany. The results were expressed as g/dl.

#### 2.6.3 Total and direct bilirubin determination

The levels of total and direct bilirubin were assayed in serum of experimental animals by using kits supplied from ERBA Diagnostic Mannheim GmbH, Germany. The results were expressed as mg/dl.

#### 2.6.4 HDL and LDL determination

The level of HDL and LDL were also estimated by using kits supplied from ERBA Diagnostic Mannheim GmbH, Germany. The results were expressed as mg/dl.

### 2.7 ASSESSMENT OF *IN-VIVO* ANTIOXIDANT ACTIVITY

*In-vivo* oxidative stress was assessed by measuring TBARS, catalase and glutathione at the end of the study. An accurately weighed piece of liver was homogenized in ice-cold potassium phosphate buffer (pH 7.5), connected to a homogenizer motor, to yield a 20% (W/V) tissue homogenate. The homogenate was centrifuged at 4000 r·min<sup>-1</sup> for 10 min at -4 °C to remove cell debris and nuclei. The resulting supernatant was stored at -80 °C for various antioxidants analyses. <sup>[19]</sup>

### 2.7.1 Determination of GSH, Catalase and TBARS

Hepatic GSH levels were estimated by a colorimetric method according to Lee & Jeong; 2002<sup>[20]</sup>. Catalase activities were determined by measuring the decrease in hydrogen peroxide concentration at 230 nm by the method of Beutler according to Cetinkaya *et al.*; 2006<sup>[21]</sup>. Hepatic lipid peroxidation levels were determined by measuring a thiobarbituric acid reactive substance (TBARS) level followed by Khanal *et al.*; 2009, Lee & Jeong; 2002.<sup>[20,22]</sup>

### 2.8 Histopathological examination

For microscopic evaluation of liver, rats were sacrificed by cervical dislocation at the end of experiment. Livers removed from the rats were frequently washed with saline solution and then fixed in 10% formaldehyde solution. Then liver tissue was embedded in paraffin and cut as a 4µm sections. After routine tissue preparation, haematoxylin and eosin stain was used to detect the

change in hepatic texture. Cover slips were mounted with premount and examined by light microscopy at 45X. Affected areas were examined histopathologically.<sup>[23]</sup>

### 2.9 STATISTICAL ANALYSIS

All the results were expressed as mean ± standard error mean (SEM). Data was analyzed by using two way ANOVA followed by Bonferroni post test and one way ANOVA by using Dunnett's multiple comparison test. P<0.05 was considered as statistically significant. All the statistical analysis of experimental data performs on Graph Pad Prism 5.00 software.

## 3 RESULTS

### 3.1 Preliminary Phytochemical Screening

The results of this preliminary phytochemical testing of formulation showed the presence of alkaloids, carbohydrates, flavonoids, glycosides, proteins, tannins, steroids and amino acids.

### 3.2 Physiological parameters

**Table 1.1: Effect of Methotrexate, Silymarin and Amlycure-DS on Body weight (g)**

S. No	Days	Group I	Group II	Group III	Group IV	Group V
1	Day 0	311.3±7.67	305.2±5.82	296.5±9.61	288.1±6.21	286.8±8.67
2	45 <sup>th</sup> Day	304.5±6.78 ***	251.3± 9.60	276.1±6.45 *	285.4±6.05 **	296.6±7.07 ***

Values are expressed as mean+ SEM, (n=6), the values with ( asterisk) \* indicates significant at p<0.05 probability, \*\* more indicates significant at p<0.01 probability, \*\*\* indicates highly significant at p<0.001 probability as compared to methotrexate treated group using two way ANOVA followed by Bonferroni post -test.

### 3.3 Serum parameters

**Table 1.2: Effect of Methotrexate, Silymarin and Amlycure-DS on different serum enzymes**

Parameters	Days	Group I	Group II	Group III	Group IV	Group V
ALT(IU/L)	Day 0	53.7±6.14	52.5±5.97	54.6±4.97	57.1±4.77	52.1±4.82
	Day 40 <sup>th</sup>	50.4±9.19***	116.6±3.86	97.7±5.85 *	94.4±6.04 *	51.0±4.61 ***
AST(IU/L)	Day 0	79.17±6.12	83.14±4.16	79.09±3.03	81.77±3.76	83.62±7.78
	Day 40 <sup>th</sup>	78.23±7.23 ***	160.01±5.79	138.3±11.6 *	132.9±4.34 *	82.26±7.08 ***
ALP(IU/L)	Day 0	70.0±2.81	68.7±6.13	65.9±1.90	68.1±1.52	65.8±3.98
	Day 40 <sup>th</sup>	77.3±3.82 ***	138.8±7.35	121.6±2.30 *	120.7±9.35 *	79.2±5.37 ***
TP(g/dl)	Day 0	7.88±0.39	7.87±0.32	7.90±0.13	7.72±0.18	7.89±0.08
	Day 40 <sup>th</sup>	7.35±0.52 ***	3.94±0.23	5.10±0.28 **	5.30±0.37 **	7.44±0.59 ***
Alb(g/dl)	Day 0	3.51±0.16	3.15±0.11	3.43±0.144	3.64±0.11	3.60±0.15
	Day 40 <sup>th</sup>	3.34±0.14 ***	1.38±0.24	2.08±0.26 *	2.28±0.15 **	3.31±0.19 ***
BID(mg/dl)	Day 0	0.24±0.05	0.21±0.04	0.21±0.04	0.20±0.03	0.29±0.03
	Day 40 <sup>th</sup>	0.32±0.06 ***	0.83±0.04	0.49±0.03 ***	0.44±0.04 ***	0.30±0.03 ***
BIT(mg/dl)	Day 0	0.27±0.05	0.27±0.04	0.29±0.03	0.26±0.06	0.27±0.04
	Day 40 <sup>th</sup>	0.26±0.05 ***	1.38±0.11	0.84±0.06 ***	0.64±0.11 ***	0.23±0.05 ***
HDL(mg/dl)	Day 0	28.5±3.07	27.1±1.96	29.6±1.97	27.8±1.42	29.1±2.27
	Day 40 <sup>th</sup>	26.6±3.92 ***	11.3±1.91	20.4±1.31 *	21.2±2.06 **	26.07±3.18 ***
LDL(mg/dl)	Day 0	70.5±3.50	73.0±3.50	75.55±3.71	68.31±2.48	72.03±2.85
	Day 40 <sup>th</sup>	65.1±3.71 ***	99.1±4.51	74.01±4.90 **	73.54±9.37 **	64.80±8.02 ***

Values are expressed as mean+ SEM, (n=6), the values with \*\* indicates significant at p<0.01 probability, \*\*\* indicates highly significant at p<0.001 probability as compared to methotrexate treated group using two way ANOVA followed by Bonferroni post -test.

## 3.4 Antioxidant parameters

Table 1.3: Effect of Methotrexate, Silymarin and Amlycure-DS on different antioxidants parameters

Parameters	Days	Group I	Group II	Group III	Group IV	Group V
Catalase	40 <sup>th</sup> Day	4.19±0.16***	1.05±0.18	2.82±0.26***	3.58±0.19***	4.03±0.11***
Glutathione	40 <sup>th</sup> Day	0.97±0.07***	0.27±0.03	0.63±0.07***	0.69±0.05***	1.02±0.08***
TBARS	40 <sup>th</sup> Day	0.62±0.03**	0.77±0.04	0.66±0.03*	0.65±0.02*	0.59±0.02***

Values are expressed as mean+ SEM, (n=6), the values with \* indicates significant at p<0.05 probability, \*\* indicates more significant at p<0.01 probability, \*\*\* indicates highly significant at p<0.001 probability as compared to methotrexate treated group using one way ANOVA followed by Dunnett's multiple comparison test.




Figure 1.1 At the end of 45<sup>th</sup> days, test drug Amlycure DS treated groups showed significant hepatoprotective effect as compared to methotrexate treated group with the effect being proportional to increasing dose of Amlycure DS. \* indicates significant at p<0.05 probability, \*\* indicates more significant at p<0.01 probability, \*\*\* indicates highly significant at p<0.001 probability as compared to methotrexate treated group.

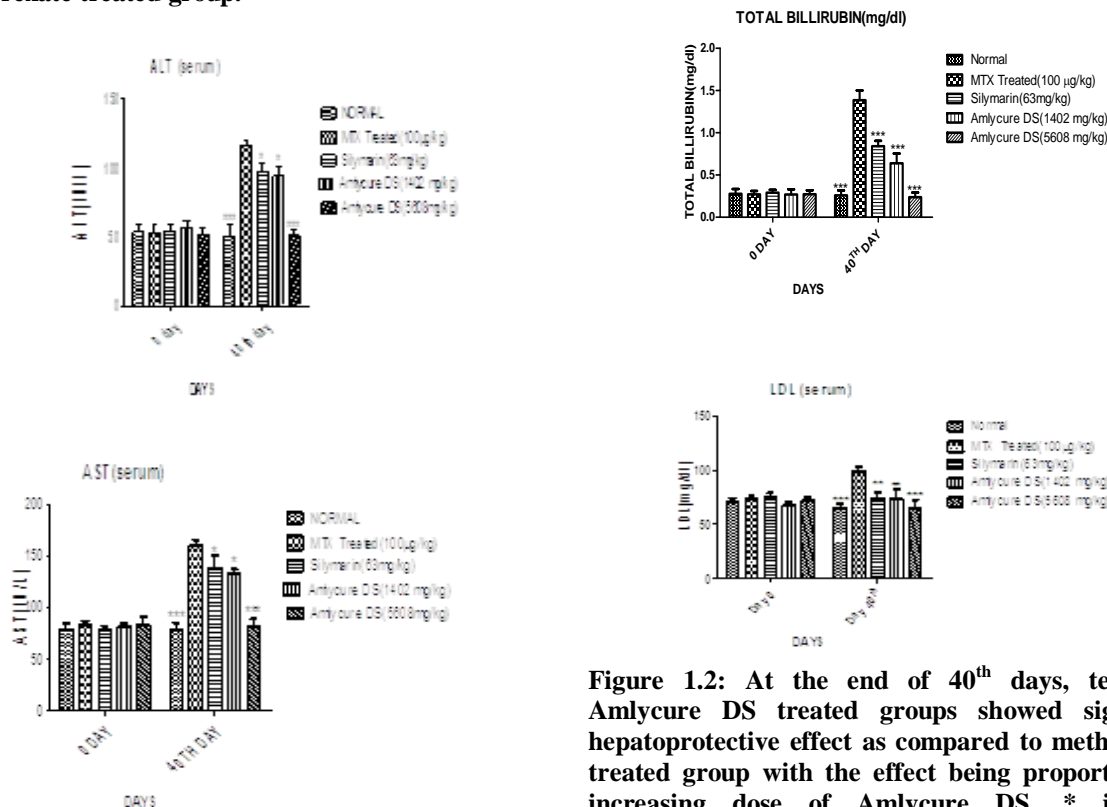


Figure 1.2: At the end of 40<sup>th</sup> days, test drug Amlycure DS treated groups showed significant hepatoprotective effect as compared to methotrexate treated group with the effect being proportional to increasing dose of Amlycure DS. \* indicates significant at p<0.05 probability, \*\*\* indicates highly significant at p<0.001 probability as compared to methotrexate treated group.

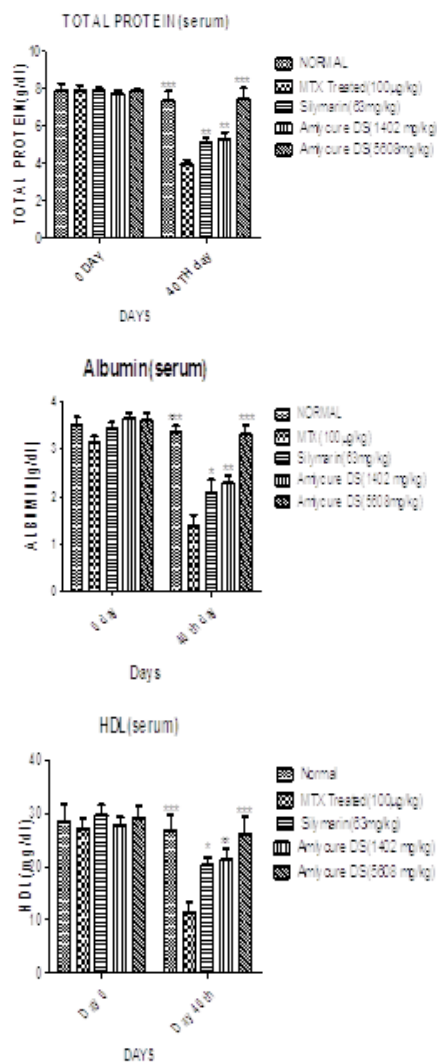


Figure 1.3: At the end of 40 days test drug Amlycure DS treated groups showed significant hepatoprotective effect as compared to Methotrexate treated group and response of Amlycure DS (5608mg/kg) treated group showed the values almost near to normal control group values. \* indicates significant at p<0.05 probability, \*\* indicates more significant at p<0.01 probability \*\*\* indicates highly significant at p<0.001 probability as compared to methotrexate treated group.

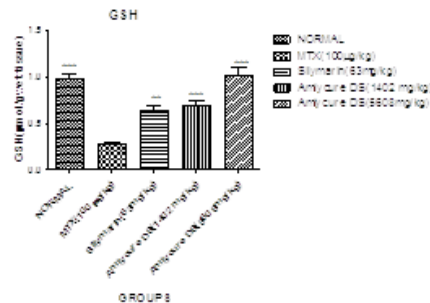
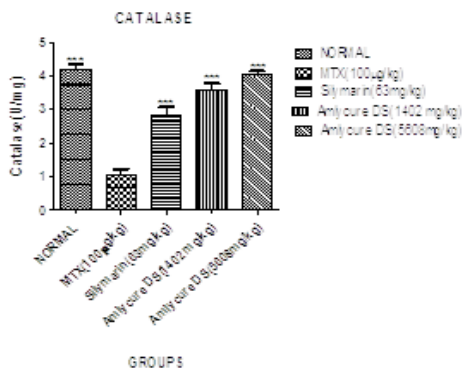


Figure 1.4: At the end of 40 days test drug Amlycure DS treated groups showed significant hepatoprotective effect as compared to Methotrexate treated group and response of Amlycure DS (5608mg/kg) treated group showed the values almost near to normal control group values. \*\* indicates more significant at p<0.01 probability, \*\*\* indicates highly significant at p<0.001 probability as compared to methotrexate treated group.

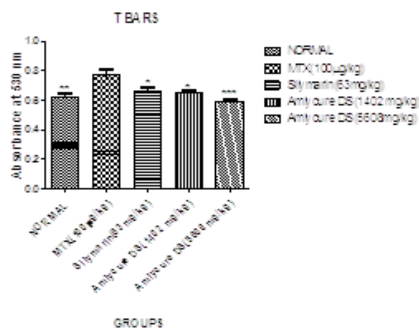


Figure 1.5: At the end of 40 days test drug Amlycure DS treated groups showed significant hepatoprotective effect as compared to Methotrexate treated group and response of Amlycure DS (5608mg/kg) treated group showed the values almost near to normal control group values. \* indicates significant at p<0.05 probability, \*\* indicates more significant at p<0.01 probability, \*\*\* indicates highly significant at p<0.001 probability as compared to methotrexate treated group.

**HISTOPATHOLOGICAL STUDY**

**Normal Control**

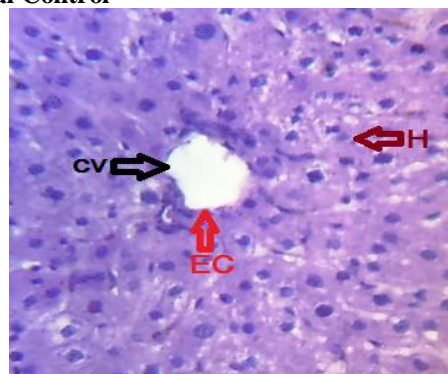


Figure 1.14: A photomicrograph of rat liver tissue of methotrexate treated group (100µg/kg) normal group showing normal central vein (CV), endothelial cell and hepatocytes (H) denoted by arrow at 45 X.

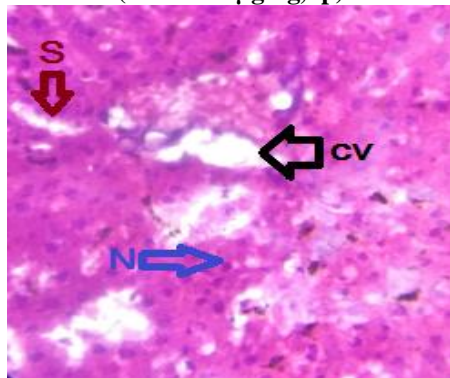
Negative Control (MTX 100 $\mu$ g/kg, ip)

Figure 1.15: A photomicrograph of rats liver tissue of methotrexate treated group (100 $\mu$ g/kg) showing the congestion in central vein (CV), sinusoidal dilation (S) and necrosis (N) at 45 X.

Positive Control (Silymarin 63 mg/kg)

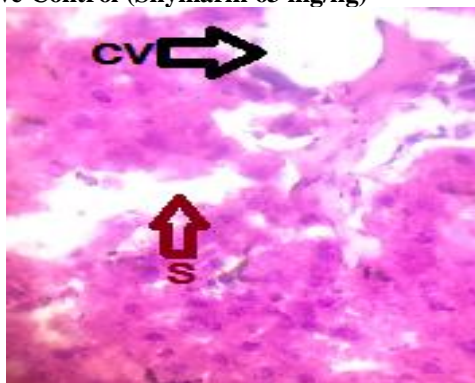

Figure 1.16: A photomicrograph of rats liver tissue of methotrexate treated group (100 $\mu$ g/kg) and silymarin (63 mg/kg) showing the recovery in central vein (CV) and sinusoids at 45 X.

Treatment Control (Amlycure DS 1406 mg/kg)

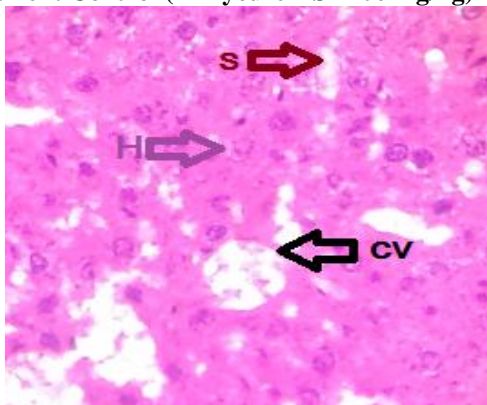


Figure 1.17: A photomicrograph of rats liver tissue of methotrexate treated group (100 $\mu$ g/kg) and Amlycure DS (1402 mg/kg) treated group showing the recovery in central vein (CV), hepatocytes (H) and sinusoids at 45 X.

Treatment Control (Amlycure DS 1508 mg/kg)

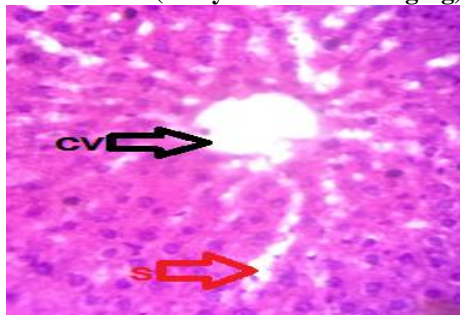


Figure 1.18: A photomicrograph of rats liver tissue of methotrexate treated group (100 $\mu$ g/kg) and Amlycure DS (5608 mg/kg) treated group showing the normalization in Sinusoids (S) and central vein (CV) at 45 X.

#### 4 DISCUSSIONS

Liver is one of the important organs of the body hence damage to the liver leads to sever pathological problems or to the end of life. Mitochondria are prominent targets for the hepatotoxicity of many drugs. Dysfunction of these vital cell organelles results in impairment of energy metabolism and an intracellular oxidant stress with excessive formation of reactive oxygen species and peroxynitrite. Oxidative stress is one major factor in etiology of liver injury mainly by kupffer cells thorough the action of substance endotoxin, which is released by certain gram -ve bacteria present in intestine, activate the kupffer cells to generate ROS & proinflammatory cytokines (TNF- $\alpha$ , IL-1) both of them leads to liver injury.<sup>[24]</sup> Methotrexate is well known animal models of hepatotoxicity. To measure the liver function serum ALT, AST, ALP, total and direct billirubin, cholesterol, HDL, LDL, serum protein, albumin and antioxidants parameters such as TBARS, catalase (cat), glutathione (GSH) are often regarded as reliable markers.

The preliminary phytochemical screening of poly herbal formulation "Amlycure DS" shows the presence of steroids, terpenoids, tannins, carbohydrates, alkaloids, protein, amino acids and flavonoids which proved Amlycure DS has anti-oxidant, antihepatotoxic, anticholestasis, immunomodulators and anti-viral activity.

Methotrexate used for cancer chemotherapy are well known to produce acute toxic side effects in multiple organ systems. The most common target organs are tissues that contain self renewing cell populations such as bone marrow, gastrointestinal tract, mucosal membranes, and hair follicles. The conversion of MTX to its major extracellular metabolite, 7-hydroxymethotrexate and takes place in the liver, where it is oxidized by a soluble enzymatic system. Inside cells, MTX is stored in a polyglutamated form. Long-term drug administration can cause accumulation of MTX polyglutamates and decreased folate levels. The presence of higher levels of polyglutamates causes a longer intracellular presence of the drug<sup>[25]</sup>. In the present study,

Methotrexate hepatotoxicity was induced by single daily i.p. injection of methotrexate (100µg/kg) for 40 days. Toxicity is characterized by marked elevation in circulating level of AST, ALT, ALP, total and direct bilirubin, cholesterol, LDL and decreased level of albumin, total protein and HDL.

Methotrexate induced group also shows decreased in the body weight of rats but Amlycure treated group (Group V) at dose of (5608 mg/kg) shows significantly increased body weight as compared to methotrexate group (Fig.1.1).

Apart from this, Amlycure DS at oral dose of 5608 mg/kg (Group V) significantly decreased the AST (Fig.1.3), ALT (Fig.1.2), ALP (Fig.1.10), Total and direct bilirubin (Fig.1.7,1.6), LDL (Fig.1.9) and increased the level of albumin (Fig.1.5), total protein (Fig.1.4) and HDL (Fig.1.8) as compared to methotrexate treated group (Group II), maintaining their value within normal range when compared to the standard Silymarin(63 mg/kg) treated group (Group III).

Although, all these results shows that Amlycure DS has hepatoprotective effect, and the mechanism involved in this might be due to presence of various phytoconstituents like glycoside, carbohydrates, alkaloids, tannins and flavonoids as these are already reported to have hepatoprotective action. "*Emblica officinalis*" is an ingredient of Amlycure DS which have strong antioxidant activity (DPPH scavenging) and high levels of hepatoprotection against tert-butyl hydroperoxide (t-BH) induced toxicity in hepatocytes (HepG2) cells<sup>[26]</sup>. "*Glycyrrhiza glabra*" contains glycosides. Glycyrrhizin having anti-inflammatory activity. It also reduces the alanine transaminase and aspartate transaminase values in serum. It has been proposed that glycyrrhizin has inhibitory effect on immune mediated cytotoxicity against hepatocytes and on nuclear factor (NF)-kappa B, which activates genes encoding inflammatory cytokines in the liver<sup>[27]</sup>. "*Eclipta alba*"(*Bhringaraj*) is one of the important ingredient of Amlycure DS. The loss of hepatic lysosomal acid phosphatase and alkaline phosphatase significantly restored by *Eclipta alba*<sup>[28]</sup>.

It is important to mention that oxidative stress is implicated in methotrexate toxicity in the liver and is an indicator of the damage that results from a change in the balance between oxidants and anti-oxidants<sup>[28]</sup>. In the present work, administration of methotrexate (100µg/kg) showed significant decreases in liver GSH. But Amlycure DS treated group (Group V) at oral dose of 5608mg/kg shows significant increased in the level of GSH (Fig.1.12). On the other hand, it was concluded that administration of methotrexate causes significant increase in liver content of TBARS of rats and Amlycure DS at oral dose of (5608 mg/kg) shows significant decreased level of TBARS (Fig.1.13).

However, methotrexate treated group (Group II) shows significant decreased in the level of Catalase in rat's tissue. On the other hand, Amlycure DS at dose of (5608 mg/kg) shows significant increased level of Catalase (Fig.1.11).

Anti-oxidative property of Amlycure DS prevents the liver damage caused by ROS. There are various herbal plants which are used in the preparation of Amlycure DS. Many of which have antioxidant and antihepatotoxic activity. "*Cichorium intybus*" commonly known as Chicory is an ingredient of Amlycure DS, having antioxidant property. Accordingly it has been used as ayurvedic medicine for gall and liver disturbances<sup>[11]</sup>. "*Andrographis paniculata*" is one of another ingredient of Amlycure DS reported to have antioxidant activity. It protects liver against the hepatotoxins by reducing the levels of the lipid oxidation product and by maintaining high levels of the reduced form of glutathione (GSH)<sup>[8]</sup>.

This was further proved by histological observation. The liver sections of vehicle control group (Group I) shows the normal liver structure (Fig 1.14). But methotrexate treated (Group II) rats has different biochemical changes i.e. necrosis, apoptosis and sinusoidal congestion (Fig 1.15). Amlycure DS at oral dose of 5608mg/kg is maintained as normal liver structure compared to methotrexate induced group (Fig 1.18). It was also observed that Amlycure DS shows better results as compared to standard drug Silymarin (63 mg/kg) (Fig 1.16).

## REFERENCES

1. Jwied AH. Hepatoprotective Effect of the Aqueous Extract of *Camellia sinensis* against methotrexate-induced liver Damage in rats. Iraqi J Pharm Sci. 2009; 18(2): 73-79.
2. Ozogula B, Kisaoglua A, Turanb MI, Altunerc D, Senerd E, Cetine N, Ozturke C. The effect of mirtazapine on methotrexate-induced toxicity in rat liver. Sci Asia. 2013; 39: 356-362.
3. Kremer JM. Toward a better understanding of methotrexate. Arthritis Rheum. 2004; 50: 1370-1382.
4. Desouza C, Keebler M, Namara DB, Fonseca V. Drugs affecting homocysteine metabolism: impact on cardiovascular risk. 2002; 62: 605-616.
5. Pandit A, Sachdeva T and Bafna P. Drug-Induced Hepatotoxicity: A Review. J Appl Pharm Sci. 2012; 02(05): 233-243.
6. Ozogula B, Kisaoglua A, Turanb MI, Altunerc D, Senerd E, Cetine N, C. Ozturkef C. The effect of mirtazapine on methotrexate-induced toxicity in rat liver. ScienceAsia. 2013; 93: 356-362.
7. Kumar CH, Ramesh A, Kumar JNS, and Ishaq BM. A review on hepatoprotective activity of medicinal plants. IJPSR. 2011; 2(3): 501-515.
8. Negi AS, Kumar JK, Luqman S, Shanker K, Gupta MM, Khanuja SPS. Recent Advances in Plant

- Hepatoprotectives: A chemical and biological profile of some important leads. *Medi Res Reviews*. 2008; 28(5): 746-772.
9. Ramamurthy MS, M Srinivasan. Hepatoprotective effect of *Tephrosia purpurea* in experimental animals. *IJP*. 1993; 25(1): 34-36.
  10. Khatri A, Garg A, Agrawal SS. Evaluation of hepatoprotective activity of aerial parts of *Tephrosia purpurea* L. and stem bark of *Tecomella undulata*. *J Ethnopharmacology*. 2009; 122(1): 1-5.
  11. Roy SD, Das S, Shil D, Dutta KN. Herbal Hepatoprotective Agents: A Review. *World J Pharma res*. 2012; 1(2): 87-99.
  12. Sharma V, Pandey D. Protective role of *Tinospora cordifolia* against lead-induced hepatotoxicity. *Toxicol Int*. 2010; 17(1): 12-17.
  13. Srirama R, Deepak HB, Senthilkumar U, Ravikanth G, Gurumurthy BR, Shivanna MB, Chandrasekaran CV, Agarwal A, and Shaanker RU. Hepatoprotective activity of Indian *Phyllanthus*. *Pharm Bio*. 2012; 50(8): 948-953.
  14. Husain S, Alam M A, Ahmed S, Quamri A, Khan M A. Hepatoprotective, anticancer & antiviral effects of Bhui Amla in unani medicine: an overview. *Journal of Medicinal Plants Studies*. 2014; 2(6): 50-52.
  15. Khin MM, Nyunt N, Tin KM. The protective effect of *eclipta alba* on  $ccl_4$  induced acute liver damage. *Toxicol and Appl Pharmacol*. 1978; 45(3): 723-28.
  16. Neeraja PV, Margaret E. *Eclipta alba* (L.) Hassk: A Valuable Medicinal herb. *Int J Current Pharma. Review and Research*. 2012; 2(4): 188-197.
  17. Shah BN, Nayak BS. *Experimental Pharmacognosy*. EDITION 1<sup>ST</sup> 2008; 191-200.
  18. Ghaffari AR, Noshad H, Ostadi A, Ghojzadeh M, Asadi P. The effects of milk thistle on hepatic fibrosis due to methotrexate in rat. *Hepat Mon*. 2011; 11(6): 464-468.
  19. Allam RM, Selim DA, Ghoneim IA, Radwan MM, Nofall SM, Khalifa AE, Sharaf OA, Toaima SM, Asaad MA, El-Sebakhy AN. Hepatoprotective effects of *Astragalus kahiricus* root extract against ethanol-induced liver apoptosis in rats. *Chinese J Nat Med*. 2013; 11(4): 0354-0361.
  20. Lee K.J, Jeong HG. Protective effect of *Platycodon radix* on carbon tetrachloride-induced hepatotoxicity. *Food Chem Toxicol*. 2002; 40: 517-525.
  21. Cetinkaya A, Bulbuloglu E, Kurutas EB, Kantarceken B. N-acetylcysteine ameliorates methotrexate-induced oxidative liver damage in rats. *Med Sci Monit*. 2006; 12(8): 274-278.
  22. Khanal T, Choi JH, Hwang YP, Chung YC, Jeong HG. Saponins isolated from the root of *Platycodon grandiflorum* protect against acute ethanol-induced hepatotoxicity in mice. *Food Chem Toxicol*. 2009; 47: 530-535.
  23. Abdul-Wahab FK & Jalil TZA. Study of Iraqi spinach leaves phytochemical and protective effects against methotrexate-Induced hepatotoxicity in rats. *Iraqi J Pharm Sci*. 2012; 21(2): 8-17.
  24. Sharma A, Sangameswaran B, Jain V, Saluja MS. Hepatoprotective activity of *Adina cordifolia* against ethanol induce hepatotoxicity in rats. *Int Cur Pharm J*. 2012; 1(9): 279-284.
  25. Jahovic N, Cevik H, Sehirli AO, Yegen BC and Sener G. Melatonin prevents methotrexate- induced hepatorenal oxidative injury in rats. *J. Pineal Res*. 2003; 34: 282-287.
  26. Dasaraju S, Gottumukkala KM. Current Trends in the Research of *Embllica officinalis* (Amla): A Pharmacological Perspective. *Int J Pharm Sci Rev Res*. 2014; 24(2): 150-159.
  27. Numazaki K. Effect of glycyrrhizin in children with liver dysfunction associated with cytomegalovirus infection. *Tohoku J ExpMed*. 1994; 172(2): 147-153.
  28. Sharma B, Sharma UP. Hepatoprotective activity of some indigenous plants. *Int j pharm tech res*. 2010; 2(1): 568-572.