

**ORGANOTOXICITY OF CADMIUM CHLORIDE ON THE FRESH WATER FISH  
LABEO ROHITA****\*Pawlin Vasanthi Joseph<sup>1</sup> and Nithya R.<sup>2</sup>**<sup>1</sup>Associate Professor and Head Department of Zoology Nirmala College for Women (Autonomous) Coimbatore-641018 Tamilnadu, India.<sup>2</sup>Research Scholar Department of Zoology Nirmala College for Women (Autonomous) Coimbatore-641018 Tamilnadu, India.**Corresponding Author: Dr. Pawlin Vasanthi Joseph**

Associate Professor and Head Department of Zoology Nirmala College for Women (Autonomous) Coimbatore-641018 Tamilnadu, India.

Article Received on 02/09/2016

Article Revised on 23/09/2016

Article Accepted on 13/10/2016

**ABSTRACT**

Toxicity is a measure of the degree to which something is toxic or poisonous. Several toxic substances entering into aquatic organisms daily may be very small and therefore, often no apparent or sudden effects are noticeable. However, this may result into impairment of many vital functions thus gradually affecting fish population indirectly. Cadmium is a rare element and is usually found as an impurity in ores of other metals principally those of zinc. The present study aims to determine the effects of sub chronic exposure of inorganic cadmium in the inland fish *Labeo rohita* by observing the histopathological changes in the vital organs like gills, liver and kidney. The LC50 at 96 hrs was determined by the Probit analysis method. The experiment was designed to expose the fish to different concentrations of cadmium chloride - 500µg/l, 700µg/l, and 900µg/l. One trough served as the control. Destruction to the gills is observed in certain areas. Pronounced changes like fusion of lamellae were observed. Severe damage and marked proliferation were seen in the liver. In the kidney a reduction in the size of the epithelial cells lining the tubules was found. The study can be considered as a good bio-marker to access the health status of fishes as well as the worsening status of aquatic bodies in relation to metallic contaminants particularly cadmium.

**KEYWORDS:** toxicity, cadmium, histopathology, proliferation, sub-chronic exposure, LC50 Contaminants.**INTRODUCTION**

Toxicity is a measure of the degree to which something is toxic or poisonous. Toxicity can refer to the effect on a whole organism, such as a human or a bacterium or a plant, or to a substructure such as a cell (cytotoxicity) or an organ (organotoxicity) such as the liver (hepatotoxicity). Several toxic substances entering into aquatic organisms daily may be very small and therefore, often no apparent or sudden effects are noticeable. However, this may result into impairment of many vital functions thus gradually affecting fish population indirectly. Hence, it is very essential to study the effect of long term exposure to sub lethal doses of toxicant.

The problem of appearance of toxic materials in water ecosystem is presently closely connected with increased concentration of different types of pollutants, which enter water bodies with industrial and communal waste waters. Evidence of toxic effect of heavy metals has been reported on fishes and populations eating contaminated food (Chang, 1996).

Cadmium is one of the heavy metals of current interest in environmental contamination studies since the

appearance in Japan of "itai- itai" disease, or acute human cadmiosis. Cadmium is a rare element and is usually found as an impurity in ores of other metals principally those of zinc. It is obtained as a by-product in the refining of zinc and copper but small quantities can remain as impurities in these and other metals. It is present in low concentrations in soils, sandstones and shale's from which it is leached only very slowly into surface water (Bowen, 1966) and is also present in some phosphate fertilizers.

Cadmium shows no indication of being an essential trace element in biological processes; on the contrary, it is highly toxic to a wide variety of living organism including man (Perry, 1976). It is considered hazardous to health at concentrations above 10 ppb in the drinking water supply.

Cadmium accumulates in the kidney, liver, and gills of freshwater fish (Chowdhury *et al.*, 2004). There is evidence that a high accumulation of cadmium in fish (Arctic char) might be the result of increased metal absorption in the gills from the water due to low alkalinity (Dallinger *et al.*, 1997). Cadmium exposure

leads to pathological conditions in various tissues including liver, testes, brain, nervous system, kidney, spleen and bone marrow (Jalaludeen *et al.*, 2012; Pantung *et al.*, 2008; Rangsayatorn *et al.*, 2004; Smith *et al.*, 1976).

The present study aims to determine the effects of sub chronic exposure of inorganic cadmium in the inland fish *Labeo rohita* by observing the histopathological changes in the vital organs like gills, liver and kidney.

## MATERIALS AND METHODS

Fresh water fish *Labeo rohita* (*rohu*) were collected from Aliyar dam near Pollachi, Coimbatore district, Tamilnadu. These fishes were transported to the laboratory in oxygenated polythene bags. The healthy fingerlings of *Labeo rohita* ranging in length 10-12 cm and weighing about 12-14g were used for the experiment. Fishes were acclimated for 2-3 weeks in a large plastic trough containing plain tap water.

Prior to acclimatization, fishes were bathed in 0.01% Potassium permanganate solution for 15 minutes for two consecutive days to neutralize possible external infectious pathogenic micro organisms. Fishes were fed with artificial feed twice a day.

The toxicant used in the static bioassay was cadmium chloride in tap water. Fingerlings were randomly distributed in plastic troughs of 20 liters capacity. One plastic trough served as the control and the other troughs were provided with different concentrations of cadmium chloride namely 4000 $\mu$ g/l, 4250  $\mu$ g/l, 4500  $\mu$ g/l, 4750  $\mu$ g/l, 5000  $\mu$ g/l, 5250 $\mu$ g/l. Ten fishes were placed in each trough and mortality was recorded after 24 hrs, 48hrs, 72hrs, and 96hrs. The LC<sub>50</sub> at 96 hrs was determined by the Probit analysis method (Finney 1971).

The experiment was designed to expose the fish to different concentrations of cadmium chloride - 500 $\mu$ g/l, 700 $\mu$ g/l, and 900 $\mu$ g/l. One trough served as the control. Each trough contained ten fishes and the experiment was conducted in triplicate. The duration of the experiment was 30 days.

Gill, liver and kidney tissue excised from fishes of the control and experimental groups were fixed with 10% formalin solution. After proper dehydration by graded alcohols, paraffin blocks were prepared and 4-5 $\mu$ m thick ribbons were cut in a Rotator Microtome and were stained with Eosin and Haematoxylin. The histopathological changes observed were photographed.

## RESULTS AND DISCUSSION

Cadmium compounds pose toxic effects on *Labeo rohita* which is evident by the findings of the present investigation and the calculated LC<sub>50</sub> value observed in the present study confirmed with the reports of Tripathi, 2014 (Table 2). Fish mortality may have resulted by the absorption and bioaccumulation of cadmium compounds

and greater activity of chemicals in the body of fishes (Kaushal and Mishra, 2013). The exact causes of death due to heavy metal poisoning are multiple and depend mainly on time and concentrations combination (Table 1).

## GILLS

The histology of gill in control fish (Fig 1) measures 2.0cm. The structure of the gill bears four pairs of gill lamellae and both the sides are supported by bony structure and primary lamellae. The secondary lamellae showed numerous channels of blood capillaries, each separated by single layered pillar cells when observed in vertical section. The laminar epithelium is thick followed by the basement membrane below where the pillar cells enclose blood spaces. Large number of mucous cells is present on the epithelial gill rakers, where as the primary lamellae have comparatively small and less number of mucous cells. In the 500 $\mu$ g/l treated fish measuring 2.0cm (Fig 2), gill showed minimum changes bulging of tips is seen in the lamellae. Fishes exposed to 700 $\mu$ g/l of cadmium show pronounced changes like fusion of lamellae (Fig 3). Destruction to the gills is observed in certain areas. In fishes treated with 900 $\mu$ g/l, gills measuring 2.5cm, the changes observed were severe showing destruction (Fig 4).

## LIVER

The histology of liver tissue in the control group showed liver cells with normal structure of hepatic cells (Fig 5). The connective tissue of liver expressed normal condition. Normal hepatic mass granulation was observed. A fragment of pale brown tissue measuring 1.2cm was observed in the control liver. In 500 $\mu$ g/l treated fish, the liver specimen consisted of a fragment of pale yellow brown tissue measuring 1.0cm (Fig 6). Proliferation of ducted cells appeared. In 700 $\mu$ g/l treated fish the hepatocytes were reduced in size (Fig 7). Spaces between the hepatocytes were observed. The histopathology of liver treated with 900 $\mu$ g/l cadmium chloride showed severe damage and marked proliferation. The liver tissue hepatocytes are reduced in size and large spaces were found between the hepatocytes (Fig 8).

## KIDNEY

The kidney is a vital organ of the body and proper kidney function is to maintain the homeostasis. It is one of the first organs to be affected by contaminants in the water (Thophon *et al.*, 2003). The control fish shows normal renal tissues (Fig 9). In the 500 $\mu$ g/l treated fish, the kidney shows cloudy changes in the renal tubules (Fig 10). The 700 $\mu$ g/l treated fish shows kidney with focal reduction in the size of the epithelial cells lining the tubules (Fig 11). In the 900 $\mu$ g/l treated fish there is reduction in the size of the epithelial cells lining the tubules (Fig 12).

The histological changes in fish is a noteworthy and promising field to understand the extent to which changes in the structural organization are occurring in

the organs due to environmental pollution. Cadmium exposure induces the appearance of granular deposits in the liver, atrophy of the proximal renal tubules, and increases the chloride cell turnover at the gills (Pratap and Wendelaar Bonga, 1993).

Gill hyperplasia, necrosis of intestinal mucosa, fat infiltration of liver parenchyma cells, destruction tubules were observed due to ammonia poisoning in the intestinal tract, kidney and gills of juveniles *Sparus auratus* (Zaki *et al.*, 1987).

Haniffa and Sundaradhanam, 1984 observed partial destruction of gill epithelium, pillar cells, acidophil mast cells, blood cells, blood capillaries, cartilage cells, and separation of epithelial layer of secondary lamellae from basement membrane. Mucous cells were destroyed and gill filaments were completely covered by the mucous layer in fishes treated with distillery effluent.

Through respiration, cadmium compounds circulate all over the body and may become one of the causes of death of animal due to hypoxia (Nilalohit *et al.*, 1981 and Maina, 1997). Cadmium inhibits the action of acetyl cholinesterase, causing death through paralysis of the respiratory muscle and depression of respiratory system (Hollis *et al.*, 2000).

Kabir and Begum, 1978 reported cytoplasmic degeneration, pyknotic nuclei in liver tissues, vacuolation in hepatic cells and rupture of blood vessels; degenerate hepatic cells and necrotic nucleic hypertrophy of hepatic cells and liver cord disarray, vacuolation of cytoplasm and necrosis, rupture of hepatic cell membrane and necrotic centro-lobular area.

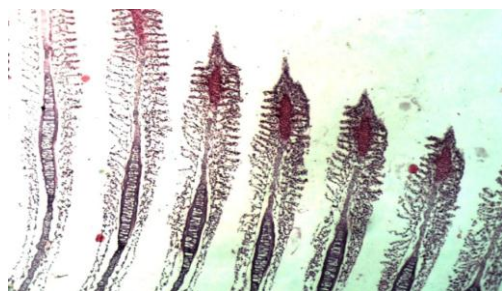Damage occurs in the proximal tubules of the kidney. For this reason, it is expected that the fishes will suffer from severe disturbances in water and electrolyte balance (Hawkins *et al.*, 1980).

**Table 1: Percentage (%) Mortality in *Labeo rohita* treated with different concentrations of Cadmium chloride.**

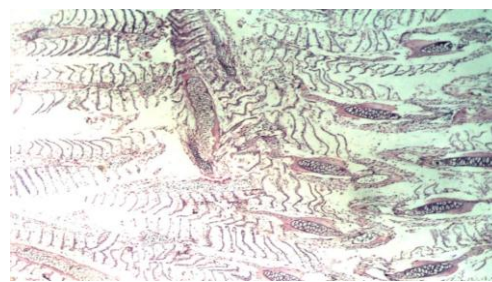
S. No	No. of fishes	Toxicant concentration in µg/l	Mortality in Test Animals	
			96Hrs	%
1	10	4000	0	0
2	10	4250	1	10
3	10	4500	2	20
4	10	4750	3	30
5	10	5000	5	50
6	10	5250	7	70

**Table 2: LC<sub>50</sub> value of cadmium chloride and the 95% confidence limit in *Labeo rohita***

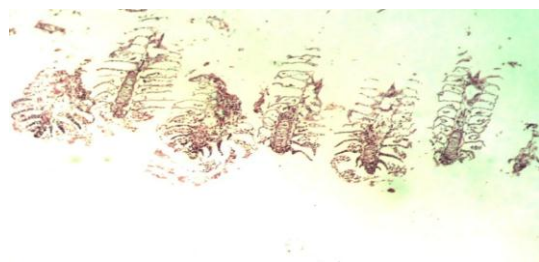
LC <sub>50</sub> (Log concentration)	95% Confidence		Probit Equation	Chi- Square
	Lower limit	Upper limit		
3.698	3.154	4.069	$y = 0.0093x - 0.0075$	0.0483



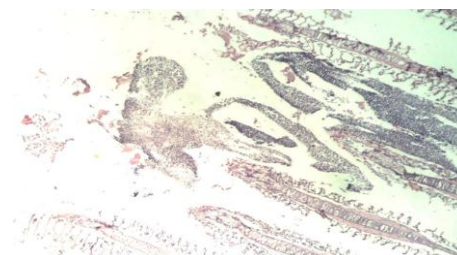
**Fig 1: Gill of control fish section showing normal gill. (HE× 100)**



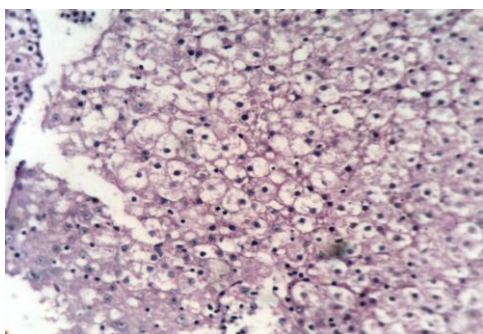
**Fig 3: Gill of 700µg/l cadmium chloride treated fish. (HE × 100)  
Gills show fusion of lamellae**



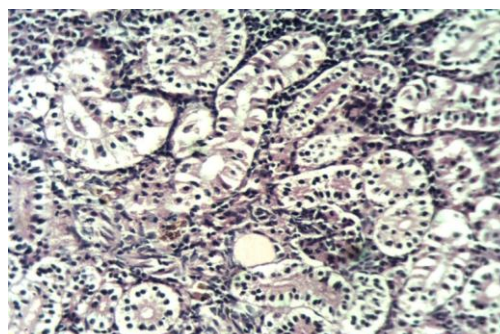
**Fig 2: Gill of 500µg/l cadmium chloride treated fish. (HE × 100)  
Section shows gills with bulging tips of lamellae.**



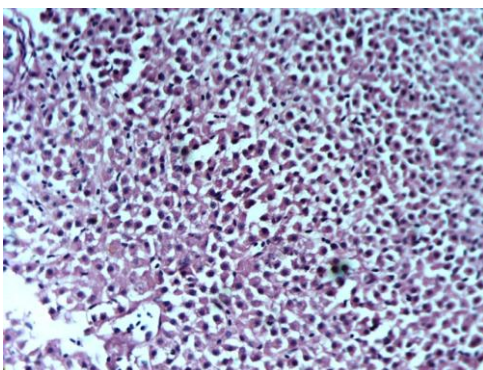
**Fig 4: Gill of 900µg/l cadmium chloride treated fish. (HE×100)  
Destruction of gills is observed**



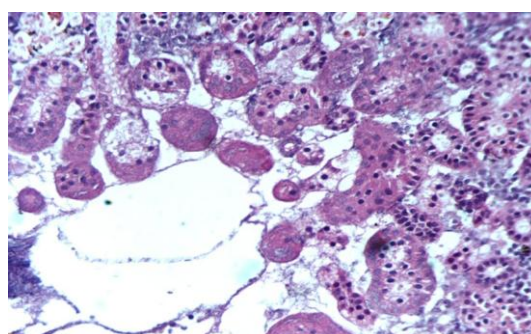
**Fig 5: Liver of control fish. (HE × 100)**  
Sections shows normal liver tissue



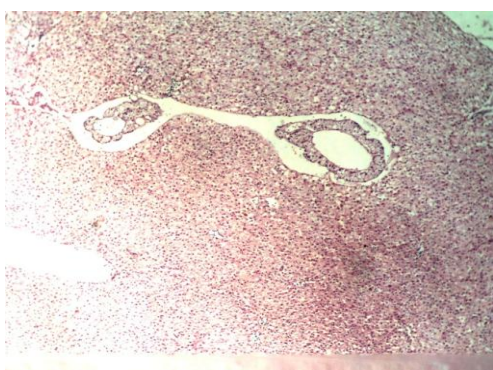**Fig 9: Kidney of control fish. (HE × 100)**  
Sections shows normal renal tissues



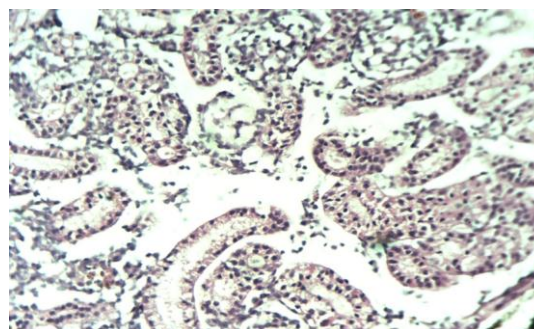
**Fig 6: Liver of 500µg/l cadmium chloride treated fish. (HE × 100)**  
Section shows bile duct proliferation



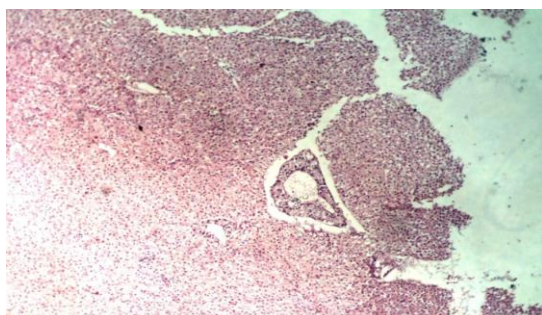
**Fig 10: Kidney of 500µg/l cadmium chloride treated fish. (HE × 400)**  
Section shows cloudy change in the renal tubules



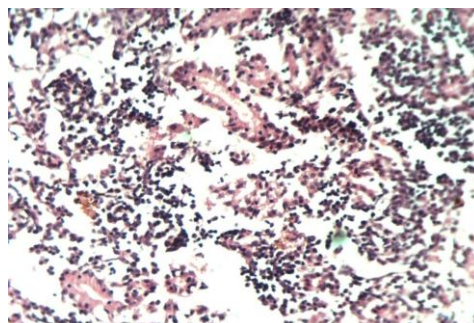
**Fig 7: Liver of 700µg/l cadmium chloride treated fish. (HE × 100)**  
Section shows hepatocytes reduced in size. Spaces are seen between hepatocytes



**Fig 11: Kidney of 700µg/l cadmium chloride treated fish. (HE × 400)**  
Section shows focal reduction in the size of the epithelial cells lining the tubules



**Fig 8: Liver of 900µg/l cadmium chloride treated fish. (HE × 100)**  
Hepatocytes are reduced in size and distinct spaces are seen between hepatocytes



**Fig 12: Kidney of 900µg/l cadmium chloride treated fish. (HE × 400)**  
Sections shows reduction in the size of epithelial cells lining the tubules

**CONCLUSION**

The histological changes in fish is a noteworthy and promising field to understand the extent to which changes in the structural organization are occurring in the organs due to environmental pollution. Heavy metal toxicant leads to many pathological changes in different tissues of fish exposed to cadmium chloride. The study can be considered as a good bio-marker to access the health status of fishes as well as the worsening status of aquatic bodies in relation to metallic contaminants particularly cadmium.

**ACKNOWLEDGEMENT**

The authors would like to thank Nirmala College for women, Coimbatore, for providing all the facilities to carry out the work.

**REFERENCES**

1. Chang LW. Toxicology of metals. CRC Press Inc. *Lewis Publishers*, 1996: New York, USA.
2. Bowen HJM. Trace elements in biochemistry. New York, *Academic Press*. 1966; 164: 179 and 209.
3. Perry HM, Thind G S, Perry EF. The biology of cadmium. *Med. Clin. North America*, 1976; 60: 759-769.
4. Chowdhury MJ, McDonald DG, Wood CM. Gastrointestinal uptake and fate of cadmium in rainbow trout acclimated to sub lethal dietary cadmium. *Aquatic Toxicology*, 2004; 69: 149-163.
5. Dallinger R, Margit Egg, Giinther KK, Rudolf Hofer. The role of metallothioneins in cadmium accumulation of Arctic char (*Salvelinus alpinus*) from high alpine lakes. *Aquatic Toxicology*, 1997; 38: 47-66.
6. Jalaludeen MD, Arunachalam M, Nandagopal S, Palanimuthu D, Raja M, Sundar S, Showket Ahmed Bhat. Histopathology of the Gill Liver and Kidney Tissues of the Freshwater Fish Tilapia Mossambica Exposed to Cadmium Sulphate. *International Journal of Advanced Biological Research*, 2012; 2(4): 572-578.
7. Pantung N, Kerstin G, Helander, Voravit Cheevapon. Histopathological Alternations of Hybrid Walking Catfish (*Clarias macrocephalus* x *Clarias gariepinus*) in Acute and Subacute Cadmium Exposure. *Environment Asia*, 2008; 1: 22-27.
8. Rangsayatorn N, Kruatrachue M, Pokethitiyook P, Upatham ES, Lanza GR, Singhakaew S. Ultra structure changes in various organs of the fish *Puntius gonionotus* fed cadmium-enriched cyanobacteria. *Environmental Toxicology*, 2004; 19: 585-93.
9. Smith L S, Bell G R. A practical guide to the anatomy and physiology of Pacific Salmon. *Fish. Mar. Serv. Misc. Spec. Publ.* 1976; 27: 14.
10. Finney D J. Probit Analysis, Cambridge University Press, 1971; London.
11. Tripathi DR. Sensitivity Evaluation in two Commonly Occurring Freshwater fishes after Intoxication with Cadmium. *Journal of Environmental Science, Toxicology and Food Technology*, 2014; 8(11): 102-105.
12. Kaushal BT, Mishra A. A comparative toxicity analysis of cadmium compounds on morphological and behavioural aspects in air breathing freshwater fish *Channa punctatus*. *International Journal of Science and Nature*, 2013; 2(2): 266-269.
13. Thophon S, Kruatrachuc M, Upathau E, Pokcthitiyook P, Sahaphong S, Jarikhuan S. Histopathological alterations of white seabass, *Lates calcarifer* in acute and subchronic cadmium exposure. *Environ. Pollut*, 2003; 121: 307-320.
14. Pratap HB, Wendelaar Bongaf SE. Effects of water-borne cadmium on plasma cortisol and glucose in the Cichlid fish, *Oreochromis mossambicus*. *Comparative Biochemistry and Physiology*, 1993; 95: 313-317.
15. Zaki MI, Saad S. Pathological Changes in different Species and Embryological Stage. *Bull Inst Oceanogr. Fish Cairo*, 1987; 13(1): 43-57.
16. Haniffa M, Sundravadhannam S. Effect of distillery effluent on Histopathological changes in certain tissues of *Barbus Stigma*. *Journal of Environ. Biol.*, 1984; 5(1): 57-60.
17. Nilalohit H, Beura B, Panigrahi. Toxicological effects of cadmium chloride on a freshwater fish, *Tilapia mossambica*, Peters and its ecological significance. *Peters. Arch. Toxicol*, 1981; 297-304.
18. Maina J N. The adaptive morphology of the gills of *Oreochromis alcalicus Grahmi*: A Cichlid fish which inhabits the hyper somatic, highly alkaline Kenyan lake Magadi. *Advance in Fish Research*, 1997; 2: 1-8.
19. Hollis L, McGeer JC, McDonald DG, Wood CM. Effects of long term sub lethal Cd exposure in rainbow trout during soft water exposure: implications for biotic ligand modelling. *Aquatic Toxicology*, 2000; 51: 93-105.
20. Kabir SMH, Begum R. Toxicity of Three Organ phosphorus Insecticides to Singhi Fish *Heteropneustes Fossilis* (Bloch). *Dhaka Univ. Stud. B*, 1978; 26: 115-122.
21. Hawkins WE, Tate LG, Sarphe TG. Acute effects of cadmium on the spot, *Leiostomus xanthurus* (teleost): tissue distribution and renal ultrastructure. *Journal of Toxicology and Environment Health*, 1980; 6: 283-95.