

**APLASIA OF LUNG - A CASE REPORT.****Dr. Prabhakar K.<sup>1</sup> and Dr. Spandana Peddareddy\*<sup>2</sup>**<sup>1</sup>HOD and Professor Department of General Medicine, Sri Devaraj Urs Medical College, Tamaka, Kolar-563101.<sup>2</sup>Post Graduate Student, Department Of General Medicine, Sri Devaraj Urs Medical College, Tamaka, Kolar-563101.**Corresponding Author: Dr. Spandana Peddareddy**

Post Graduate Student, Department Of General Medicine, Sri Devaraj Urs Medical College, Tamaka, Kolar-563101.

Article Received on 12/09/2016

Article Revised on 01/10/2016

Article Accepted on 23/10/2016

**ABSTRACT**

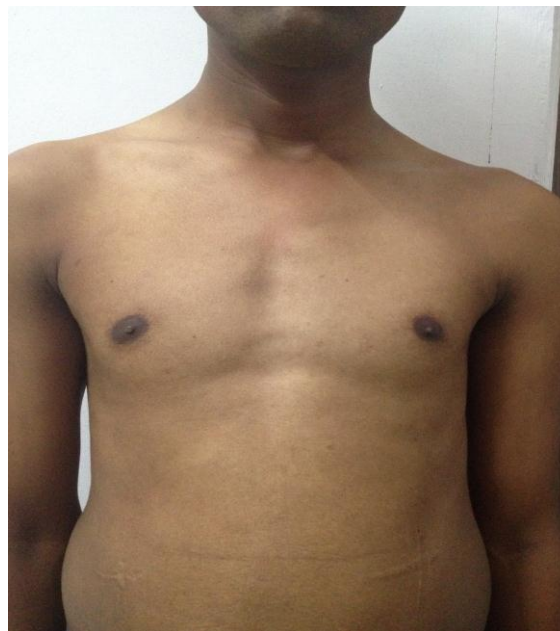The onset of symptoms in pulmonary agenesis is remarkably variable. Patients with one lung have been reported to survive well into adulthood without much complaint and they are detected in later years on routine CXR done for some other reasons.<sup>[2]</sup> Chest X-Ray findings of unilateral lung or lobar collapse with mediastinal shift towards the affected side may prompt differential diagnoses of suspected foreign body aspiration, mucus plug occlusion, and bronchial mass lesions. One of the rare conditions like pulmonary agenesis should also be considered. Lung aplasia is a congenital abnormalities in the development of the lungs in which there is complete absence of a lung. We report a 27 year old male with left sided pulmonary aplasia.

**KEYWORDS:** Unilateral lung, Lung aplasia, Lung agenesis.**INTRODUCTION**

Pulmonary agenesis, aplasia and hypoplasia are few congenital abnormalities of the lung which are rare. Pulmonary agenesis is the complete absence of the lung parenchyma, its vasculature, and its bronchus. Pulmonary aplasia is a common variant, which consists of a carina and the main-stem bronchial stump with absence of the distal lung.<sup>[1]</sup> Pulmonary agenesis and aplasia are rare abnormalities having an incidence

between 0.0034% and 0.0097%. It was first reported by de Pozzis in 1673, and more than 200 cases have been recorded since. From INDIA, the first case was reported by Muhamed in 1923 of left sided pulmonary agenesis in a medico legal autopsy.<sup>[3]</sup>

We present a case report of 27 year old male with unilateral pulmonary aplasia of left lung found incidentally when patient presented with palpitations.

**CASE REPORT****Fig no1: Picture showing patient's Chest.**

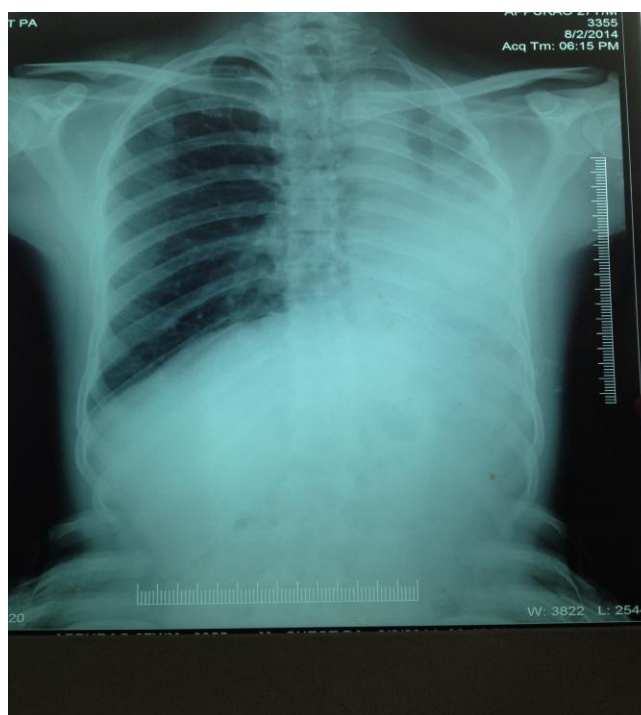
A 27 year old male patient presented with complaints of palpitations since 7 months. Patient initially consulted a cardiologist where 2D ECHO showed cardia to extreme left and mediastinal shift to left. CXR was taken which showed homogenous opacity on left side with hyperinflation of right lung. Collapse of left lung was suspected and patient was referred to physicians for further evaluation.

Patient gave history of recurrent episodes of cough with breathlessness since childhood for which he was treated locally as bronchial asthma. No history of exertional dyspnoea and he was able to perform day today activities without any difficulty. He is not a smoker or alcoholic. Patient was born out of a non consanguinous marriage. He was the fourth child out of seven siblings. Rest of the siblings were healthy.

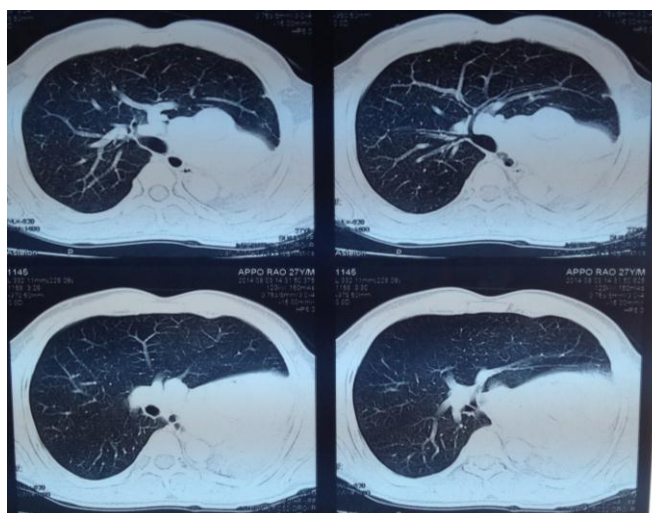
On examination of respiratory system, there was decreased movement of left hemithorax with shifting of trachea and apex beat to the left. Breath sound was absent in the left hemithorax and percussion note was dull in the left side.

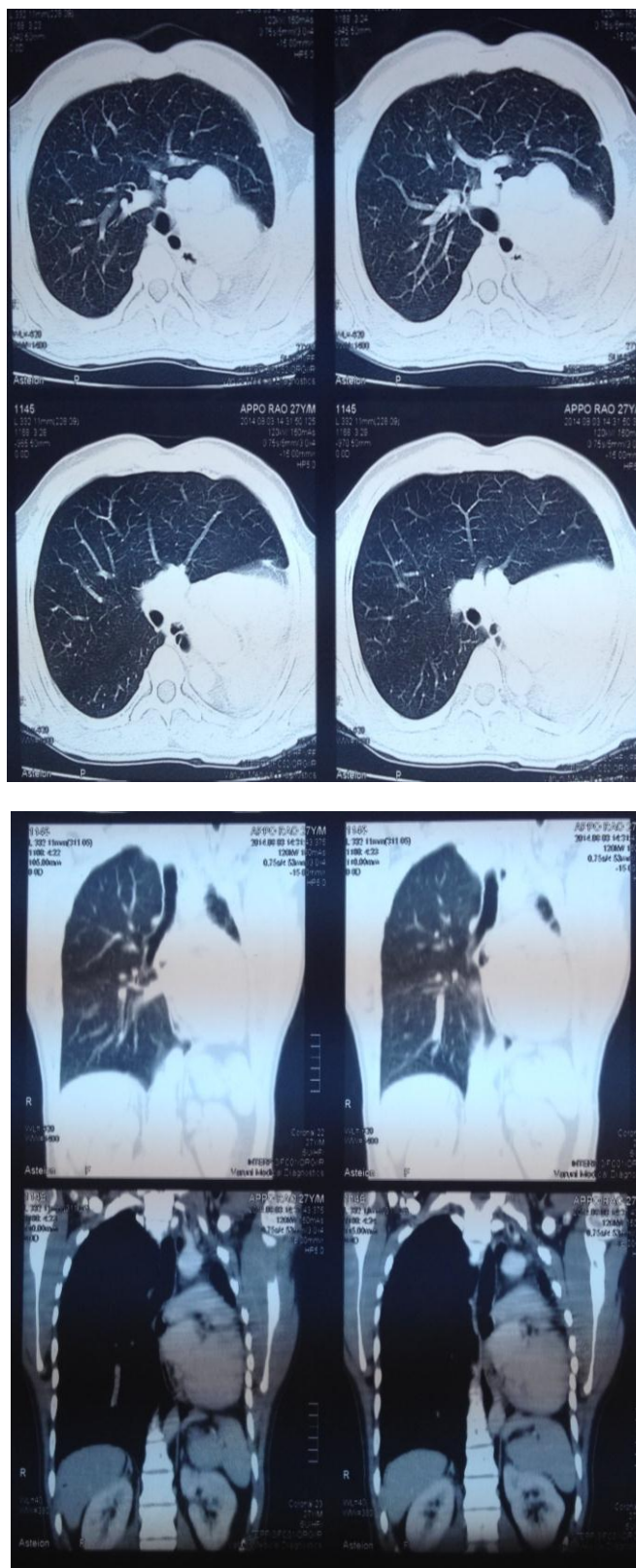
CT THORAX was advised which showed aplasia of left lung with hyperinflated right lung and herniation of right lung to left side, shift of mediastinal structures to left. Narrow left ribs were present. There was minimal atelectasis of lower lobe of right lung. The trachea showed division with small blind ending left main bronchus bud and absent left main pulmonary artery.

Pulmonary function tests showed early small airway obstruction. Spirometry showed mild restriction as FVC % < 80 and FEV1/FVC % 70.

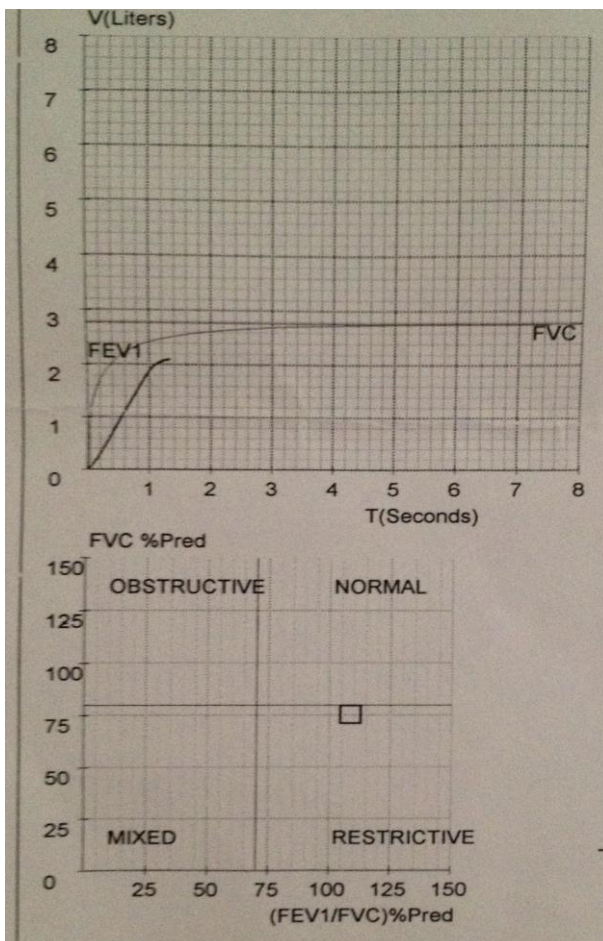
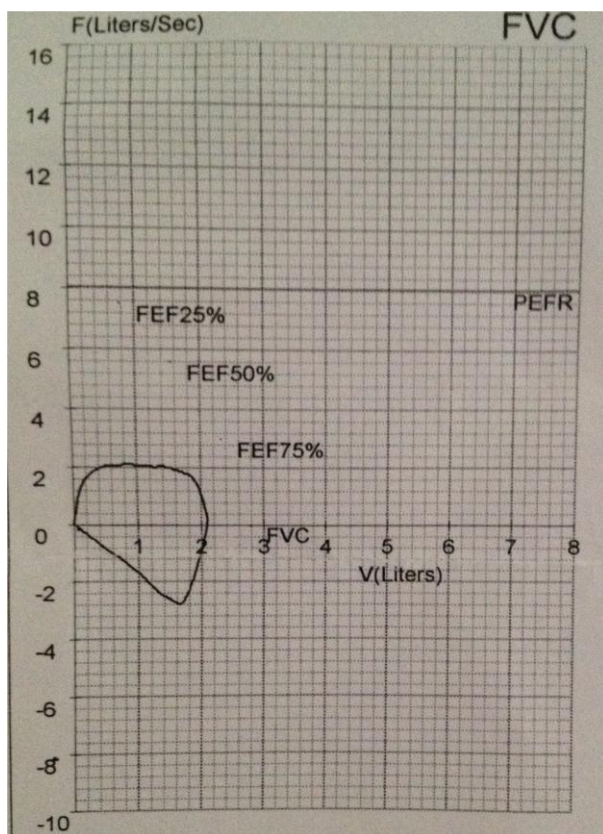


Chest x-ray PA view showing Left sided homogenous opacity with mediastinal shifting to leftside.





CT SCAN : Showing aplasia of left lung with herniation of right lung to left side.



PFT showing Early small airway obstruction and mild restriction.

## DISCUSSION

The first proposed classification of underdevelopment of the lung was introduced by Scheider in 1912 into three groups which have been modified by Boyden. Depending upon the stage of development of primitive lung bud, pulmonary agenesis is classified into three categories:

CLASS I: Agenesis – Total absence of bronchus and lung and no vascular supply.

CLASS II: Aplasia – rudimentary bronchus with complete absence of pulmonary parenchyma.

CLASS III: Hypoplasia – presence of variable amounts of bronchial tree, pulmonary parenchyma and supporting vasculature.<sup>[3]</sup>

Development of the bronchial tree takes place during 26th to 31st day of intrauterine life. Embryologically, these malformations correspond to a failure of development of the respiratory system from the foregut. Arrest at the stage of the primitive lung bud produces bilateral pulmonary agenesis. The respiratory anlage at a later stage may develop only unilaterally and lead to lung agenesis.<sup>[1]</sup>

Bilateral pulmonary agenesis is a rare malformation that may occur in anencephalic babies. The sole lung is larger than normal and this enlargement is true hypertrophy and not emphysema. They are generally sporadic, with only a few reports of these conditions occurring in siblings in an autosomal recessive pattern. They occur with equal frequency in both sexes and involve both lungs equally.<sup>[1]</sup>

Nearly 50% cases of pulmonary agenesis have associated congenital defects, involving cardiovascular (ventricular septal defect, atrial septal defect, tetralogy of Fallot), skeletal (hemivertebra, absent ribs), gastrointestinal (esophageal atresia, imperforate anus) and genitourinary (absent or polycystic kidney) system. The exact etiology of this condition is unknown, but genetic factors, viral agents and dietary deficiency of Vitamin A during pregnancy have been implicated.<sup>[2]</sup>

The onset of symptoms in pulmonary agenesis is remarkably variable. In many cases, presence of this anomaly usually comes to light during infancy because of recurrent chest infections, cardiopulmonary insufficiency or due to associated congenital anomalies. However, patients with one lung have been reported to survive well into adulthood without much complaint and they are detected in later years on routine CXR done for some other reasons.<sup>[2]</sup>

Many cases of pulmonary agenesis, aplasia and hypoplasia have been reported at different ages prenatally in newborns, infants, children and adults, even at 90 years of age. More common are unilateral agenesis, aplasia and hypoplasia which have few symptoms and non-specific findings and only one-third are diagnosed during life.<sup>[1]</sup>

Clinically the disease closely mimics collapse of the lung of affected side. Lung agenesis should be strongly suspected when CXR reveals bony asymmetry, opaque hemithorax with ipsilateral mediastinal shift and herniation of contralateral lung to the affected side. Respiratory difficulty is seen in these patients when there is tracheal deviation, in the presence of a clinically symmetric chest and patients having stumps. Diagnosis of pulmonary agenesis should be made on CXR, CT scan of thorax, bronchoscopy and pulmonary angiography.

Treatment in adults consists of control of recurrent infections, symptomatic treatment in form of expectorants and bronchodilators and management of other complications. Prophylaxis for respiratory syncytial virus, pneumococcus, influenza infections are recommended. No treatment is required in asymptomatic cases. Patients having stumps (hypoplastic bud) may require surgical removal if postural drainage and antibiotics fail to resolve the infection.<sup>[2]</sup>

Prognosis depends on two factors i.e the severity of associated congenital anomalies and secondly involvement of the normal lung in any disease process. Patients with right lung agenesis have a higher mortality than those with left lung agenesis because of compression of the tracheobronchial tree by the shifting of normally midthoracic structures into the right chest. If patient survives the first five years without major infection, a normal life span can be expected.<sup>[1]</sup>

## CONCLUSION

To conclude recurrent respiratory infections and radiologic evidence of opaque hemithorax, bony symmetry and herniation of normal lung to the affected side, along with associated congenital anomalies, are suggestive of pulmonary agenesis.

## REFERENCE

1. Shresta P, Poudel P, Shah PL. Unilateral pulmonary aplasia: A case report. *J.Nepal Paediatr Soc.* May-August 2010; 30(2): 116-18.
2. Ankan B, Debraberta S, Koushik S, Debraj J, Arnab M, Arpita B. A rare case of left lung agenesis in a female teenager. *Bangladesh Journal of Medical Science.* Oct 2012; 11(40): 350-52.
3. Arora V.K, Bedi R.S, Sarin N.K. *Lungindia.* June 1986; No.4: 171-73.