

## AN UNUSUAL CASE OF ATTEMPTED SUICIDE BY HANGNING: A CASE REPORT

Spoorti Vulavala\*<sup>1</sup>, Anitha Aswathanarayana<sup>2</sup> and Vidyasagar C. R.<sup>3</sup><sup>1</sup>Post Graduate Student, Department of General Medicine, SDUMC, Kolar.<sup>2</sup>Assistant Professor, Department of General Medicine, SDUMC, Kolar.<sup>3</sup>Associate Professor, Department of General Medicine, SDUMC, Kolar.**\*Corresponding Author: Dr. Spoorti Vulavala**

Post Graduate student, Department of General Medicine, SDUMC, Kolar.

Article Received on 21/09/2016

Article Revised on 11/10/2016

Article Accepted on 31/10/2016

**ABSTRACT**

Hanging has become the second most common method of attempted suicide especially among adolescents. Asphyxia, venous occlusion and arterial occlusion are believed to be the major factors contributing to death in non-judicial hanging. Brain perfusion is diminished in all suicide attempts by hanging. It sometimes causes cerebral infarction and results in poor outcome. Near hanging injury or strangulation injury is one of cause of carotid artery dissection (CAD). CAD is rare, occurring spontaneously or secondary to trauma. CAD has been often missed in cases with few symptoms, it is increasing in young people in relation to the recent increase of suicide attempts by hanging. We report an unusual case of unilateral carotid artery (CAD) dissection secondary to complete hanging in a 24-year female patient treated by medical management. Carotid artery dissection is to be considered as one of the possibility in cases of hanging. Survivors often recover fully and poor central nervous system function in the field (Glasgow Coma Scale score of 3) may not presage poor outcomes. Therefore, aggressive treatment in hanging victims is warranted regardless of the initial neurologic findings.

**KEYWORDS:** Hanging, carotid artery dissection, cerebral infarction, Glasgow Coma Scale.**INTRODUCTION**

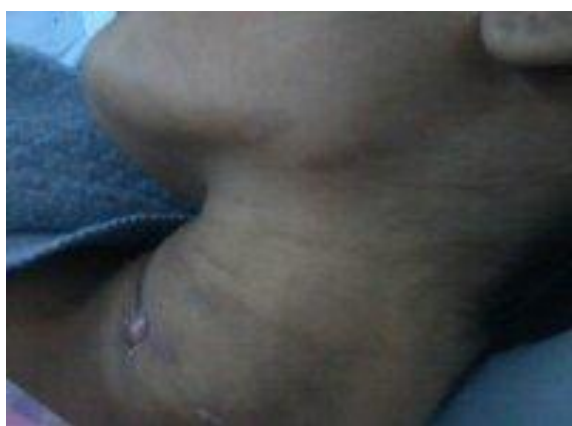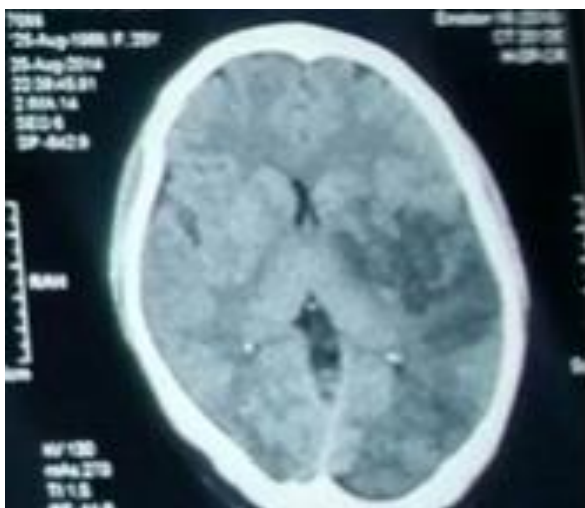
Human suicidal behaviour has always been a source of dread and wonder to mankind and its history goes back at least to the earliest human records. Hanging has become the second most common method of attempted suicide among adolescents, but there is little relevant epidemiologic or outcome data in the trauma literature. The thought of hanging oneself may come progressively or as an impulse. In India suicide by hanging was the first most commonly adopted mean of committing suicide i.e.41.8% in the year 2014 which increased from 37.0% in 2012. Hanging is the most preferred method of suicide along with consumption of poisons.<sup>[1]</sup> Asphyxia, venous occlusion and arterial occlusion are believed to be the major factors contributing to death in non-judicial hanging.<sup>[2]</sup>

Near hanging injury or strangulation injury is one of cause of carotid artery dissection. Carotid artery dissection (CAD) is rare, occurring spontaneously or secondary to trauma. Although CAD has been often missed in cases with few symptoms, it is increasing in young people in relation to the recent increase of suicide attempts by hanging.<sup>[3]</sup>

We report an unusual case of attempted suicide by hanging.

A 26-year-old woman was brought to emergency department with alleged history of hanging. She was brought unconscious and her pulse and respiration were weak. (Glasgow Coma Scale score was 3) She was immediately intubated and put on ventilator support. Ligature mark is present over left side of neck. On examination, paucity of movements of right upper limb and lower limb with painful stimuli is noticed within 24 hours. Left Horner's syndrome was present. She had no other co-morbid illnesses. CT brain plain showed parietooccipital infarct with midline shift of 0.8mm. Other blood investigations were all normal. Carotid Doppler showed left common carotid artery dissection. In view of clinical features and radiological findings, diagnosis of left common carotid artery dissection(CCAD) with artery to artery embolization is made.

We considered that cerebral infarction was caused by artery-to artery embolism from the left common carotid artery (CCA) dissection. Left frontotemporoparietal decompressive craniotomy was done in emergency. Patient was on ventilator support for 12 days. She gradually improved with anticoagulants and physiotherapy.



## DISCUSSION

The most common causes of blunt carotid injury are: 1) hyper-extension of the carotid vessels over the lateral articulation of C1-C3 at the base of the skull; 2) a direct blow to the artery; 3) basilar skull fractures involving the petrous bone or sphenoid portions of the carotid canal. Based on the nature of the injury, the traumatic event may cause intimal disruption, pseudo-aneurysm, dissection and/or thrombosis. Moreover, the lesion can evolve despite a small intimal injury.<sup>[4]</sup> These mentioned changes in carotid arteries are evident due to traction and direct pressure of the ligature on the neck. The acting pressure of ligature probably leads to fixation and deformation of the part of artery below the ligature to the deeper tissue structures of the neck. Section of the artery below the point of its fixation due to pressure of ligature is exposed to traction forces that lead to downward stretching of this part of the artery. A combination of forced compression of the artery and its longitudinal stretching could be the most frequent mechanism leading to occurrence of tears in the intimal layer of carotid arteries in hanging deaths. The sub intimal haemorrhage and perivascular congestion appears to be more due to direct trauma due to pressure of ligature, whereas intimal tear and disruption of intimal layer from medial layer are the result of traction forces. So these findings in carotid arteries are possible due to direct and indirect trauma in the form of crushing and traction forces.<sup>[5,6,7]</sup>

The most common presenting neurologic symptoms of CCAD were hemiparesis, decreased consciousness, headache/neck pain, aphasia and monocular field deficit. The most frequently reported neurosonographic findings included a double lumen, mural thrombus, intraluminal hyperechoic/isoechoic lesion and intimal flap. Most cases of CCAD were subsequently confirmed with conventional angiography, computed tomography angiography, or magnetic resonance angiography. Treatment differed based on etiology; anticoagulation was used most commonly for spontaneous CCAD and surgical repair was most often done for traumatic and aortic dissection-associated CCAD. Prognosis was generally good; the majority of patients achieved complete clinical recovery. Carotid Doppler is a widely accessible, rapid and non-invasive technique for diagnosing CCAD. Common carotid artery dissection (CCAD) is a rare and poorly characterized cause of ischemic stroke.<sup>[8]</sup>

In general, CAD has been treated medically, especially in asymptomatic cases. Heparin was continued for about one week and followed by oral anticoagulant with warfarin for three to six months. When frequent transient ischemic attack or cerebral infarction occurs, surgical treatment should be considered.<sup>[9,10,11]</sup> Surgical treatment includes interposition of the saphenous vein graft, extracranial to intracranial arterial bypass and carotid endarterectomy.

## CONCLUSION

Carotid Artery Dissection is to be considered as one of the possibility in cases of hanging. Survivors often recover fully and poor central nervous system function in the field (Glasgow Coma Scale score of 3) may not presage poor outcomes. Therefore, aggressive treatment in hanging victims is warranted regardless of the initial neurologic findings.

## REFERENCES

1. National Crime Record Bureau. (online) 2015 (accessed on 2015 Jul 02; p.192-208. Available from:RL;http://ncrb.nic.in/ADS/2015/suicide-02.
2. Iserson KV. Strangulation: a review of ligature, manual and postural neck compression injuries *Ann Emerg Med*, 1984; 13: 179–185.
3. Schievink WI, Mokri B, Whisnant JP. Internal carotid artery dissection in a community, Rochester, Minnesota, 1987-1992. *Stroke*. 1993; 24: 1678–1680.
4. Cothren CC, Moore EE, Biffl WL, Ciesla DJ, Ray CE Jr, Johnson JL, Moore JB, Burch JM: Cervical spine fracture patterns predictive of blunt vertebral artery injury. *J Trauma*, 2003; 55(5): 811-813.
5. Vinay Kumar M.S. Histopathological study of carotid trauma in strangulation deaths. *J Indian Acad Forensic Med*. April-Jun 2013; 35(2): 102-105.
6. Petr Hejna. Amussat's sign in hanging –A prospective autopsy study. *J Forensic Sci*. Jan 2011; 56(1): 132-35.

7. Dattatray Ghodake, Shailesh Mohite, Heena Desai. Histopathological Study of Carotid Arteries in Deaths due to Hanging. *Medico-Legal Update*, 2014; 14: 82-85.
8. Victor Zach, Svetlana Zhovtis et al. *Journal of Stroke and Cerebrovascular Diseases*, 2012; 21(1): 52-60.
9. Benjjani GK, Monsein LH, et al. Treatment of Symptomatic Cervical Carotid Dissection with Endovascular Stents. *Neurosurgery*. 1999; 44: 755–761.
10. Malek AM, Higashida RT, et al. Endovascular Management of Extracranial Carotid Artery Dissection Achieved Using Stent Angioplasty. *Am J Neuroradiol*. 2000; 21: 1280–1292.
11. Uno M, Ueda S, et al. Management and long-term follow-up results in patients with carotid artery dissection. *No Shinkei Geka*. 1997; 25: 417–423.