

**A CONVULSIVE SEIZURE AFTER NORMAL DELIVERY**

Mounir Moukit\*<sup>1</sup>, Imane Bensaleh<sup>1</sup>, Fatimazahra Ait El Fadel<sup>1</sup>, Jaouad Kouach<sup>1,2</sup>, Driss Moussaoui Rahali,<sup>1,2</sup>  
Mohammed Dehayni<sup>1,2</sup>

<sup>1</sup>Department of Obstetrics and Gynecology, Military Training Hospital Mohammed V, Rabat, Morocco.

<sup>2</sup>Faculty of Medicine and Pharmacy, University Mohammed V, Rabat, Morocco.

\*Corresponding Author: Dr. Mounir Moukit

Department of Obstetrics and Gynecology, Military Training Hospital Mohammed V, Rabat, Morocco.

Article Received on 04/10/2016

Article Revised on 25/10/2016

Article Accepted on 14/11/2016

**ABSTRACT**

The association between pregnancy and rapid growth of meningioma has long been appreciated. In pregnant women, a history of chronic headache and convulsive seizures should alert the attending physician to its potential and prompt further radiologic investigation to confirm the diagnosis. We report a case of 35 years old woman, having a history of chronic headache, admitted for convulsive seizure appeared 2 hours after normal delivery. Brain computed tomography scan was performed objectifying extra-axial frontal lesion in favor of intracranial meningiomas.

**KEYWORDS:** chronic headache; delivery; convulsive seizures; meningioma.

**INTRODUCTION**

The incidence of meningioma in pregnant women is rare, comparable with that in non-pregnant women of the same age group.<sup>[1]</sup> However, symptoms may flare during gestation, especially, during the second half of pregnancy. We report a case of 35 years old woman, admitted 2 hours after delivery for convulsive seizures.

**CASE REPORT**

A 35 years old woman, gravida 2, parity 2, admitted in our establishment for a convulsive seizure with urine emission, appeared 2 hours after normal delivery. She reported chronic headache and the occurrence of two similar seizures, at 26 and 32 weeks' gestation. On admission, the patient was afebrile, with normal vital signs. No deficits or symptoms related to raised intracranial pressure were detected in neurological examination. Brain computed tomography scan was obtained (**Figure 1**); the description of the lesion was in favor of intracranial meningiomas. Funduscopic examination was normal. Preoperatively, oral corticoid therapy and anticonvulsants (Depakine) were prescribed. After brain Magnetic resonance imaging, craniotomy was performed (3 months later) for excision of the tumoral mass. The pathologic report was meningothelial meningioma, World Health Organization (WHO) grade 1.

**DISCUSSION**

Meningioma is the most common primary intracranial tumor in the adult population; it's a slow growing extra-axial brain neoplasm that arises from the arachnoid cells. This tumor accounts for 10 to 20 % of all central nervous

system neoplasms.<sup>[2]</sup> The clinical evidence of the effect of pregnancy on intracranial meningioma remains controversial. Authors have concluded that reversible hemodynamic changes such as hypervascularity and intracellular and/or extracellular edema were most likely responsible for the rapid growth pattern. A progesterone-induced mechanism has also been reported to be responsible for enlargement of meningiomas in pregnancy.<sup>[3,4]</sup> Clinical presentation of convulsive seizures during early postpartum period could be misdiagnosed as eclampsia, cerebral thrombophlebitis or hypoglycemia. However, the presence of a history of chronic headache and similar seizures, should alert physicians to the possibility of an intracranial lesion and further radiologic investigations should be made to establish correct diagnosis. The management strategy for intracranial tumors during pregnancy should be made depending on patient's physical status, localization of the tumor, gestational age and other concomitant factors. Surgical excision is the treatment of choice for intracranial meningiomas, but surgical intervention should be avoided during pregnancy when is possible because of the increased risk to both mother and fetus. Moreover, postpartum surgery of meningioma is recommended by most authors in the literature.<sup>[2,5]</sup> Pending surgery, corticosteroids must be prescribed for severe edema, and seizures should be controlled, preferably with monotherapy (like our case). In addition, obstetricians should realize that the risk and complications of epilepsy are more serious than the side effects of anticonvulsants.<sup>[6]</sup> Urgent neurosurgical intervention is reserved for the management of malignant tumors, active hydrocephalus, and benign brain tumors

associated with signs of impending herniation or progressive neurological deficit.<sup>[7]</sup>

### CONCLUSION

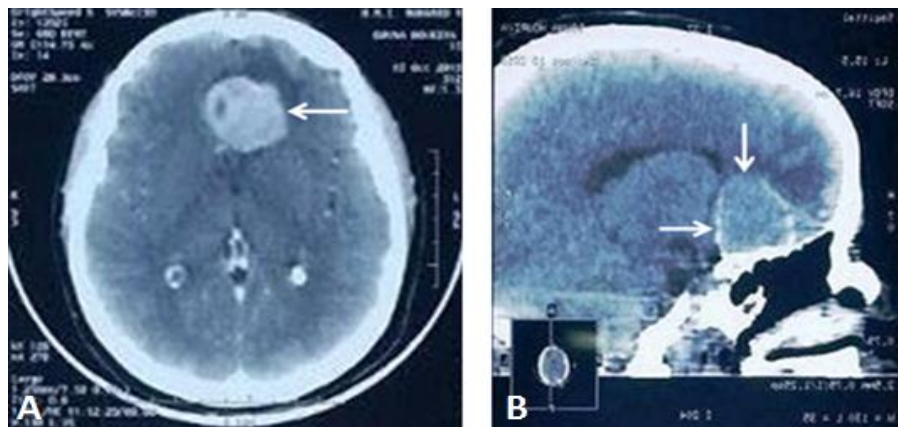
In the differential diagnosis of convulsive seizures, in the second or third trimesters of pregnancy and early postpartum period, intracranial meningioma should be considered. Advances in fetal and maternal monitoring, neuroanesthesia and microsurgical techniques allow safe neurosurgical management of these patients, and pregnancy usually continues successfully to term.

### ACKNOWLEDGEMENT

The authors have no personal financial or institutional interest in any of the drugs, materials, or devices described in this article.

### Conflict of interests

The authors declare that there is no conflict of interests regarding the publication of this paper.



**Figure 1: brain computed tomography scan (A: Cross section, B: Sagittal section) showing extra-axial frontal lesion (white arrows), measuring 35×31×37 mm, with peripheral calcifications enhanced after injection of a contrast agent and peritumoral oedema.**

### REFERENCES

1. Rand CW, Andler M. Tumors of the brain complicating pregnancy. *Arch Neurol Psychiatry*, 1950; 63(1): 1-41.
2. Dumitrescu BC, Tataranu LG, Gorgan MR. Pregnant woman with an intracranial meningioma: case report and review of the literature. *Romanian Neurosurgery*, 2014; 21(4): 489-496.
3. Cahill DW, Bashirelahi N, Solomon LW, Dalton T, Salcman M, Ducker TB. Estrogen and progesterone receptors in meningiomas. *Journal of Neurosurgery*, 1984; 60(5): 985-993.
4. Lesch KP, Fahlbusch R. Simultaneous estradiol and progesterone receptor analysis in meningiomas. *Surgical Neurology*, 1986; 26(3): 257-263.
5. Kanaan I, Jallu A, Kanaan H. Management Strategy for Meningioma in Pregnancy: A Clinical Study. *Skull Base*, 2003; 13(4): 197-203.
6. Gedzelman E, Meador KJ. Antiepileptic drugs in women with epilepsy during pregnancy. *Ther Adv Drug Saf*, 2012; 3(2): 71-87.
7. Wang LP, Paech MJ. Neuroanesthesia for the pregnant woman. *Anesthesia and Analgesia*, 2008; 107(1): 193-200.