

UNILATERAL NEVOID TELANGIECTASIA: TWO DIFFERENT CASE PRESENTATIONS

¹*Dr. Kapila Verma, Dr. Rakesh Biswas², Dr. Romita Bachaspatimayum³, Dr. Mhalevilie⁴,
Dr. Deepamala Subba⁵ and Dr. Y. Imlong Chaba⁶

^{1,2,4,5,6}Post Graduate Trainee, ³Registrar,

Department of Dermatology, Venereology and Leprology, Regional Institute of Medical Sciences, Imphal, Manipur, India.

*Corresponding Author: Dr. Kapila Verma

Post Graduate Trainee, Department of Dermatology, Venereology and Leprology, Regional Institute of Medical Sciences, Imphal, Manipur, India.

Article Received on 22/10/2016

Article Revised on 11/11/2016

Article Accepted on 01/12/2016

ABSTRACT

Unilateral nevoid telangiectasia (UNT) is a rare vascular dermatosis characterized by superficial telangiectasia in dermatomal distribution. It is distributed unilaterally and frequently found in C3-C4 or trigeminal nerve dermatomes. With less than 100 cases reported in literature, etio-pathogenesis still remains unclear, but a number of theories have been proposed to support the role of hormones (estrogens, progestogens and androgens) and their receptors as triggering agents. We report two different cases of UNT, one in a 20-year-old pregnant female patient who developed the disease during puberty and it aggravated during pregnancy. The second case is a 15-year-old boy who developed the disease during childhood and which aggravated during puberty.

KEYWORDS: Unilateral nevoid telangiectasia dermatomal distribution.

INTRODUCTION

Unilateral nevoid telangiectasia (UNT) is a rare congenital or acquired disorder, which was first described, by Blaschko in 1899.^[1] It is characterized by the appearance of unilateral telangiectasia with a segmental distribution. Apart from the skin, they can also affect the oral and gastric mucosae. In 1977, Wilkin et al classified it into two categories: congenital and acquired.^[2] Congenital cases are rare and occur during or after the perinatal period; more commonly in males. The acquired forms are much more frequent, and prefer females during fertile period.^[3] The acquired forms may be secondary to states of hyperestrogenism (pregnancy, puberty and menstrual cycle) or may be associated with

liver disease (alcoholic, viral and metastatic).^[2,3] We report two different presentations - one case of UNT in a pregnant lady and one case of UNT in a young boy.

Case 1

A 20-year-old female with 7 months' amenorrhoea (G₁P₀₊₀) presented with four years history of multiple, scattered, asymptomatic red spots, distributed linearly and unilaterally over the left side of face, chest, trunk and extremities. The lesions started over the left side of face and neck and gradually progressed during the course of pregnancy, ultimately involving the trunk, extremities and mucosa (ocular and oral) of the same side.

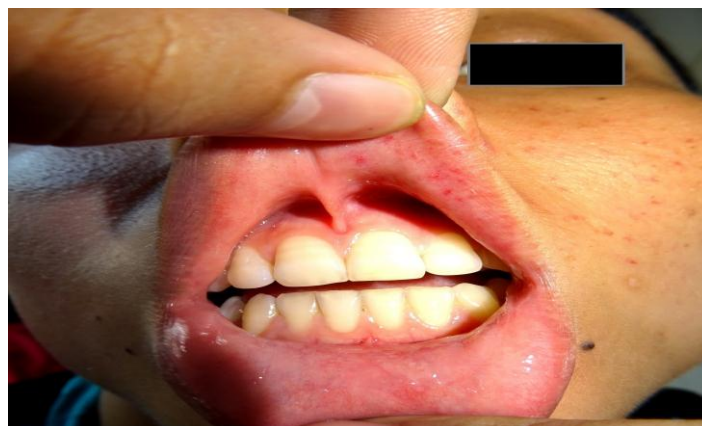

Figure 1: Erythematous blanchable macules over left side of face with oral mucosal involvement on same side.

On examination, erythematous blanchable macules with telangiectasia were present over left trigeminal (V₁₋₃), cervical (C₂₋₈) and thoracic (T₁₋₁₂) dermatomes (Figures 1 and 2).

Laboratory tests (complete hemogram, coagulation profile, random blood sugar, liver and kidney function tests, thyroid profile) were normal with no hepatomegaly on ultrasonography (USG) whole_abdomen study. HBsAg and anti-HCV antibody were non-reactive.

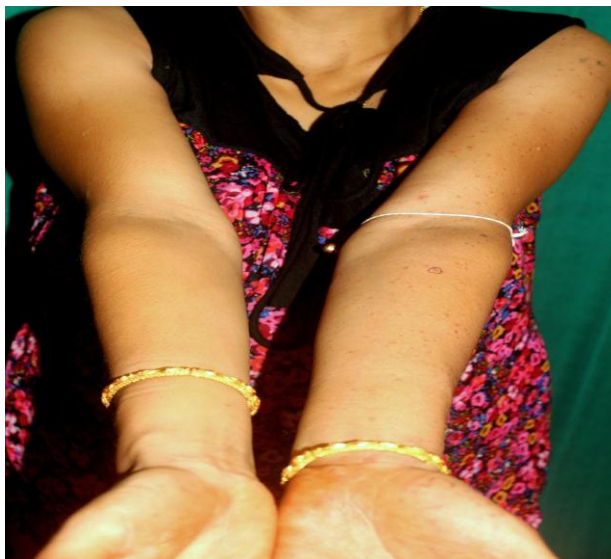

Figure 2: Erythematous blanchable macules over left upper limb.

Histopathological examination {Hematoxylin & Eosin (H&E)} showed non-specific finding with no dilatation

of vessels, neither endothelial cell proliferation nor neo-angiogenesis (Figure 3).

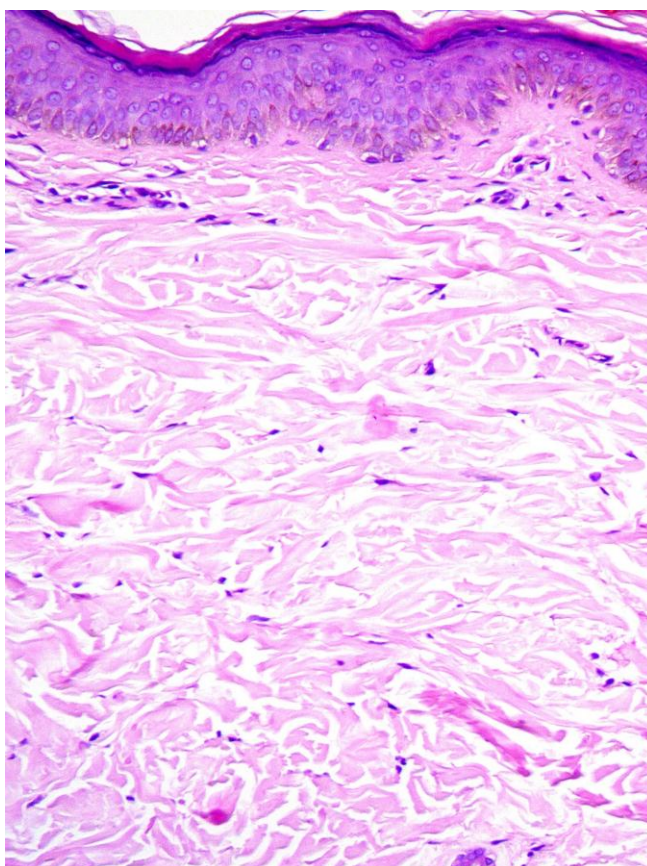


Figure 3: HPE (H&E X 100x) – orthokeratotic epidermis with mild pericapillary lymphocytic infiltration in the dermis.

Case 2

A 15-year-old boy presented with unilateral asymptomatic reddish spots which started on inner aspect of the right thigh at the age of seven years and gradually spread to the ventral and dorsal aspects of the right lower

extremity. General examination was unremarkable. On cutaneous examination, blanchable telangiectatic macules were present over the right lower extremities involving L₂₋₅ dermatomes (Figure 4).

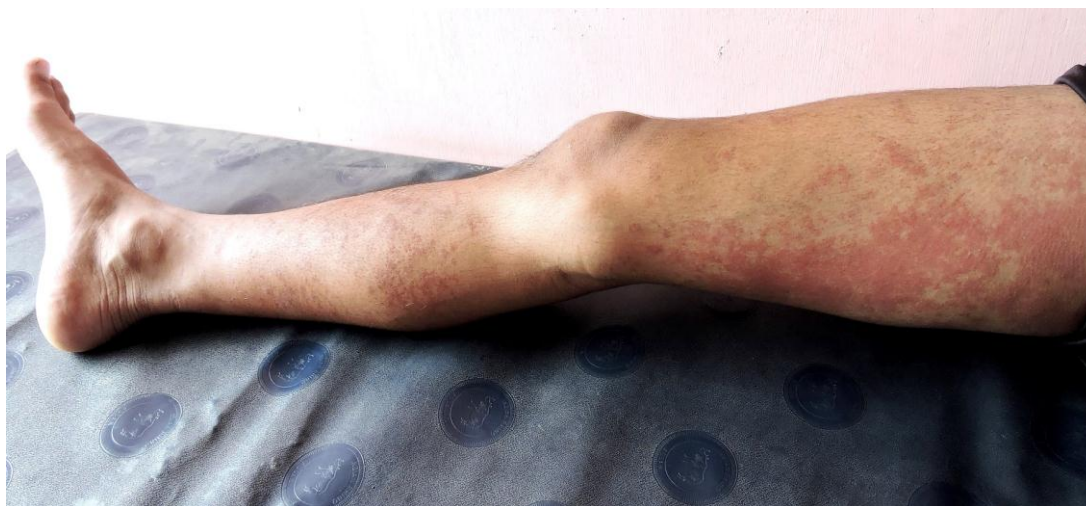

Figure 4: Erythematous blanchable macules and patches over right lower limb.

Skin biopsy showed orthokeratotic epidermis with increased collagen deposition in the dermis. No capillaries and lymphatic channels are seen. Laboratory tests revealed no abnormalities in hemogram, random blood sugar, liver and kidney function tests, and coagulation profile. HBsAg and anti-HCV antibody were non-reactive. USG whole abdomen was normal.

DISCUSSION

UNT was initially described by Blaschko in 1899, but only in 1970 had Selmanowitz coined the current name.^[3] It was recently in 2013 that Tanglersampan et al proposed a new classification system which divides UNT into congenital and acquired subtypes. The acquired cases are further subdivided into two classes: systemic association and no association.^[4] Although it is thought to be a rare condition with only fewer than 100 reported cases,^[1] increase in number of reports and association with newer conditions has drawn interest worldwide. UNT is thought to be associated with physiological and pathological hyperestrogenemic states such as pregnancy, puberty, hepatic disease and hormonal therapy.^[5] In our first case, the disease onset occurred during puberty and was exacerbated during pregnancy. In the second case, the disease started during childhood and was aggravated during adolescence. This might be explained by the hypothesis that, probably increased estrogen and progesterone during pregnancy and increased androgen hormones during puberty, stimulates the end target organs that are distributed congenitally in a dermatomal pattern in order to produce telangiectasia.^[6]

Presence of cutaneous along with ocular and oral telangiectasias, as reported in our first case, is thought to be an incomplete manifestation of Hereditary Hemorrhagic Telangiectasia. However, the absence of

family history refute this possibility^[7] so also in our first case.

Except for few, majority of cases have shown little or no estrogen/progesterone receptor positivity in biopsies from patients with UNT. Also, there have been no documented cases of increased serum or urine estrogen or progesterone levels outside of known pregnant patients.^[8]

Few authors have supported the role of vascular endothelial growth factor (VEGF) as an important angiogenic factor in pathogenesis of UNT by strong positive immunohistochemical staining of lesional skin.^[4] Also, the unilaterality of this condition and its association with ipsilateral melorheostosis has been explained by the concept of genetic mosaicism, specifically twin spotting.^[9]

The differential diagnosis of UNT includes hemangioma, angioma serpiginosum and rarely nevus flammeus. Histologically, hemangioma also shows a more distinct vascular proliferation compared to the sparse papillary dermal telangiectatic vessels of UNT. Angioma serpiginosum is characterized by a distinct distribution (usually lower extremities) of multiple punctate red or purple lesions, typically arranged in a serpiginous pattern and histologically is composed of thick-walled, dilated capillaries in superficial or mid-dermis.^[8] Therefore, diagnosis of this entity is eminently clinical, as the histopathology is not pathognomonic.^[5]

Although treatment is not required in UNT because the lesions are generally asymptomatic, patients may request therapy for cosmetic reasons.^[8] Pulsed-dye laser therapy of the involved areas has been used with good cosmetic

outcome.^[10] Treatment was denied by both patients owing to the benign nature of the condition. However, we were unable to assess whether spontaneous involution of the lesions has occurred, as both patients were lost to follow up.

CONCLUSION

UNT is regarded as a rare condition with fewer than 100 cases reported so far. But it seems to be underdiagnosed and sub-reported because of its asymptomatic character.^[1] Although we could not document the serum hormone levels and their receptors status because of patients' unaffordability, the relation of the disease onset and aggravation with puberty and pregnancy in our cases may support the role of hyperestrogenism in its pathogenesis.

As case-reports of associated condition presenting along with UNT is increasing, they warrant a thorough general, systemic and muco-cutaneous examination with laboratory investigations including histology, molecular and immunohistochemical staining which can help in better understanding of this condition.

Conflicts of Interest of each author: None.

Source of support: Nil.

REFERENCES

1. Guedes R, Leite L. Unilateral nevoid telangiectasia: A rare disease?. *Indian J Dermatol*, 2012; 57(2): 138-40.
2. Mayo-Pampín ME, Conde A, de la Torre C. Angiomatous eruption during pregnancy *Actas Dermosifiliogr*, 2008; 99(1): 73-4.
3. Arias M, González R, Retamar R, Santoro MCL, Demarchi M, Kien MC et al. Unilateral nevoid telangiectasia. Report of four cases. *Dermatol Argent*, 2009; 15(1): 44-8.
4. Smith JA, Kamangar F, Prakash N, Fung MA, Konia T, Fazel N. Unilateral nevoid telangiectasia syndrome (UNTS) associated with chronic hepatitis C virus and positive immunoreactivity for VEGF. *Dermatol Online J*, 2014; 20(6): 7-10.
5. Turan H, Gönen I, Albayrak H, Aliğaoğlu C. Acquired unilateral nevoid telangiectasia syndrome accompanied by chronic hepatitis B virus infection. *Acta Dermatovenerol Croat*, 2013; 21(2): 135-6.
6. Afsar FS, Ortac R, Diniz G. Unilateral nevoid telangiectasia with no estrogen and progesterone receptors in a pediatric patient. *Indian J Dermatol Venereol Leprol*, 2008; 74(2): 163-4.
7. Jordão JM, Haendchen LC, Berestinas TC, Faucz LR. Acquired unilateral nevoid telangiectasia in a healthy men. *An Bras Dermatol*, 2010; 85(6): 912-4.
8. Wenson SF, Jan F, Sepehr A. Unilateral nevoid telangiectasia syndrome: a case report and review of the literature. *Dermatol Online J*, 2011; 17(5): 2.
9. Kim J, Cho SB, Cho S, Bang D. Unilateral nevoid telangiectasia associated with ipsilateral melorheostosis. *Ann Dermatol*, 2012; 24(2): 206-8.
10. Sharma VK, Khandpur S. Unilateral nevoid telangiectasia-response to pulsed dye laser. *Int J Dermatol*, 2006; 45(8): 960-4.