

**GIANT AXILLARY LIPOMA REVEALING BREAST CANCER**

Mounir Moukit\*<sup>1</sup>, Moulay El Mehdi El Hassani<sup>1</sup>, Jaouad Kouach<sup>1,2</sup>, Fatimazahra Ait El Fadel<sup>1</sup>, Abdellah Babahabib<sup>1</sup>, Amina Kili<sup>2,4</sup>, Driss Moussaoui Rahali<sup>1,2</sup>, and Mohammed Dehayni<sup>2,3</sup>

<sup>1</sup>Department of Obstetrics and Gynecology, Military Training Hospital Mohammed V, Rabat, Morocco.

<sup>2</sup>Faculty of Medicine and Pharmacy, University Mohammed V, Rabat, Morocco.

<sup>3</sup>Department of Gynecology and Visceral Surgery, Military Training Hospital Mohammed V, Rabat, Morocco.

<sup>4</sup>Pediatric Center of Hematology and Oncology, Children's Hospital, Rabat, Morocco.

\*Corresponding Author: Mounir Moukit

Department of Obstetrics and Gynecology, Military Training Hospital Mohammed V, Rabat, Morocco.

Article Received on 27/10/2016

Article Revised on 17/11/2016

Article Accepted on 07/12/2016

**ABSTRACT**

Lipomas are the most frequent mesenchymal soft tissue tumours, but rarely present huge sizes or in the axillary region. Some cases of so-called "giant lipomas" have been reported in the literature and here, is presented the first case of giant axillary lipoma in a 57 years old woman which revealed breast cancer in the same side.

**KEYWORDS:** giant lipoma; axilla; breast cancer.

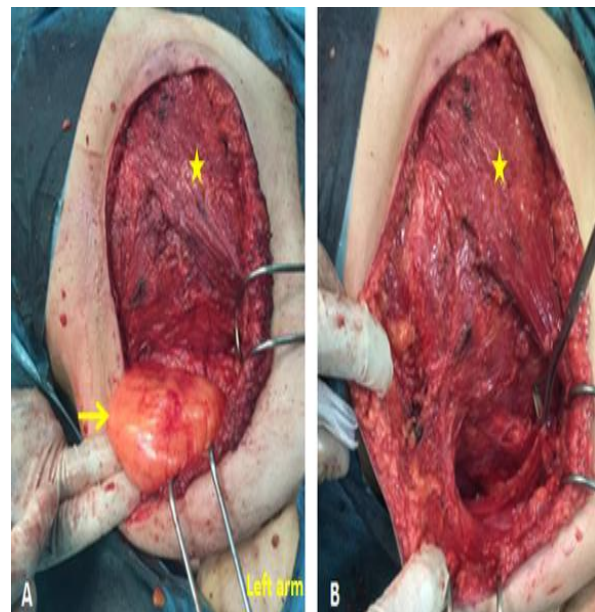
**INTRODUCTION**

Lipomas are the most common mesenchymal tumors. Their growth is usually insidious and limited, weighting only a few grams. However, these benign tumours may occasionally enlarge rapidly and become huge.<sup>[1]</sup> We report the first case of a large lipoma of the axilla revealing breast cancer in the same side in a menopausal woman.

**CASE REPORT**

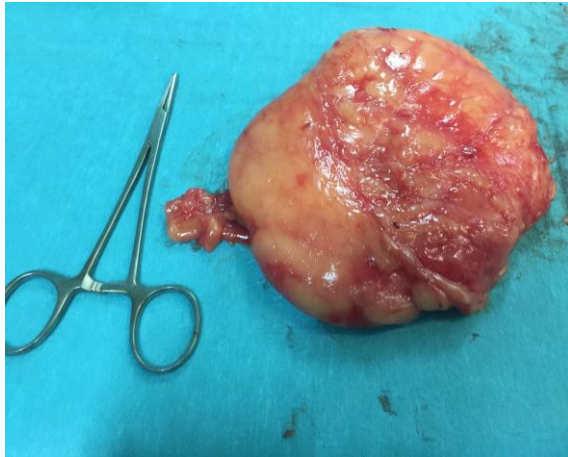A 57 years old woman, without family history of breast cancer, admitted in our department for asymptomatic left axillary mass that had grown slowly for 2 years. On physical examination a palpable soft mass filling the axillary region was observed. There were no skin changes, and neurological examination of the left upper extremity was normal. Left breast examination revealed a 3 cm masses in the upper outer quadrant, without nipple discharge or inflammatory skin signs. The right breast, nipple and axilla were normal. Systemic examination did not show any abnormality. Mammograms and ultrasonography revealed a 13 cm round homogeneous left axillary mass, with 3,5 cm left breast mass in the upper outer quadrant ACR 5. Excision biopsy of the breast mass was suggestive of invasive ductal carcinoma. Staging workup did not reveal any distant metastasis. Patient was consented for left mastectomy and axillary curage. Per operatively, the left axillary lesion was well delineated and could be completely excised after left axillary curage (**Fig. 1**), the specimen weighted 890g and measured 12×10 cm (**Fig. 2**). The final pathologic report was invasive ductal carcinoma (pT<sub>2</sub>N<sub>0</sub>M<sub>0</sub>, Scarff-Bloom-Richardson grade 2, HER2neu negative, ki67 40%, negative hormone

receptors) associated with axillary benign lipoma. She was treated with neoadjuvant chemotherapy. No recurrence was observed at 3 years follow-up.



**Figure 1: Intraoperative view after left mastectomy and axillary curage.**

**A:** axillary lipoma is exposed (yellow arrow) under the pectoralis major muscle (asterisk). **B:** view after complete surgical resection of the lipoma.



**Figure 2: Macroscopic view of the resected specimen (890 g).**

### DISCUSSION

Lipomas are the most frequent mesenchymal tumours, accounting for approximately 10 percent of all neoplasms.<sup>[2]</sup> Most of them are benign and arise mainly in any part of the body where adipose tissue is present.<sup>[3]</sup> The axillary region is a rare location for development of giant lipomas, and only a few cases have been reported.<sup>[1,4]</sup> A study by De Andrade and associates, in 31 cases of axillary masses, only one patient had an axillary lipoma.<sup>[5]</sup> The mechanism for the uncontrolled growth of giant lipomas is still unknown. Trauma is thought to be an important factor in the pathogenesis of lipoma.<sup>[6]</sup> It has been proposed that rupture of the fibrous septa after trauma accompanied by tears of the anchorage may result in proliferation of adipose tissue.<sup>[6]</sup> Since axillary region is one of the most moveables of the body it can be exposed to microtraumas with each movement of the upper limb.<sup>[1,6]</sup> Giant axillary lipomas could be of mammary origin, either by direct extension of the mammary gland itself or by secondary invasion by a malignant breast disease.<sup>[7]</sup> In our case, histopathological examination revealed that the axillary lesion comprised mature adipose tissue without breast ducts or acini. We suggest that local inflammation secondary to breast cancer may induce differentiation of pre-adipocytes and disrupt the normal regulation of adipose tissue. Mammography is the most useful imaging investigation for women over the age of 35 years presenting with a suspected breast mass. In addition, it can establish a preoperative diagnosis of the axillary mass. The typical mammographic manifestation of lipoma shows a completely fatty circumscribed lesion with or without encapsulation.<sup>[8]</sup> In ultrasonography, axillary lipomas are isoechoic to the surrounding fat and contain a disproportionate amount of axillary fat compared with the contralateral side. In this case, axillary lipoma was confused with axillary invasion by the malignant breast disease, axillary supernumerary mammary gland and fibrocystic disease. The main problem in the diagnosis of giant lipomas is to rule out malignancy, especially in our patient with breast cancer. Differential diagnosis between lipomas and liposarcomas is impossible by the clinical

appearance alone. Fine-needle aspiration biopsy or incisional biopsy can establish a preoperative diagnosis.<sup>[3]</sup> Moreover, the probability of malignancy still cannot be excluded; the histological evaluation of the entire lesion is essential for definitive diagnosis. Complete surgical excision still preferable, especially in the axillary area where large vessels and nerves could be engulfed by the neoplasm.<sup>[1,9]</sup> Liposuction through tiny incisions, even for a huge lesion, has been reported as effective treatment of giant lipomas.<sup>[9,10]</sup> However, hematomas, paralysis and recurrence (by incomplete removal of the tumor) are possible complications in such an indication.<sup>[9]</sup> In our case, dissection around the lesion was successfully performed, after axillary curage, without complications.

### CONCLUSION

facing an axillary tumour, complete senological investigation should be performed, including clinical breast examination, classical mammography/ultrasonography and eventually biopsy, to rule out a malignant breast disease.

### ACKNOWLEDGEMENT

The authors have no personal financial or institutional interest in any of the drugs, materials, or devices described in this article.

**Conflict of interests:** The authors declare that there is no conflict of interests regarding the publication of this paper.

### REFERENCES

1. Copcu E, Sivrioglu NS, Culhaci N. Axillary giant lipoma. *Plast Reconstr Surg*, 2004; 114(7): 1982-1983.
2. Meson H. Lipoma in clinical dermatology. *Clin Dermatol*, 1991; 4(1): 1-2.
3. Di Benedetto G, Aquinati A, Astolfi M, Bertani A. Giant compressing lipoma of the thigh. *Plast Reconstr Surg*, 2004; 114(7): 1983-1985.
4. Singal R, Jora MS, Mittal A et al. An unusual presentation of giant extrathoracic tumor in a child-managed successfully. *Turk J Pediatr*, 2012; 54(2): 191-193.
5. De Andrade JM, Marana HR, Sarmiento Fihlo JM, Murta EF, Velludo MA, Bighetti S. Differential diagnosis in axillary masses. *Tumori*, 1996; 82(6): 596-599.
6. Copcu E, Sivrioglu NS. Posttraumatic lipoma: analysis of 10 cases and explanation of possible mechanisms. *Dermatol Surg*, 2003; 29(3): 215-220.
7. Vandeweyer E, Scagnol I. Axillary Giant Lipoma: a case report. *Acta chir belg*, 2005; 105(6): 656-657.
8. Muttarak M, Chaiwun B. Imaging of giant breast masses with pathological correlation. *Singapore Med J*, 2004; 45(3): 132-139.
9. Nichetr LS, Gupta BR. Liposuction in giant lipoma. *Ann Plast Surg*, 1990; 24(4): 362-365.

10. Rubenstein R, Roenigk HH, Garden JM, Goldberg NS, Pinski JB. Liposuction for lipomas. *J Dermatol Surg Oncol*, 1985; 11(11): 1070-1074.