

PREVALENCE & DIFFERENT SHAPES OF HALLER'S CELLS ON PANORAMIC RADIOGRAPH- A STUDY**Dr. Md. Asdullah*¹, Dr. Kauser J. Khwaja², Dr. Anshul Aggarwal³, Dr. Masood H. Khan⁴, Dr. Nasir A. Salati⁵, Dr. Saif Khan⁶**^{1,4,5}Assistant Professor, Department of Oral Pathology/Oral Medicine & Radiology, Dr. Z.A College & Hospital, A.M.U Aligarh (UP).^{2,3}Associate Professor, Department of Oral Pathology/Oral Medicine & Radiology, Dr. Z.A College & Hospital, A.M.U Aligarh (UP).⁶Assistant Professor, Department of Periodontics, Dr. Z.A College & Hospital, A.M.U Aligarh (UP).***Corresponding Author: Dr. Md. Asdullah**

Assistant Professor, Department of Oral Pathology/Oral Medicine & Radiology, Dr. Z.A College & Hospital, A.M.U Aligarh (UP).

Article Received on 08/12/2016

Article Revised on 28/12/2016

Article Accepted on 18/01/2017

ABSTRACT

Objective-Haller's cells or infraorbital ethmoid cells refer to the ethmoidal pneumatization of the superior aspect of the maxillary sinus and floor of the orbit. The clinical importance of these entities initiated this study with an aim to determine the prevalence and characteristics of Haller's cells on panoramic radiographs. **Materials and Methods:** This study comprised of 400 panoramic radiographs of healthy adults of the age 18-60 years. Each radiograph was interpreted for the presence of haller's cells. The data collected were then tabulated and subjected to descriptive statistics and chi-square test. **Results:** Haller's cells were observed in 20.5% patients. The overall mean age of subjects with Haller's cells was 33.82 years (with SD 8.61). Maximum cells were oval in shape, followed by round, tear drop and nonspecific in shape. **Conclusion:** Presence of haller's cells helps in enumerating the differential diagnosis for orofacial pain and in avoiding surgical complications in endonasal procedures.

KEYWORDS: Endonasal procedures, Ethmoid air cells, Maxillary sinus, Orthopantomograph, Orofacial pain.**INTRODUCTION**

Haller's cells are defined as air cells situated beneath the ethmoid bulla along the roof of the maxillary sinus and the most inferior portion of the lamina papyracea, including air cells located within the ethmoid infundibulum.^[1] Haller's cells, first described by the Swiss anatomist Albert von Haller in 1765, are also known as maxillo-ethmoidal or orbito-ethmoidal cells.^[2,3] Haller's cells are thought to arise in individuals with pneumatization of the lateral crus.

Although Haller's cells are anatomical variations in the development of the nose and paranasal sinuses, they have been held responsible for patient's symptoms and are thus clinically significant.^[1,2] In addition to distressing orofacial pain and sinusitis, numerous pathologies and symptoms associated with this entity include nasal obstruction, impaired nasal breathing, headache, chronic cough and mucocoeles.^[2,3,5-8] Haller's cells can also restrict access to the maxillary sinus or the anterior ethmoidal cells during endonasal procedures.

Infraorbital ethmoid cells have been described as well-defined, round, oval or teardrop-shaped radiolucencies (single or multiple), unilocular or multilocular with a smooth border which may or may not appear corticated

and are located medial to the infraorbital foramen according to a solitary panoramic radiographic study.^[2] The clinical significance of these entities and the lack of noteworthy research initiated this study with an aim to determine the prevalence and scrutinize the characteristics of Haller's cells on panoramic radiographs.

MATERIALS AND METHOD

The study group comprised 400 healthy adults of both genders with an age range of 18-60 years who were selected by simple random sampling. Patients with a history of trauma and/or surgery involving the maxillofacial region, systemic diseases affecting growth and development, or clinical and/or radiographic evidence of developmental anomalies/pathologies affecting the maxillofacial region were excluded from the study. The institutional ethical clearance was obtained prior to the conduct of the study. Following clinical examination, one panoramic radiograph (Orthophos XG Sivona) for each of the patients was made. Films (Eastman Kodak, Rochester, NY) were processed in an automatic processor (Konica Minolta, Dry pro) that was preset to the manufacturer's specifications regarding the processing cycle. The radiographs obtained were serially interpreted for the

presence of Haller's cells under ideal viewing conditions. The recognition of Haller's cells was made if an anatomical variation fulfilled the criteria suggested by Ahmad *et al.*^[2] The observations pertaining to the Haller's cells were entered in the subjects' performa. The data collected were tabulated and subjected to statistical analysis.

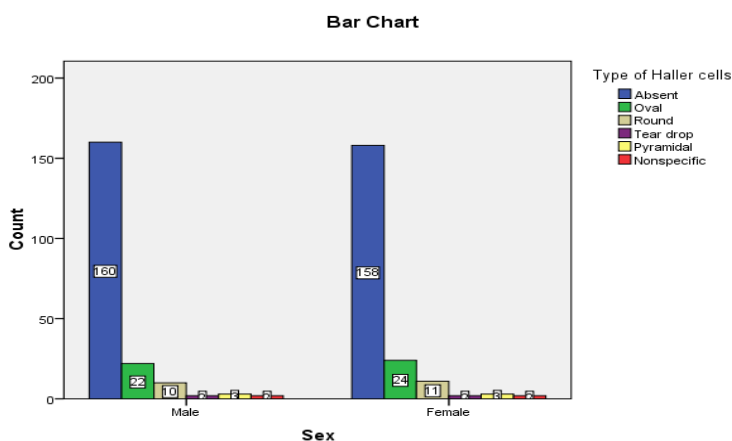
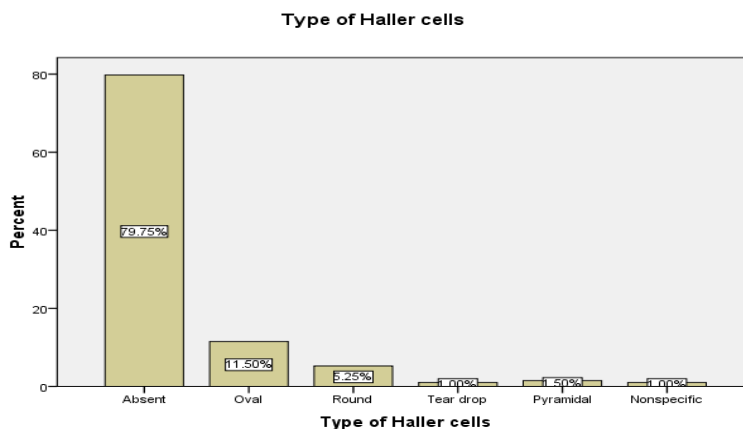
RESULTS

The total sample size of the study was 400, consisting of 200 males and 200 females. However one data of male sample was missing.

Of the 400 patients, Haller's cells were found in 81. The overall prevalence of Haller's cells was 20.5% (Table 1). The overall mean age of subjects with Haller's cells was 33.82 years (with SD 8.61). Of the 81 patients with Haller's cells, 46 (11.5%), were oval in shape 21(5.2%) were round in shape, 4 (1%) were tear drop in shape, 6(1.5%) were pyramidal and 4(1%) were nonspecific in shape. (Table 1). Among the 81 patients with Haller's cells, 39 (14.9%) were male and 42(18%) were female (Table 2).

Type of Haller cells					
		Frequency	Percent	Valid Percent	Cumulative Percent
Valid	Absent	319	79.8	79.8	79.8
	Oval	46	11.5	11.5	91.2
	Round	21	5.2	5.2	96.5
	Tear drop	4	1.0	1.0	97.5
	Pyramidal	6	1.5	1.5	99.0
	Nonspecific	4	1.0	1.0	100.0
	Total	400	100.0	100.0	

Table-1



Sex * Type of Haller cells Crosstabulation								
Count								
		Type of Haller cells						Total
		Absent	Oval	Round	Tear drop	Pyramidal	Nonspecific	
Sex	Male	160	22	10	2	3	2	199
	Female	158	24	11	2	3	2	200
Total		318	46	21	4	6	4	399

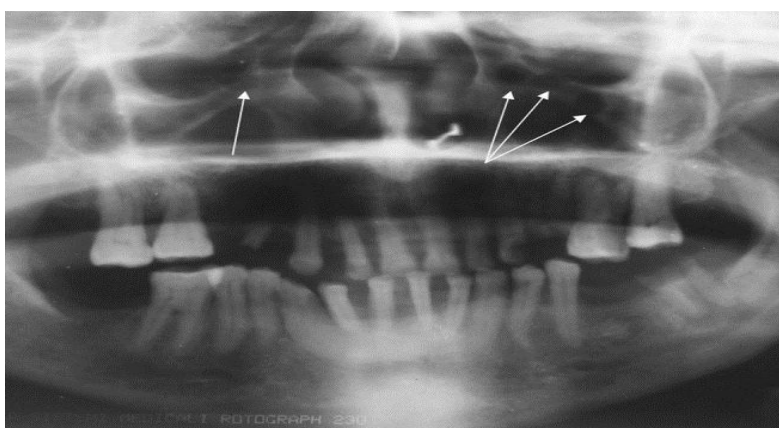
Table-2

Chi-Square Tests			
	Value	df	Asymp. Sig. (2-sided)
Pearson Chi-Square	.145 ^a	5	1.000
Likelihood Ratio	.145	5	1.000
Linear-by-Linear Association	.043	1	.836
N of Valid Cases	399		

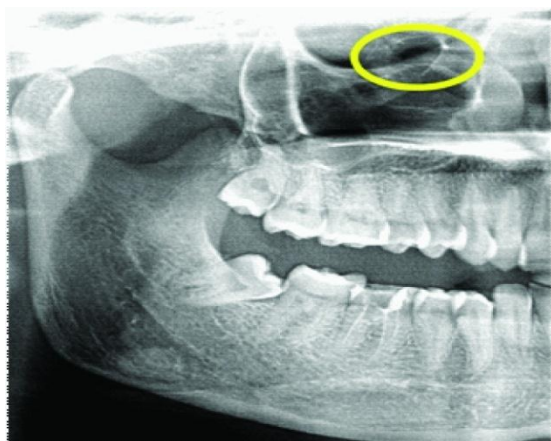
a. 6 cells (50.0%) have expected count less than 5. The minimum expected count is 1.99

Among the total (39) haller cell present in male patients 22 were oval, 10 were round, 2 were teardrop, 3 were pyramidal and 2 were nonspecific in shape. Whereas 24 were oval, 11 were round, 2 were teardrop, 3 pyramidal and 2 were nonspecific in shape among total of 42 female patient showing haller cell. (Table-2).

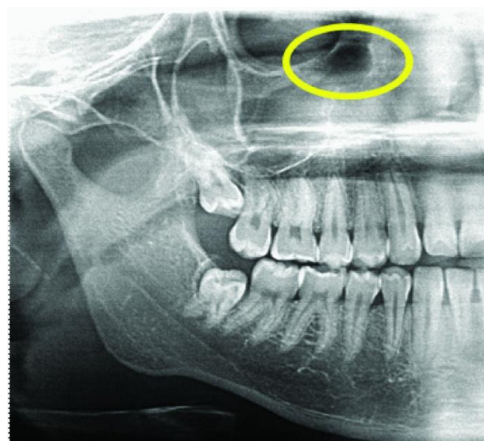
In chi-square test p value found to be 0.836 which is not significant. (p value less than 0.05 is considered to be significant).



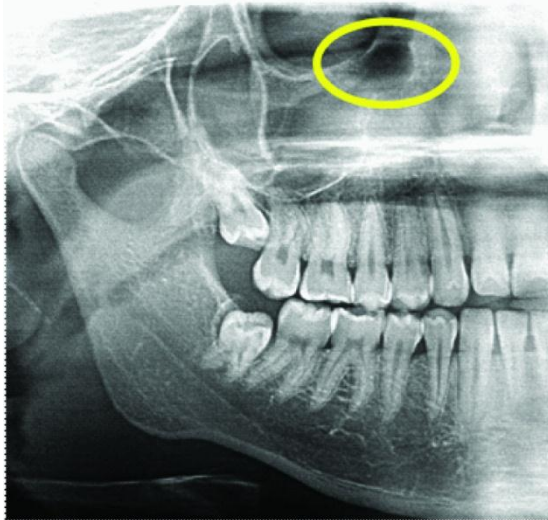
Cropped panoramic radiograph showing bilateral Haller's cells



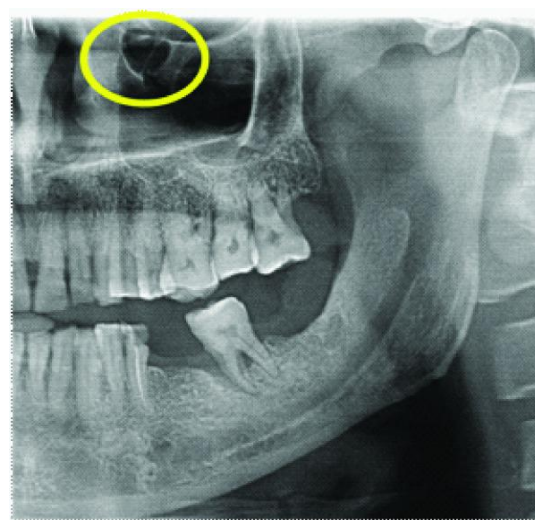
Oval shape haller's cell



round shape haller's cell



Tear drop shape haller's cell



Pyramidal shape haller's cell

DISCUSSION

A wide range of prevalence (4.7–45.1%) of infraorbital ethmoid cells using CT images has been reported in the literature.^[1,2,5,7,9-13] Although this study examined panoramic radiographs, the prevalence (20.5%) falls within the range of these previous studies. A much higher prevalence of 38.2% has been cited according to the sole panoramic radiographic study on Haller's cells conducted by Ahmad *et al* in 2006.^[2] This disparity could have resulted from variations in the populations studied, sample sizes and the subjective judgment pertaining to the presence or absence of Haller's cells.

Results indicated a male-to-female ratio of nearly 1:1 for the presence of Haller's cells. The distribution of Haller's cells with respect to gender was not statistically significant. This is consistent with the results of a CT imaging study on Haller's cells by Basic *et al*,^[1] who reported no difference in prevalence of Haller's cells between males and females.

In conclusion, the results of this study indicate that panoramic radiographs can depict and provide a clear delineation of Haller's cells in a considerable number of cases. The present study is distinctive in that there have been analyses performed to determine the variations of Haller's cells with respect to age, gender, type, number and shape which has only remotely been documented in the past. Such a description of the infraorbital ethmoid (Haller's) cells may prove useful in clear identification of these entities and aid in charting out the differential diagnosis for patients suffering from intractable orofacial pain, thereby avoiding other expensive and invasive diagnostic modalities. Detection of Haller's cells may also forewarn the surgeons prior to endonasal procedures, thus preventing any untoward intraoperative complications. Further studies employing advanced imaging modalities would aid in justifying our findings and provide a more precise description of these less explored entities.

REFERENCES

1. Basic N, Basic V, Jukic T, Basic M, Jelic M, Hat J. Computed tomographic imaging to determine the frequency of anatomical variations in pneumatization of the ethmoid bone. *Eur Arch Otorhinolaryngol*, 1999; 256: 69–71 [PubMed].
2. Ahmad M, Khurana N, Jaber J, Sampair C, Kuba RK. Prevalence of infraorbital ethmoid (Haller's cells) on panoramic radiographs. *Oral Surg Oral Med Oral Pathol Oral Radiol Oral Endod*, 2006 May; 101(5): 658–61. Epub 2006 Feb 28 [PubMed].
3. Yanagisawa E, Marotta JC, Yanagisawa K. Endoscopic view of a mucocele in an infraorbital ethmoid cell (Haller cell). *Ear Nose Throat J*, 2001; 80: 364–368 [PubMed].
4. Lang J. *Clinical anatomy of nose, nasal cavity and paranasal sinuses: a basis for diagnosis and surgery*. New York, NY: Thieme; 1989.
5. Kantarci M, Karasen RM, Alper F, Onbas O, Okur A, Karaman A. Remarkable anatomic variations in paranasal sinus region and their clinical importance. *Eur J Radiol*, 2004; 50: 296–302 [PubMed].
6. Braun H, Stammberger H. Pneumatization of turbinates. *Laryngoscope*, 2003; 113: 668–672 [PubMed].
7. Tatli MM, San I, Karaoglanoglu M. Paranasal sinus computed tomographic findings of children with chronic cough. *Int J Pediatr Otorhinolaryngol*, 2001; 60: 213–217 [PubMed].
8. Holinger LD, Sanders AD. Chronic cough in infants and children: an update. *Laryngoscope*, 1991; 101: 596–605 [PubMed].
9. Wanamaker HH. Role of Haller's cell in headache and sinus disease: a case report. *Otolaryngol Head Neck Surg*, 1996; 114: 324–327 [PubMed].
10. Bolger WE, Butzin CA, Parsons DS. Paranasal sinus bony anatomic variations and mucosal abnormalities: CT analysis for endoscopic sinus surgery. *Laryngoscope*, 1991; 101: 56–64 [PubMed].

11. Milczuk HA, Dalley RW, Wessbacher FW, Richardson MA. Nasal and paranasal sinus anomalies in children with chronic sinusitis. *Laryngoscope*, 1993; 103: 247–252 [PubMed].
12. Nouraei SA, Elisay AR, Dimarco A, Abdi R, Majidi H, Madani SA, et al. Variations in paranasal sinus anatomy: implications for the pathophysiology of chronic rhinosinusitis and safety of endoscopic sinus surgery. *J Otolaryngol Head Neck Surg*, 2009; 38: 32–37 [PubMed].
13. Mazza D, Bontempi E, Guerrisi A, Del Monte S, Cipolla G, Perrone A, et al. Paranasal sinuses anatomic variants: 64-slice CT evaluation. *Minerva Stomatol*, 2007; 56: 311–318 [PubMed].