

**ANHIDROTIC ECTODERMAL DYSPLASIA PRESENTING AS ATROPHIC RHINITIS -
A CASE REPORT****Dr. Pooja Thakur^{1*}, Dr. Dilip Awasya² and Dr. V. K. Poorey³**¹Department of E.N.T, G.M.C, Bhopal, India.²Department of E.N.T, G.M.C, Bhopal, India.³Department of E.N.T, G.M.C, Bhopal, India.**Corresponding Author: Dr. Pooja Thakur**

Department of E.N.T, G.M.C, Bhopal, India.

Article Received on 03/12/2016

Article Revised on 25/12/2016

Article Accepted on 15/01/2017

ABSTRACT

Anhidrotic ectodermal dysplasia, also known as Christ-Siemens-Tourine Syndrome is a X-linked recessive disorder characterised by the faulty development of the ectodermal structure, resulting in most notably anhydrosis/hypohydrosis, hypotrichosis and hypodontia. An interesting case of anhidrotic ectodermal dysplasia which came with Atrophic rhinitis, epistaxis, headache and nasal myiasis is presented.

KEYWORDS: Anhidrotic Ectodermal dysplasia, hypohidrotic ectodermal dysplasia, X-linked recessive, Atrophic rhinitis.

INTRODUCTION

Anhidrotic ectodermal dysplasia is a form of ectodermal dysplasia, which is a group of conditions characterized by abnormal development of ectodermal tissues including the skin, hair, teeth, and sweat glands^[1]. This condition is usually an X linked recessive disorder affecting predominantly males. The signs and symptoms are evident soon after birth. Skin abnormalities include areas that are dry, wrinkled, or darker in color than the surrounding skin. Affected individuals tend to have sparse scalp and body hair (hypotrichosis)^[1,2]. The hair is often lightcoloured, brittle, and slow growing. It is also characterized by missing teeth (hypodontia)^[2,3] or teeth that are small and pointed. Most people with anhidrotic ectodermal dysplasia have a reduced ability to sweat (hypohydrosis)^[2,3,4], because they have fewer sweat glands than normal or their sweat glands do not function properly. An inability to sweat (anhidrosis) can lead to a dangerously high body temperature (hyperthermia), particularly in hot weather^[5].

Otorhinolaryngological manifestations are related to hypoplasia of mucous glands of the upper aero-digestive tract, leading to chronic infections like Rhinitis, Pharyngitis, Otitis media, Atrophic rhinitis and epistaxis.^[3,4] We are here reporting a classical case of anhidrotic ectodermal dysplasia with a review of the literature.

CASE PRESENTATION

A 10 year old male child was brought to the ENT OPD of Gandhi Medical College Bhopal, M.P, on 20/10/2014

with the complaints of epistaxis and nasal myiasis. There was history of crust formation in nose since birth. Externally, nose was broadened and on Anterior Rhinoscopy, thick crust and maggots filled the nasal cavities & turbinates were atrophied. There was loss of eyebrows and eyelashes. The skin over these areas was dry and wrinkled. Lips were thick and everted. There was hypodontia with peg shaped incisors and pointed teeth. He had sparse, thin, lightly pigmented scalp hair. There was palmo-plantar hyperkeratosis. The oral mucosa, palate, nails were normal. There was a history of reduced sweating and heat intolerance.

All Heamatological examination were within normal limits. Schirmer's test showed decreased lacrimation. Skin biopsy showed absence of hair follicles, sebaceous and eccrine gland. The history, clinical presentation and histopathology confirmed the diagnosis.

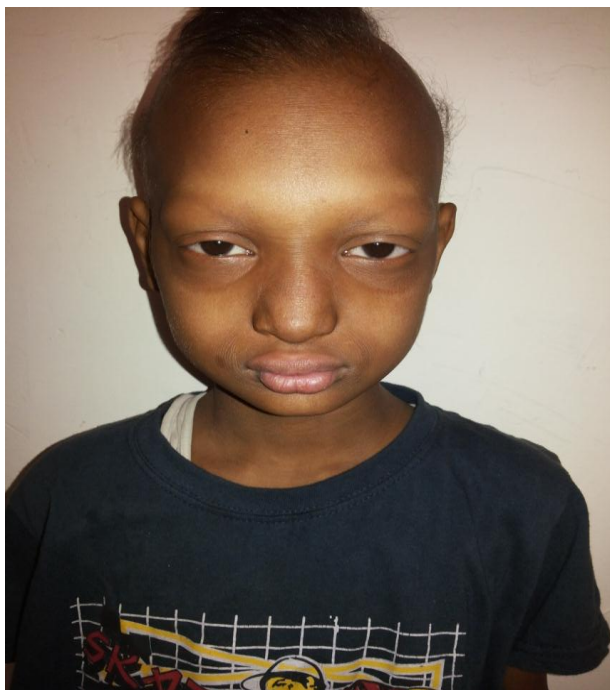


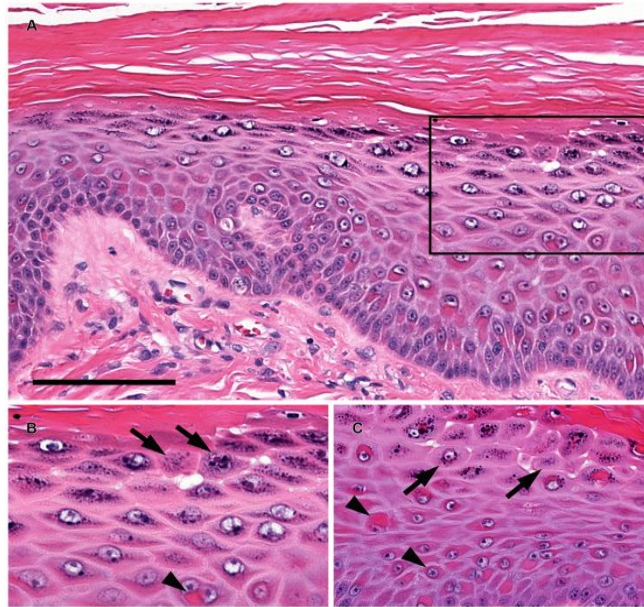
Figure Legend 1: A Case of Anhidrotic ectodermal dysplasia

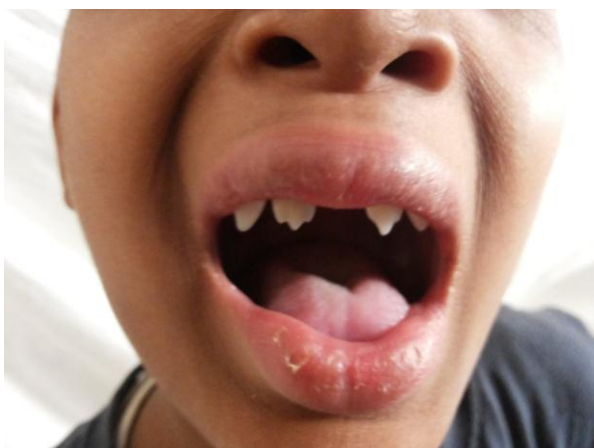
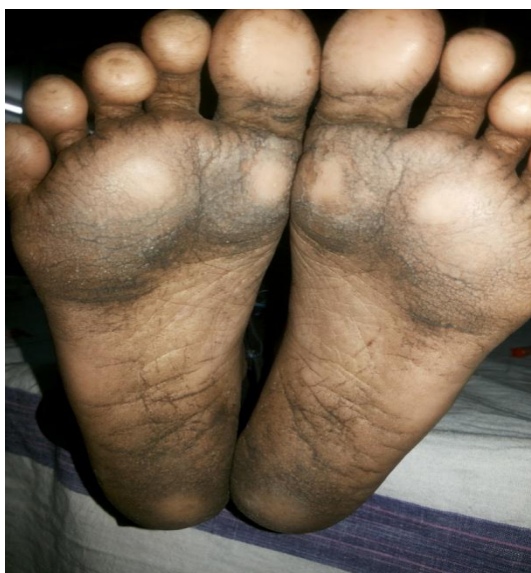
Figure Legend 2: (A) – Peculiar Clinical features



(B) - Histopathology- Skin biopsy - Absence of sweat glands and hair follicles



DISCUSSION

Ectodermal dysplasias are a group of inherited disorders that share common developmental defects involving at least two of the major structures classically hold to derive from the embryogenic ectoderms- hair,teeth, nails and sweat glands^[1,3,4]. Anhidrotic ectodermal dysplasia is characterized by partial or complete absence of sweat glands, hypotrichosis, and hypodontia.^[3,4] The X linked type, otherwise called as Christ Siemens Touraine Syndrome, was first described in 1848 by Thurnam. The incidence at birth is 1 in 100,000 males^[6]. Clinically, this condition is characterized by sparse or absent eccrine glands as well as by hypotrichosis and oligodontia with peg shaped teeth^[4] as seen in the present case also. The conical and pointed teeth are key features of the syndrome and may be the only obvious abnormality. Usually incisors and/or canines are characteristically affected. The scalp hair, eyebrows, and eyelashes are sparse, fine, and often times lightly pigmented. Our patient had loss of eyebrows and eyelashes, and sparse, thin, lightly pigmented scalp hair. In contrast to several other types of ectodermal dysplasia, nails were normal.

This is one of the rare condition presenting with atrophic rhinitis and nasal Myiasis in infancy and early childhood. Carrier mothers must be informed of the high risk recurrence for future male infants. Affected individuals should learn to control their exposure to heat and to minimize its consequences. Regular visits to an ENT specialist is necessary .

REFERENCES

1. James, William; Berger, Timothy; Elston, Dirk (2005). *Andrews' Diseases of the Skin: Clinical Dermatology*. (10th ed.). Saunders. ISBN 0721629210.
2. Freedberg, et al. (2003). *Fitzpatrick's Dermatology in General Medicine*. (6th ed.). McGrawHill. ISBN 0071380760.
3. Soloman LH, Kener EJ. The ectodermal dysplasia. *Arch Dermatol* 1980; 116: 2959.
4. Reed WB, Lopez DA, Lauding B. Clinical spectrum of anhidrotic ectodermal dysplasia. *Arch Dermatol* 1970; 102: 13443.
5. Brengelmann GL, Freund PR, Rowell LB, Olerud JE, Kraning KK. Absence of active cutaneous vasodilation associated with congenital absence of sweat glands in humans. *Am J Physiol* 1981; 240: H5715.
6. Stevenson AC, Kerr CB. On the distribution of the frequencies of mutation to genes determining harmful traits in man. *Mutat Res* 1967; 4: 33952.