



## RADIOGRAPHIC EVALUATION OF THE POSITION OF MENTAL FORAMEN IN ALIGARH (WESTERN U P) POPULATION

Dr. Md. Asdullah<sup>1\*</sup>, Dr. Masood Hassan Khan<sup>2</sup>, Dr. Nasir Ahmad Salati<sup>3</sup>, Dr. Kauser j Khwaja<sup>4</sup>, Dr. Ansul Aggarwal<sup>5</sup> and Dr. Sajjad Abdur Rahman<sup>6</sup>

<sup>1,2,3</sup>Assistant Professor, Deptt. Oral Pathology/Oral Medicine & Radiology, Dr. Z. A Dental College & Hospital, A. M. U Aligarh (U.P).

<sup>4,5</sup>Associate Professor, Deptt. Oral Pathology/Oral Medicine & Radiology, Dr. Z. A Dental College & Hospital, A.M.U Aligarh (U.P).

<sup>6</sup>Assistant Professor, Deptt. of Oral & Maxillofacial Surgery, Dr. Z.A Dental College & Hospital, A.M.U Aligarh (U.P).

\*Corresponding Author: Dr. Md. Asdullah

Assistant Professor, Deptt. Oral Pathology/Oral Medicine & Radiology, Dr. Z.A Dental College & Hospital, A.M.U Aligarh (U.P).

Article Received on 07/02/2017

Article Revised on 28/03/2017

Article Accepted on 19/04/2017

### ABSTRACT

**Background:** Information on the position of the mental foramen is important in dental profession. Variations in its position can be a cause of complications during local anesthesia or surgical procedures. The usual position of the mental foramen in an Indian population has not been previously reported. **Aims:** The purpose of this study was to determine the most common location of the mental foramen in an Indian population. Gender differences and the symmetry of location within individuals were also analyzed **Materials and Methods:** 30 panoramic radiographs were evaluated with regard to the location and symmetry of the mental foramina in male and female subjects. **Results:** It was found that the mental foramen was located between the first and second premolars in 47% of patients and in line with the second premolar in 46.2%. In 48.2% of males, the mental foramen was in line with the second premolar. In 50.9% of females it was between the first and second premolars. It was symmetrical in 86% bilaterally. **Conclusions:** Based on this study it appears that the most common position of mental foramen is either between the two premolars or in line with the second premolar. This is in concordance with previous studies.

**KEYWORDS:** Mandible, mental foramen, mental nerve, panoramic radiography.

### INTRODUCTION

The Mental Foramen (MF) is an important anatomical structure located in the body of mandible. The mental foramen on each side is located on the buccal cortex of the mandibular bone and lies near the apices of the premolars. It has been shown to be located at precisely the same level on most humans (13-15 mm superior to the inferior border of the mandible). The opening of the mental foramen is directed outward, upward, and posterior, viewed from inside out. It transmits the mental vessels and nerve.<sup>[1]</sup> The mental nerve is a terminal branch of the inferior alveolar nerve; it supplies sensory innervations to the lower lip, the buccal vestibule, and the gingival, mesial to the first mandibular molar. Local anesthesia of the terminal incisive branches of the inferior alveolar nerve and injected within it.

Accurate identification of the mental foramen is important for both diagnostic and clinical procedures. Repeated failures which are witnessed during mental nerve blocks indicate its variability of location in a given population<sup>[2,3]</sup> Its radiographic misdiagnosis as a radiolucent lesion in the apical area of the mandibular premolars can lead to iatrogenic injuries. Treatment

concepts for dental implant patients identify mental foramen and its anterior loop as a critical surgical landmark and essential reference point during treatment planning. It has also been acknowledged through various studies, that surgical trauma caused to the mental nerve bundle as a result of inappropriate prior assessment, would result in altered sensation from 8.5% to 24% during periods of upto 3-16 months post-operatively following implant surgeries.<sup>[4,5]</sup>

As the bone density increases, it becomes more difficult to identify mental foramen on radiographs. Such cases, in which the mental foramen cannot be identified during panoramic radiographs under ordinary exposure and viewing conditions, were classified as 'un-identified type' by Yosue and Brooks.<sup>[6]</sup> The location of mental foramen has been studied in different populations without the mention of any Indian population.<sup>[3,8]</sup>

The purpose of this study was to report the usual position of the mental foramen in an northern Indian population.

## MATERIALS AND METHOD

Evaluation of 30 panoramic radiographs of patients was done who reported to our department, Oral Pathology/Oral Medicine & Radiology, Dr.Z.A Dental College & Hospital, A.M.U Aligarh (U.P) during last 6 months. Following clinical examination, one panoramic radiograph (Orthophos XG Sivona) for each of the patients was made. Films (Eastman Kodak, Rochester, NY) were processed in an automatic processor (Konica Minolta, Dry pro) that was preset to the manufacturer's specifications regarding the processing cycle.

### Exclusion criteria were

1. Presence of a radiolucent lesion in the lower jaw anywhere in the area extending from the right first molar to the left first molar.
2. Presence of a missing tooth in the lower jaw (between 36 and 46)
3. No visualization of the mental foramen bilaterally
4. Incomplete eruption of permanent teeth
5. Patient under 18 years
6. Presence of periodontal lesions
7. Radiolucent Patient with previous orthodontic treatment
8. Presence of crowding and spacing in the lower arch

The position of the image of the mental foramen was recorded according to Jasser and Nwoku<sup>[12]</sup> as follows

Position 1: Situated anterior to the first premolar

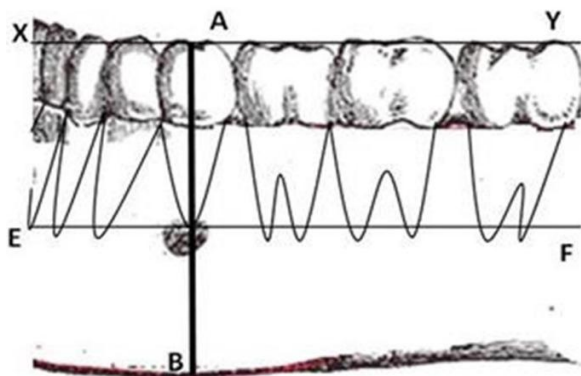
Position 2: In line with the first premolar

Position 3: Between the first and second premolars

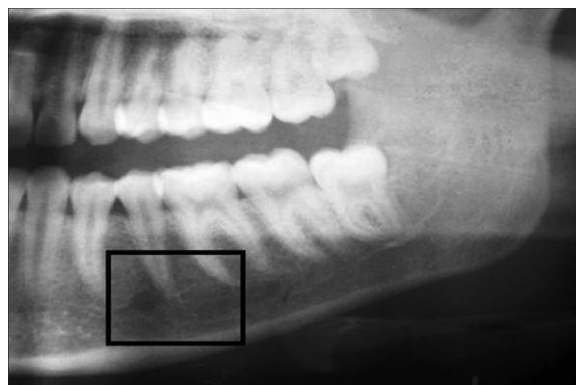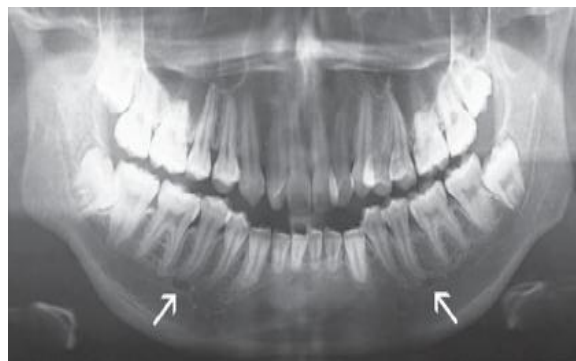Position 4: In line with the second premolar

Position 5: Between the second premolar and first molar

Position 6: In line with the first molar



Determining the average position of mental foramen on panoramic radiograph. A horizontal line XY was drawn at the occlusal level. Another line EF was drawn parallel to the line XY at the apex of second premolar. Perpendicular line AB was drawn passing through the apex of the mandibular second premolar through the long axis of the clinical crown (perpendicular to lines XY and EF) to the inferior border of the mandible. The average position of the MF (in relation to the line AB) relative to the apex of 2nd premolar was recorded as mesial, distal or intersecting this line.



Different position of mental foramen seen on panoramic radiograph.

After evaluation of each panoramic radiograph, the location of the mental foramen on each side was recorded in the form. The location of the mental foramen was reported on the basis of gender and symmetry or asymmetry. The findings were subjected to statistical analysis.

## RESULTS

Of the 30 panoramic radiographs analyzed, 15 were that of males and 15 that of females. The most common position for the mental foramen in this sample was position 3 (46.2%). There was no case found in position 1 (anterior to the first premolar). On the right side, the commonest position of the mental foramen was position 3 (23%) and on the left side it was position 4 (22.6%). Position 4 was the most common one among males (48.2%) and position 3 was the most common one among females (51%) In 25 cases (86%) the mental foramina were symmetrically located. For the symmetrically placed mental foramina, the most common location was position 3 (42.5%), followed by position 4 (38.6%). No case was found in position 1 and 6. No statistically significant differences were seen between males and females in symmetry and asymmetry location of mental foramen in both sides.  $P < 0.05$  was taken to indicate statistical significance.

## DISCUSSION

There is considerable debate regarding the normal position of the mental foramen in different populations. In the series of 30 panoramic radiographs used here, the location of the mental foramen varied widely, being found at any position between the root of the first premolar and the roots of the first molar;

this is in accordance with previous studies. According to this study, in 46.2% of the cases the mental foramen was located between the first and second premolars and in 47% it was in line with the second premolar; thus these two positions accounted for 93.2% of the cases.

Studies done by Moiseiwtsch<sup>[7]</sup> in a North American white population and by Fichel *et al.*<sup>[9]</sup> and Olasoji *et al.*<sup>[11]</sup> in Northern Nigerian adults showed that the most common location of the mental foramen was between the two premolars. These findings are consistent with the results found here. But studies done in other populations such as Malays, Iranians, Kenyan Africans and Saudis as well as the studies done by Phillips *et al.*<sup>[12]</sup>, have indicated that the mental foramen is most commonly positioned in line with the second premolar tooth.<sup>[13]</sup>

In the review of literature it was found that according to most authors the mental foramen is usually located between the lower premolars. However, there were some studies that reported that it most commonly lies near the apex of the second premolar. Other studies have found that both locations are common. In the present study, panoramic radiographs were used because the mental foramen is seen more consistently on the wide field of mandible view in panoramic radiographs than on periapical radiographs.

Patients over the age of 18 years were selected because of complete skeletal growth requirement. To eliminate the possibility of tooth migration, cases with periodontal lesions and previous orthodontic treatment were omitted from the study.

In conclusion, the most common locations of the mental foramen are between the two premolars and in line with the second premolar (below and or mesial to the second premolar). These findings are in accordance with the results of previous studies in other populations. The mental foramina are usually bilaterally symmetrical on both sides.<sup>[14]</sup>

**CONFLICT OF INTEREST:** None.

**SOURCE OF SUPPORT:** Nil.

#### REFERENCES

1. Woelfel JB, Scheid RC. Structures that form the foundation for tooth function. *Dental Anatomy: Its relevance to dentistry*. 6 \* ed. Newyork: Lippincott, Williams and Wilkins; 2002; 19.
2. Pokhrel R, Bhatmagar R. Position and number of mental foramen in dry human mandibles: Comparison with respect to sides and sexes. *Open Access Anatomy*. 2013 Dec 1; 1(4): 31.
3. Siddiqui AU, Daimi SR, Mishra PP, Doshi SS, Date JY, Khurana G. Morphological and Morphometric analysis of mental foramen utilizing various assessment parameters in dry mandibles. *Int J Stud Res*. 2011; 1(1): 19–22.
4. Massey ND, Galil KA, Wilson TD. Determining position of the inferior alveolar nerve via anatomical dissection and micro-computed tomography in preparation for dental implants. *J Can Dent Assoc*. 2013; 79: d39. [PubMed].
5. Greenstein G, Tarnow D. The mental foramen and nerve: clinical and anatomical factors related to dental implant placement: a literature review. *J Periodontol*. 2006 Dec; 77(12): 1933–43. [PubMed].
6. Yosue T, Brooks SL. The appearance of mental foramina on panoramic radiographs. I.Evaluation of patients. *Oral Surg Oral Med Oral Pathol* 1989; 68: 360-4.
7. Phillips JL, Weller RN, Kulild JC. The mental foramen: Part 1. Size, orientation and positional relationship to the mandibular second premolar. *J Endod* 1990; 16: 221-3.
8. Ngeow WC, Yuzawati Y. The location of the mental foramen in a selected Malay population. *J Oral Sci* 2003; 45: 171-5.
9. Yosue T, Brooks SL. The appearance of mental foramina on panoramic and periapical radiographs. II. Experimental evaluation. *Oral Surg Oral Med Oral Pathol* 1989; 68: 488-92.
10. Moiseiwtsch JR. Position of the mental foramen in a North American, white population. *Oral Surg Oral Med Oral Pathol Oral Radiol Endod* 1998; 85: 457-60.
11. Shankland WE 2<sup>nd</sup>. The position of the mental foramen in Asian Indians. *J Oral Implantol*. 1994; 20: 118-23.
12. Fishel D, Buchner A, Hershkowitz A, Kaffe I. Roentgenologic study of the mental foramen. *Oral Surg Oral Med Oral Pathol* 1976; 41: 682-6.
13. Mwaniki DL, Hassanali J. The position of mental foramina in Kenyan African mandibles. *East Afr Med J*. 1992; 69: 210-3.
14. Olasoji HO, Tahir A, Ekanem AU, Abubakar AA. Radiographic and anatomic locations of mental foramen in northern Nigerian adults. *Niger Postgrad Med J* 2004; 11: 230-3.
15. Phillips JL, Weller RN, Kulild JC. The mental foramen: Part 2. Radiographic position in relation to the mandibular second premolar. *J Endod*. 1992; 18: 271-4.
16. AL Jasser NM, Nwoku AL. Radiographic study of the mental foramen in Saudi females. *Saudi Med J*. 1996; 17: 471-4.
17. Atkinson ME, White FH. The skeletal system. *Principles of Anatomy and Oral Anatomy for Dental Students*. 1<sup>st</sup> ed. Edinburgh: Churchill Livingstone; 1992; 120.s.