



UNEXPLAINED DIFFUSE ARTERIOSCLEROSIS IN A 26-YEAR-OLD PATIENT

Jihed Anoun, Fatma Ben Fredj Ismail*, Anis Mzabi, Syrine Daadaa, Imene Ben Hassine, Monia Karmani, Hassen Hosni Mhiri, Amel Rezgui and Chedia Laouani Kechrid

Department of Internal Medicine, Sahloul Hospital, Faculty of Medicine, Sousse, Tunisia.

***Corresponding Author: Dr. Fatma Ben Fredj Ismail**

Department of Internal Medicine, Sahloul Hospital, Faculty of Medicine, Sousse, Tunisia.

Article Received on 19/03/2017

Article Revised on 09/04/2017

Article Accepted on 29/04/2017

ABSTRACT

Arteriosclerosis is an alteration of the blood vessels whose walls calcify, lose their elasticity and thicken. The result is a decrease in circulating blood flow and ischemic manifestations. Calcification of arteries is a physiological phenomenon in the elderly but young subjects may also be affected. Indeed, some risk factors can cause arteriosclerosis. We report the case of a 26-year-old female patient with diffuse arteriosclerosis discovered accidentally, and whose exhaustive etiological investigation remained negative.

KEYWORDS: Arteriosclerosis, young, diffuse, unexplained.

INTRODUCTION

Arteriosclerosis is an alteration of the blood vessels whose walls calcify, lose their elasticity and thicken. The result is a decrease in circulating blood flow and ischemic manifestations. Calcification of arteries is a physiological phenomenon in the elderly but young subjects may also be affected. Indeed, some risk factors can cause arteriosclerosis. These include classic cardiovascular risk factors, as well as systemic inflammatory diseases, connective tissue diseases, chronic hypocalcaemia. We report the case of a 26-year-old female patient with diffuse arteriosclerosis discovered accidentally, and whose exhaustive etiological investigation remained negative.

CASE REPORT

BAO is 26 years old, single, student, non-smoking and active. She had neither significant family medical nor surgical history. She was followed since age 13 for rheumatoid arthritis without cardiac involvement, which was manifested by arthritis treated with non steroidal anti-inflammatory drugs once or twice a year and once or both short corticosteroid treatment.

Two months prior to hospitalization, the patient had a right knee arthritis resistant to anti-inflammatory drugs. Radiography of the right knee revealed a calcification of the right popliteal artery [Fig 1, 2 and 3]. Arterial Doppler ultrasound of the right lower limb showed an irregular intimal calcification with diffuse medioclastic aspect of the femoro-popliteal and tibial arterial axis with significant hemodynamic repercussion and multiple loco regional substitution collaterals. There was, moreover, an aspect of calcifying tendonitis of the internal surface of the knee at the expense of the internal lateral ligament.

She consulted in our department and the patient's interrogation revealed the presence of a phenomenon of Raynaud in its anoxic phase for several years and eliminated the use of drugs. Physical examination showed a weight of 45 kg with a body mass index of 18.9 kg / m² and a waist circumference of 72 cm. The femoral and popliteal pulses were diminished on both sides and the foot pulse was abolished on both sides. A coldness of both feet without cyanosis or necrosis was also noted. The rest of the exam was without anomalies.

Phosphate, calcium in the blood and urine, creatin, fasting blood, glucose, HbA1c, lipids, alkaline phosphatases, vitamin D, uricemia, homocysteinemia and a blood count were normal. Inflammatory biology (PEP and CRP) and immunoassay (ANAc, Rheumatoid Factor, and Anti-CCP Ac) were normal. A capillaroscopy revealed a capillary rarefaction without signs of chronic microangiopathy.

We carried out a radiological assessment which included the following examinations.

- Cervical ultrasound: Two parietal calcifications of the right thyroid lobe without lesion of the parathyroid.
- Upper limbs arterial doppler ultrasonography: Absence of parietal calcifications.
- Angio-scan of the lower limbs: Extensive calcifications of the superficial femoral arteries and popliteal occludes along their paths, with deep femoral collateral network draining a sural network of preserved quality [Fig 4, 5 and 6].
- Angio-CT of the descending and ascending aorta: Multiple mediastinal and cervical calcifications confluent in places. Partial stenosing calcification of

the left external carotid artery reducing light to 40%. Non-obstructive parietal calcification of the right renal artery and the left internal iliac, reducing light by 50% and 30%, respectively [Fig 7 and 8].

- Brain CT scan: Bilateral punctiform micro calcifications of the lenticular nuclei [Fig 9 and 10].
- Cardiac ultrasound: without abnormalities.

A cutaneous biopsy showed discrete non-specific chronic inflammatory changes without histological signs in favor of a collagen or elastic connective tissue disorder.

The patient was treated by statin, antiaggregant platelet and an anti-thrombotic. After 2-years of follow-up, its evolution is stationary; it has any new complaints or ischemic signs.

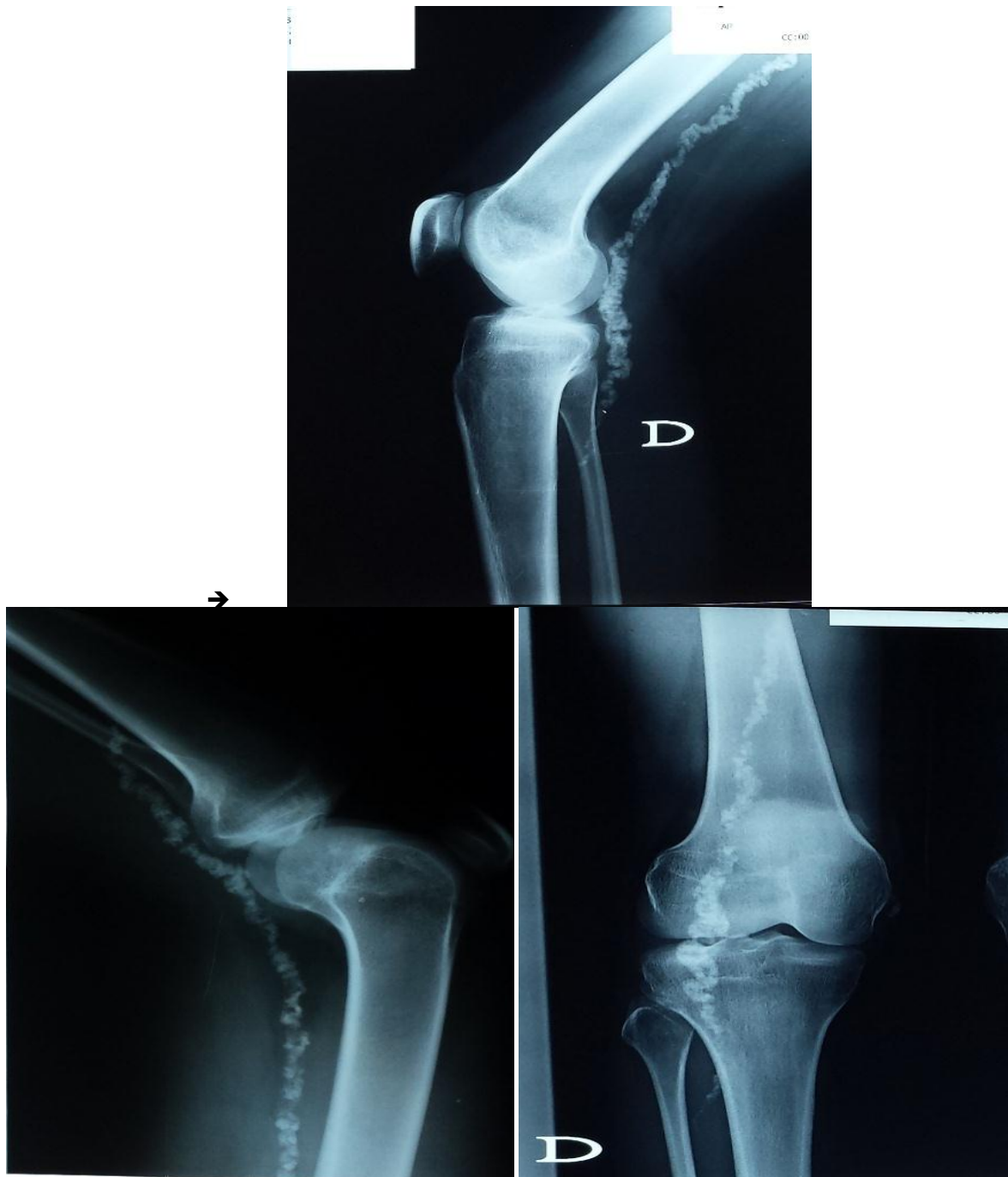

Fig 1. 2 and 3: Radiography of the right knee: calcification of the right popliteal artery.

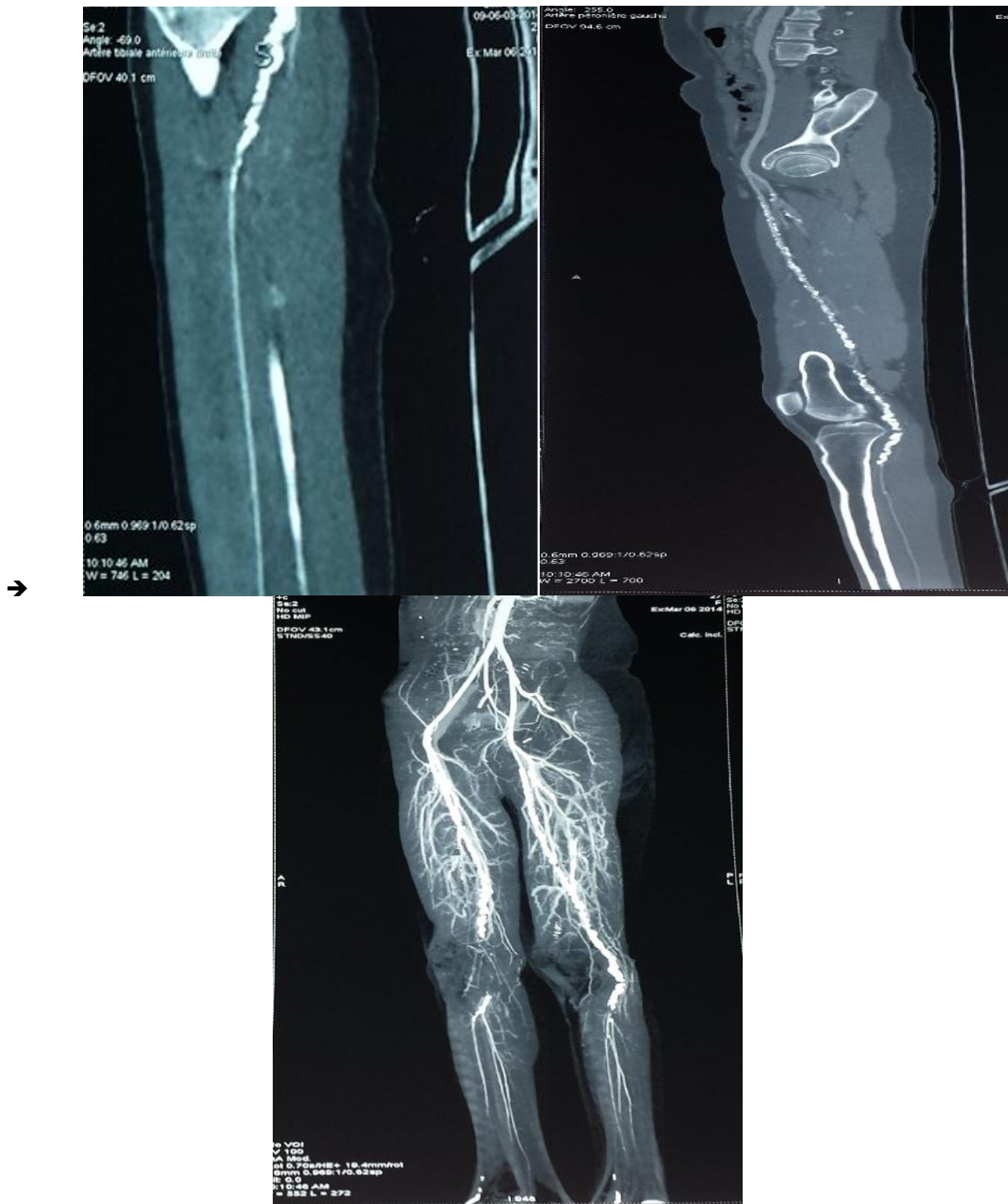

Fig 4.5 and 6: Lower limb Angio-CT.

Extensive calcifications of the superficial femoral arteries and occluded poplites along their paths, with a network of deep femoral collateral draining a sural network of preserved quality.

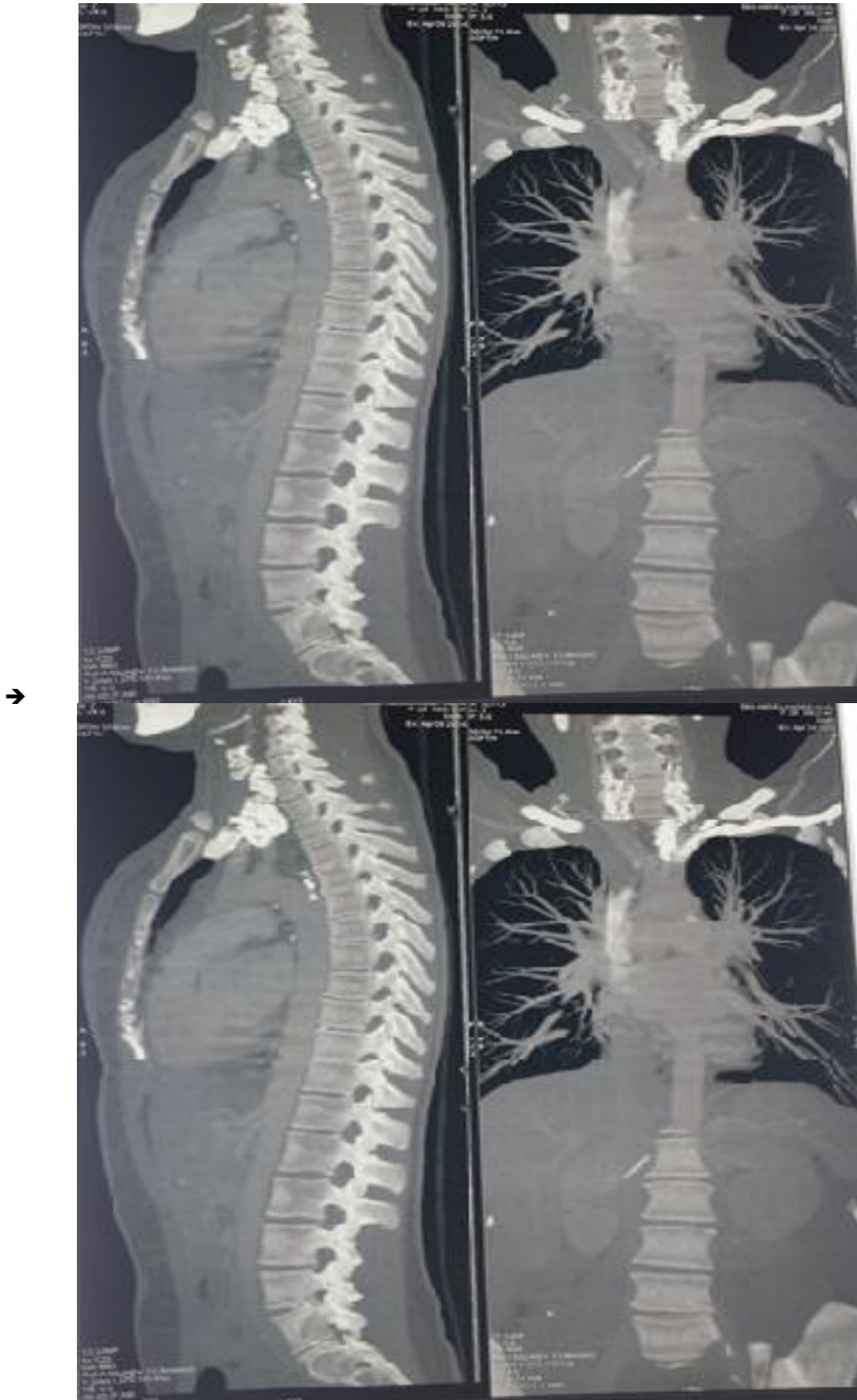
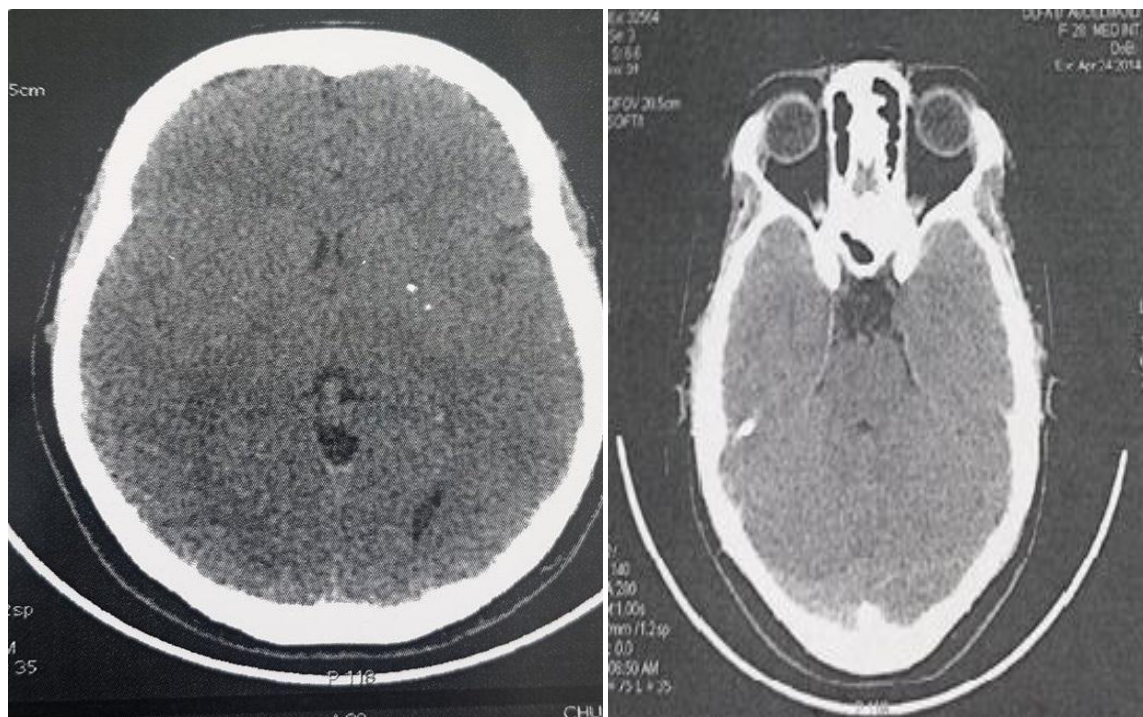


Fig 7 and 8: Angio-CT of the descending and ascending aorta.

Multiple mediastinal and cervical calcifications confluent in places.

Partial stenosing calcification of the left external carotid artery which reduces light to 40%.

Non-obstructive parietal calcification of the right renal artery and the left internal iliac, reducing light by 50 and 30%, respectively.



→ **Fig 9 and 10: Cerebral CT scan.**

Microcalcifications punctiform bilateral lenticular nuclei.

DISCUSSION

It is a table of diffuse arteriosclerosis occurring in a girl of 26 years, having no significant cardiovascular risk factor, nor hypercalcaemia. Few plausible etiologies explain this type of attack in the literature.

We found no clinical or para-clinical evidence for inflammatory vascular disease: no inflammatory biological syndrome, no systemic manifestations other than the Raynaud phenomenon without real parietal vascular thickening in imaging. Nevertheless, the extensive and extra vascular distribution of calcifications argues against this etiology.

Calciophylaxis, or calcifying arterial disease, is a disease characterized by calcification followed by thrombosis of the small vessels of the skin and fat leading to necrotic ulcerations. It occurs in a particular area (chronic terminal renal failure in the hemodialysis stage, hepatocellular insufficiency, alcoholic hepatic cirrhosis, primary hyperparathyroidism, regressive renal insufficiency, paraneoplastic). Unlike mediocalcosis, it is localized at the level of the intima of the arterioles. Initially considered a localized disease, it is increasingly considered a systemic disease.^[1, 2] But in our case there was no predisposing factor for developing calciophylaxis, and the occurrence of large arteries and the normality of the cutaneous biopsy were against this diagnosis.

The inherited diseases of collagen may also be the cause of diffuse arterial calcifications. The diseases of Marfan and Ehlers-Danlos are rarely incriminated. On the other hand, Pseudoxanthoma Elastica (PXE) has frequently been incriminated in the occurrence of diffuse arterial calcifications. It is a rare disease, due to a mutation on the *ABCC6* gene (located on the short arm of chromosome 16) of autosomal recessive transmission. PXE is responsible for a calcifying juvenile arteriopathy that affects the proximal and distal axes with the development of collateral circulation. Patients are often pauci-symptomatic and ischemic complications are rare. A microangiopathic attack, objectified by capillaroscopy, is also present in this disease.^[3-8] In our patient, although the type of vascular and extra vascular disease and the evolutionary mode were suggestive of PXE in the absence of obvious cardiovascular risk factors, she had no skin or ophthalmic signs of the disease, The cutaneous biopsy showed no alteration of the elastic fibers or calcium deposits, the family survey was negative and the genetic study in search of an abnormality of the *ABCC6* gene is not accessible in Tunisia.

Another diagnosis was mentioned: the idiopathic calcified arteriopathy of the child. This is a rare condition seen in children under 3 years of age. It associates arterial calcifications accompanied by

thromboses and occlusive intimal proliferation of coronary arteries with possible involvement of other vessels or the aorta. The clinical picture is non-specific, biologically, calcium and phosphorus are normal and the radiological assessment shows classically vascular calcifications. The prognosis is bleak with early mortality.^[9] This diagnosis was not plausible in our patient before the age and the evolutionary mode of its disease. However, rare cases have been described in young adults.^[10]

The corticosteroid prescribed for its ancient arthritis was it behind the acceleration of arteriosclerosis? The literature is not in favor, such cases were not reported.

CONCLUSION

We present a case of calcifying arteriopathy in a 26-year-old girl whose diagnosis was accidentally discovered and whose exhaustive etiological investigation was negative.

What is already known on this topic

- Arteriosclerosis in this age is exceptional
- Predisposing factors of arteriosclerosis are absent in our case report
- We didn't find an etiology to explain this arteriosclerosis in 26 years old

What this study adds

- Describe asymptomatic arteriosclerosis and its paraclinical findings
- Discuss causes of arteriosclerosis of young people

Competing interests

The authors declare no competing interest.

Authors' contributions

All authors contributed in conception, analysis, drafting the article and revising it critically for important intellectual content; and final approval of the version to be published.

REFERENCES

1. Duval A, Moranne O, Vanhille P, Hachulla E, Delaporte E. Artériopathie calcique (Calciphylaxie). *Rev Med Int.* mars, 2006; 27(3): 184-95.
2. Agaajani S, Becker D, Loute G. Lésions de calciphylaxie chez une patiente en insuffisance rénale terminale. *Louvain Méd.* 2004; 123(7): 210-6.
3. C Francès. Maladies héréditaires du collagène et du tissu élastique. In: *Traité de Médecine.* 2004^e éd.
4. Sène D, Patrice Cacoub. Conduite à tenir devant une artériopathie du sujet jeune [Internet]. *Angéologie « Société Française d'Angéologie ».* [Cited 29 mars 2016]. Available on: <http://www.angiologie.fr/wp/?p=1003>.

5. Perdu J, Champion K, Emmerich J, Fiessinger J-N. Micro angiopathie du pseudo xanthome élastique. *Presse Méd.* 2004; 33(8): 518-21.
6. Finger RP, Issa PC, Ladewig MS, Götting C, Szliska C, Scholl HPN, and al. Pseudoxanthoma Elasticum: Genetics, Clinical Manifestations and Therapeutic Approaches. *Surv Ophthalmol.* Mars, 2009; 54(2): 272-85.
7. Nitschke Y, Rutsch F. Generalized arterial calcification of infancy and pseudoxanthomaelasticum: two sides of the same coin. *Front Genet [Internet].* 24 Dec 2012 [cited 29 mars 2016];3. Available on: <http://www.ncbi.nlm.nih.gov/pmc/articles/PMC3529400/>.
8. Leftheriotis G, Kauffenstein G, Hamel JF, Abraham P, Le Saux O, Willoteaux S, and al. The contribution of arterial calcification to peripheral arterial disease in pseudoxanthoma elasticum. *PloS One.* 2014;9(5):e96003.
9. Michels. Artériopathie calcifiée de l'enfant [Internet]. *Anabible.* [Cited 29 mars 2016]. Available on: <http://anabible.webethan.org/spip.php?article1974>.
10. Ferreira C, Ziegler S, Gahl W. Generalized Arterial Calcification of Infancy. In: Pagon RA, Adam MP, Ardinger HH, Wallace SE, Amemiya A, Bean LJ, et al. Éditeurs. *Gene Reviews (®)* [Internet]. Seattle (WA): University of Washington, Seattle; 2014 [Cited 29 mars 2016]. Available on: <http://www.ncbi.nlm.nih.gov/books/NBK253403/>.