

**A RARE OCCURRENCE OF OVARY-CONTAINING HERNIA OF CANAL OF NUCK IN
A FEMALE CHILD OF TWO YEARS**¹*Dr. P B Nichkaode and ²Dr. R. K Diwakar,¹M.S. Fellow UICC (USA). Professor and Head, Department of Surgery, C.C.M. Medical College and Hospital, Kachandur. Durg, C.G.-India, 490024.²M.D. Department of Radio-diagnosis. C.C.M. Medical College and Hospital, Kachandur. Durg, C.G.-India, 490024.***Corresponding Author: Dr P B Nichkaode**

M.S. Fellow UICC (USA). Professor and Head, Department of Surgery, C.C.M. Medical College and Hospital, Kachandur. Durg, C.G.-India, 490024.

Article Received on 27/03/2017

Article Revised on 17/04/2017

Article Accepted on 07/05/2017

ABSTRACT

We present a case where non-suspicion of the presence of ovary in an inguinal hernia, lead to error in the diagnosis in a child of two years age. Proper sonographic examination in longitudinal as well as transverse plane with 6-12 MHz linear probe and the use of CDU may prove to be key factors for correct diagnosis. The size of the ovary and the presence of cystic lesions are helpful in the diagnosis.

KEYWORDS: Inguinal canal, Hernia, Ovary, Ultrasonography, color Doppler, Canal of Nuck.**INTRODUCTION**

The incidence of inguinal hernia in females is 1.9%, the ratio of boys to girls being 6:1.^[1]

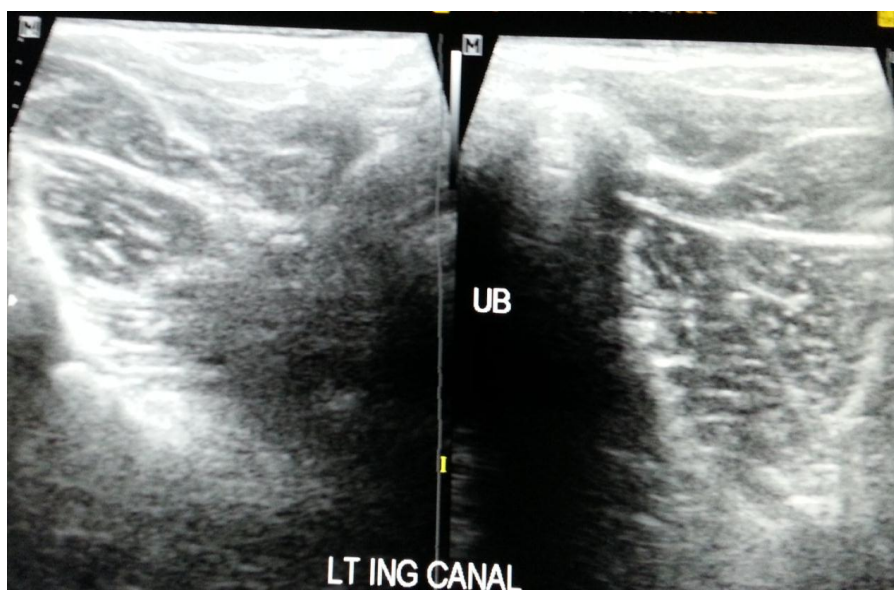
Congenital hernia in female child is a considerable rarity. Failure of obliteration of canal of Nuck results in an indirect inguinal hernia.

CASE REPORT

The parents brought a female child of two years age in the outpatient Department of Surgery, having a swelling in left groin which was noticed by them a week ago.

Physical examination findings were solid-looking inguino-labial reducible swelling in left inguinal area, increasing in size during standing and crying. It reduced in size in lying down position. Positive cough impulse was present. Systemic examination was normal. Chest radiograph was normal. Haematological examination and urinalysis were normal.

Ultrasound examination with 5 MHz linear probe (Fig.1) did not detect any identifiable structure in the inguinal region; hence, colour Doppler ultrasound was not done.

**Fig 1: Sonography of inguinal canal showing solid looking oval shape structure**

Surgical exploration of left inguinal canal revealed the presence of the ovary (Fig.2) in the sac which was gently cleared. The ovary appeared normal for age and was reposed back in the abdomen (Fig.3). Herniotomy was done and the wound was closed in layers. The colour of the surface of the ovary was normal.

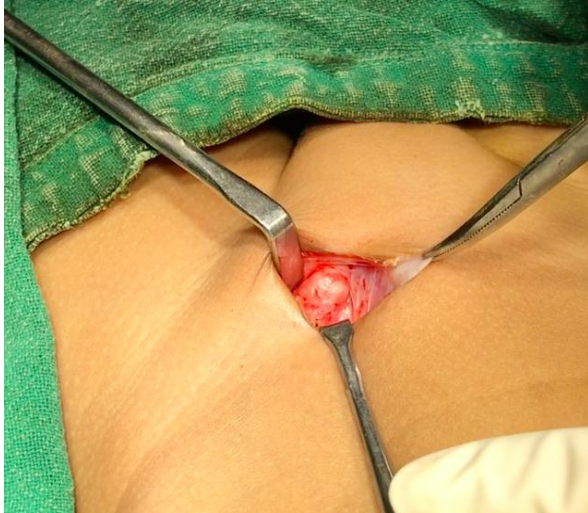

Fig 2: Left ovary in the inguinal canal seen at surgical exploration

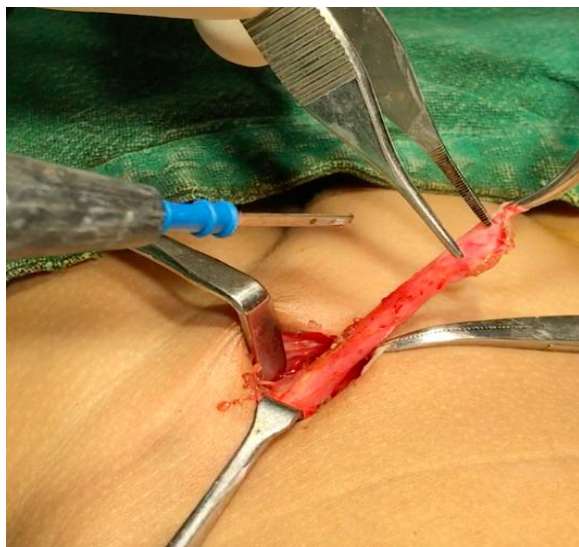


Fig.3: The ovary with the ligament after surgical dissection

Post-operative period was uneventful and the discharge was given on 3rd post-operative day.

DISCUSSION

Embryology

In the female embryo, the ovaries descend into the pelvis but do not leave the abdominal cavity. The upper portion of the gubernaculum becomes the ovarian ligament, and the lower portion becomes the round ligament, which travels through the inguinal ring into the labium majus. If the processus vaginalis remains patent, it extends into the labium majus and is known as the canal of Nuck. In the normally developing female foetus, the canal of Nuck is

usually obliterated by 8 months of gestation. Failure of complete obliteration of this structure results in an indirect inguinal hernia of the canal of Nuck.^[2] In women, the round ligament is attached to the uterus near the origin of the fallopian tube and a small evagination of parietal peritoneum accompanies the round ligament through the inguinal canal to the labium majorum. This small evagination parietal peritoneum named the canal of Nuck in women, is the equivalent of the processus vaginalis in men.^[3]

Incidence

The incidence of ovary as content of inguinal hernia in a paediatric patient of 2 years age is very uncommon & reported to be 1:500000. In 15–20% of the female patients with inguinal hernias, the herniation sac may contain the ovaries and/or the fallopian tubes.^[4]

Sonographic diagnosis

In the case of a hernia containing ovary in the canal of Nuck in female infant, early diagnosis is important because incarceration of the ovary is common and has been reported in up to 43% of cases.^[4] Therefore, a female infant with an inguinal hernia should be evaluated to determine whether the ovarian contents are present. We believe that the ultrasonographic finding of solid masses containing multiple cysts of varying size is a useful sign for the identification of ovary containing hernias.^[4,5,6]

Ultrasonographic findings of ovary torsion are an enlarged, mass-like ovary with heterogeneous echogenicity that contains multiple peripheral cysts and no blood flow within the ovary.^[7,8]

CONCLUSION

To avoid a surprise finding at operation it is advised that possibility of ovary in hernia sac in inguinal canal should be kept in view, 5-7MHz linear probe or high resolution 10-12 MHz linear probe should be used. Careful colour flow study should be done for early diagnosis of incarceration or torsion.

Conflict of interest

Nil.

Source of Funding

None.

REFERENCES

1. Read RC, White JJ. Inguinal herniation. *Am J Surg.*, 1978; 136: 651–657. [PubMed]
2. Yigit H, Tuncbilek I, Fitoz S, Yigit N, Kosar U, Karabulut B. Cyst of the canal of Nuck with demonstration of the proximal canal: the role of the compression technique in sonographic diagnosis. *J Ultrasound Med.*, 2006; 25: 123–125. [Article](#) [PubMed](#)
3. Park SJ, Lee HK, Hong HS, Kim HC, Kim DH, Park JS, et al. Hydrocele of the canal of Nuck in a girl:

- ultrasound and MR appearance. *Br J Radiol*, 2004; 77: 243–244. [Article](#) [PubMed](#)
4. F. C. Laing, B. A. Townsend, and J. R. Rodriguez, “Ovary-containing hernia in a premature infant: sonographic diagnosis,” *Journal of Ultrasound in Medicine*, 2007; 26(7): 985–987. View at Google Scholar · View at Scopus
 5. Kim H C, KimS W, Lim S J, Park S J, Lim J W. Sonographic diagnosis of ovary-containing hernias of the canal of nuck, 2014; 183. <https://doi.org/10.14366/usg.14010>
 6. Goske MJ, Emmens RW, Rabinowitz R. Inguinal ovaries in children demonstrated by high resolution real-time ultrasound. *Radiology*, 1984; 151: 635–636. [PubMed]
 7. Aydin R, Polat AV, Ozaydin I, Aydin G. Gray-scale and color Doppler ultrasound imaging findings of an ovarian inguinal hernia and torsion of the herniated ovary: a case report. *Pediatr Emerg Care*, 2013; 29: 364–365. [PubMed]
 8. Merriman TE, Auldish AW. Ovarian torsion in inguinal hernias. *Pediatr Surg Int*, 2000; 16: 383–385. [PubMed]