

EFFECT OF ELLAGIC ACID ON GASTRIC MUCOSA OF EXPERIMENTALLY INDUCED GASTRIC ULCER: HISTOLOGICAL AND IMMUNOHISTOCHEMICAL STUDYMai M.H. Selim^{1*}, Eman Badwi ElShal² and Azaa H. Abd Elwahab³Histology^{1*}, Anatomy² and Physiology³ Departments, Faculty of Medicine for Girls, Al- Azhar University.***Corresponding Author: Mai M.H. Selim**

Histology, Departments, Faculty of Medicine for Girls, Al- Azhar University.

Article Received on 28/09/2016

Article Revised on 09/10/2016

Article Accepted on 30/11/2016

ABSTRACT

Introduction: Ellagic acid (EA) is one of the naturally occurring polyphenols of plant origin. The EA has been known as a gastroprotective agent of natural plant origin. **Aim of the work:** The current study was designed to evaluate the effect of EA on the gastric mucosal injury induced by aspirin in adult male albino rats. **Materials and Methods:** 48 adult male albino rats were divided into 4 equal groups: group I; control group, group II; E.A. group: in this group the animals received daily oral dose of E.A. (50mg/kg). Group III; aspirin group: in which the animals received (0.2gm/kg) of aspirin as a daily oral dose. Group IV; E.A. & aspirin group: in this group the animals were given both E.A. & aspirin. The experiment was continued for 3 weeks, after which, the stomach samples were collected, processed for histological & immunohistochemical study. The mean number of proliferating cell nuclear antigen (PCNA) positive cells were measured and statistically represented. In addition, gastric Ph, gastric wall mucus content, peptic activity, angiogenic marker, as: Vascular endothelial growth factor (VEGF), oxidative stress markers, and inflammatory marker were also estimated and statistically represented. **Results:** Examination of sections of aspirin group revealed that aspirin induced desquamation of gastric epithelium, which may extend to reach the base of some gastric glands. Mucus contents and angiogenic marker were decreased, while the peptic activity, gastric acidity (gastric ph), oxidative stress, and inflammatory makers were increased. The PCNA positive cells were significantly decreased in this group if compared with the control group. The combined use of EA & aspirin showed generalized improvement of most histological changes and the other parameters, if compared to the control. **Conclusion:** E.A. administration protects the gastric mucosa from damage induced by aspirin.

KEYWORDS: Aspirin, Gastric Mucosa, Ellagic Acid, Proliferating Cell Nuclear Antigen.**INTRODUCTION**

Peptic ulcer (P.U.) is the most common ulcer of an area of the gastrointestinal tract.^[1] It includes gastric and duodenal ulcers.^[2] The P U is caused by many factors such as drugs, stress or alcohol, due to an imbalance between offensive acid pepsin secretion and defensive mucosal factors like mucin secretion and cell shedding.^[1] Gastric ulcer (G.U.) is a common ailment throughout the world, in which the gastric mucosa becomes damaged and perforations lead to bleeding.^[3]

Gastric ulcer is a multietiological disease. Steroidal and nonsteroidal drugs have been shown to play a role in gastric ulcerogenesis.^[4] Non-steroidal anti-inflammatory drugs (NSAIDs) including aspirin (acetyl salicylic acid) are widely prescribed, despite their gastrointestinal side effects. Several regimens have been recommended to prevent serious gastrointestinal complications such as the use of safer NSAIDs and the co-prescription of gastroprotective agents.^[5] Reactive oxygen species (ROS) have been proved to play an important role in the

pathogenesis of gastric ulcer. Accordingly, various regimens of reactive oxygen metabolite scavengers appear to be new treatment strategies for gastrointestinal diseases.^[6]

Thus, there is a growing interest in the scientific community to develop drugs from plant origin, which are cheap, non-toxic, and accessible, particularly to the rural people in the developing countries.^[3] Many studies have attempted to identify the therapeutic constituents of pomegranate.^[1] Ellagic acid (EA) is one of the main constituents of this fruit. EA exhibits powerful anti-carcinogenic and anti-oxidant properties.^[7]

It is one of the naturally occurring polyphenols found in pomegranates, raspberries, strawberries, walnuts, and other plant foods mainly in the form of ellagitannins. Numerous in vitro and animal studies have suggested the anti-proliferative and anti-oxidant properties of EA Also it has been shown to exert a potent scavenging action on both superoxide anion and hydroxyl anion in vitro.^[3]

The current study was conducted to evaluate the effect of EA on the gastric mucosal injury induced by aspirin in adult male albino rats.

MATERIALS AND METHODS

48 adult male albino rats were used in this experiment weighed (160-170 gm). They were kept in clean properly ventilated cages under condition of natural light and dark cycle, free access to food and water was allowed for one week before the beginning of the experiment for acclimatization. The experiment was done at the laboratory of Physiology Department Faculty of Medicine for Girls Al-Azhar University. All procedures were approved by the animal care committee.

The animals were divided into 4 equal groups: **Group I** (control group); **Group II** (EA group): in this group the animals were given a daily oral dose of EA. (50 mg/kg).^[8] It was in the form of powder. **Group III** (aspirin group): in this group the animals were given a daily oral dose of Aspirin (acetyl salicylic acid) in a dose of 0.2 gm/kg.^[9] The drug was in the form of tablets. Both drugs were dissolved in sterile distilled water, given to the animals by orogastric tube. **Group IV** (E.A. & aspirin) group: In this group the animals were given both E.A. and aspirin by the previously mentioned regimen. Ellagic acid was purchased from Sigma-Aldrich Chemical Co (St. Louis, MO, USA). Aspirin was purchased from local pharmacy. Other chemicals and reagents used were of analytical grade. The experiment continued for 3 weeks, after which, the animals were fasted overnight, at the morning the animals were anesthetized by ether inhalation. Stomach samples were collected from only 6 animals from each group be prepared for histological study, while the remaining 6 rats from each group were used for other studies.

The histological tissue samples were prepared by opening each stomach and cleaned it by saline, then examined by magnifying hand lens to detect the site of injury in aspirin group. Corresponding parts of stomach in other groups were collected. Most lesions were detected within the body and fundic regions of the stomach. The samples were fixed in Boun's solution^[10, 11] and processed for 5 micron thick paraffin sections. Sections were stained with H&E for routine histological examination.^[12] Periodic acid Schiff (PAS) to stain the mucous and the mucous secreting cells by pink colour.^[13]

For immunohistochemical study: Avidin-biotin peroxidase technique for Proliferating cell nuclear antigen (PCNA) using monoclonal antibodies^[12] (Dako-Denmark. Diluted 1: 100). The stain was used on 5 micron thick paraffin sections. Positive stain showed brown granules within the cell. PCNA antibodies served as a reliable marker of proliferation.^[14]

Preparation of gastric mucosal homogenate: in this technique 6 rats from each group were used, exposed for ether anesthesia, mid line incision was performed. The

pylorus of the stomach and esophagocardic junction was immediately ligated. Then, the stomach was opened along greater curvature and the gastric content was drained into centrifuge tube, centrifugation at 60 rpm/min for 10 minutes. The gastric juice was used for biochemical assay.

Biochemical assay of the gastric mucosal contents

1- Determination of the gastric mucin contents, to evaluate the effect of aspirin and/or E.A. on gastric mucin production. A modified method of^[15] was used.

2- Measurement of PH of gastric juice, this was done on centrifuged gastric juice digital PH meter according to.^[16]

3- Determination of pepsin activity of gastric juice, which was determined according to the method described by.^[17]

4- Determination of total VEGF level (major angiogenic growth factor) in the gastric mucosa was determined by solid phase sandwich technique (ELISA) using commercial kits (Rat VEGF ELISA kit; IBL, Gesellschaft, Hamburg, Germany) according to.^[18]

5- Estimation of gastric content activity of: - malondialdehyde(MDA). -reduced glutathione (GSH). - myeloperoxidase (MPO) and interleukin 6 (IL-6),^[19] using Biodiagnostic Kits (Egypt). GSH was quantified using Bio diagnostic Kits (Egypt).^[20] The gastric activity of MPO a marker of tissue neutrophil infiltration, was assessed using Biodiagnostic Kits (Egypt) according to.^[21] ELISA Kit (Assaypro, USA) was used for measurement of IL-6 concentration in stomach homogenate.

Morphometric and Statistical studies: the mean number of PCNA –positive cells/high power field of randomly chosen 5 fields per slide. Five slides were used for each group.^[22] Statistical analysis was done for the mean number of PCNA positive cells, and for other parameters obtained from gastric homogenate, by using the (t) test for data evaluation and for comparison between the experimental groups. Data was expressed as means \pm Standard Deviation (SD). P value \leq 0.05 was considered statistically significant. The findings were represented in tables (1,2) and table (3) and histogram (1) for PCNA.

RESULTS

Histological results

Light microscopic examination of group I; control group of H & E stained gastric mucosal sections of stomach body and fundic regions showed that the gastric mucosa at the fundus & body were histologically identical. The gastric mucosa was formed of 3 layers, epithelium which was interrupted by gastric pits, connective tissue (C.T.) layer or lamina propria which was occupied by the gastric glands, and the muscularis mucosa fig (1).

The lamina propria of fundus and body of the stomach was occupied by overcrowded straight tubular glands, the gastric glands which were differentiated into 3 parts; inner most isthmus, middle neck and outer base fig (1). The gastric glands contained a mixed population of cells, they were, mucus secreting cells that covered the luminal surface of the stomach and lined the gastric pits into which one or two of the gastric glands opened. These cells were columnar having basal oval nuclei within poorly stained vacuolated cytoplasm. Acid secreting cells, oxyntic or parietal cells were distributed along the length of the glands but tended to be most numerous in the middle portion. These cells were large, rounded have deeply eosinophilic cytoplasm with centrally located vesicular nuclei. Pepsin secreting cells, peptic or chief cells, were located towards the bases of the gastric glands. Peptic cells were recognized by basally located rounded vesicular nuclei and strongly basophilic granular cytoplasm. The muscularis mucosa lying immediately beneath the base of the gland fig 2(A,B,C).

Examination of H & E stained sections of group II (EA group) showed no variation between this group and the control group fig 3(A,B).

Examination of H&E stained sections of group III (aspirin group) showed that the gastric glands were preserved with their general architecture. Partial discontinuity, disorganized, sloughed epithelium and widening of gastric pits. Such pits usually contained detached cells and tissue ruminants. Some parietal cells were vacuolated eroded with dark pyknotic nuclei fig 4 (A,B). The bases of the glands showed some vacuolation and disorganization. The oxyntic cells were detected with darkly stained condensed nuclei. The chief cells appeared to be more resistant to the injury, in spite of that some of them contained small darkly stained pyknotic nuclei detected specially at the site of injury. Some other peptic cells appeared vacuolated with darkly stained small nuclei. The muscularis mucosa was apparently healthy fig (5).

Examination of H &E stained sections of group IV (EA & aspirin group) showed that the structure of the gastric mucosa was comparable with that of the control group. The mucosa appeared intact with regularly arranged gastric glands. Surface columnar mucous secreting cells appeared intact with oval shaped nuclei and apical vacuolated cytoplasm. The raw gastric surface was covered by flat or cubical cells. Collection of fusiform or flat cells with flat vesicular nuclei were also detected covering the gastric mucosal surface, forming many layers fig (6). The Parietal cells appeared with central rounded vesicular nuclei and acidophilic cytoplasm. They were distributed throughout the gland. The chief cells appeared lining the bases of the glands, they had basophilic cytoplasm, and basally located vesicular rounded nuclei fig (7).

PAS stained sections results

Control group showed that there was a continuous PAS positive coat covering mucosal surface of the stomach, also the surface columnar mucous secreting cells were PAS positive fig (8). Group II showed picture similar to the control group fig (9). Examination of aspirin group showed absence of the PAS positive mucous layer, the PAS positive cells were less prominent than those of the control group fig (10). Examination of sections of group IV showed that the gastric mucosa was covered by PAS positive mucus layer in some sections it was apparently thin than the control, while in others it showed broad similarity to the control, in general the PAS positive mucous coat was prominent and continuous. The mucous secreting cells were PAS positive having the same pattern of distribution as those of the control fig 11 (A,B).

Immunohistochemical results: the PCNA positive cells showed dark brown cytoplasmic granules. These positive cells were concentrated nearly at the middle zone of the gastric glands in control fig (12) and other experimental groups. The PCNA positive cells were detected in control and EA groups were the most numerous fig (13, 14). The PCNA positive cells were fewer in group III if compared to the control group fig (15). Numerous immunopositive cells were detected in group IV which more or less similar to the control fig (16).

Statistical and morphometric results: Statistical analysis of the aspirin administered group (group III) showed that the gastric pH, VEGF and gastric mucus content were significantly decreased in this group while pepsin activity was significantly increased if compared to the control group.

Concomitant treatment of EA and aspirin ameliorating the destructive effect of aspirin on gastric mucosa as demonstrated by the significant increase in gastric pH, significant lowering of pepsin activity as well as the significant increase in gastric mucin content and VEGF expression ($P < 0.05$) if compared to aspirin administered group. But this improvement could not reach to control values as there was a significant difference in all the measured parameters if compared to EA treated group (group IV), table (1).

Statistical analysis of the aspirin administered group showed significant increase in oxidative stress markers mainly increased MDA and decrease GSH. The inflammatory markers which were represented by MPO and IL-6 were increased if compared to control group ($P < 0.05$).

All the previous parameters were improved in aspirin group treated by EA (group IV). This group showed significant lowering of MDA, elevation of GSH and significant decrease in MPO and IL-6 ($P < 0.05$) if compared to aspirin administered group table (2).

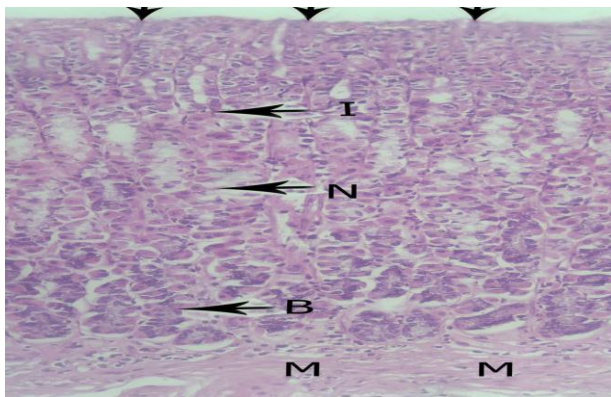


Fig (1): showing gastric mucosa formed of •surface epithelium (arrow heads). •lamina propria occupied by regularly arranged tubular fundic glands, each gland composed of isthmus (I), neck (N) and base (B). • muscularis mucosa (M). H&E x 200 control

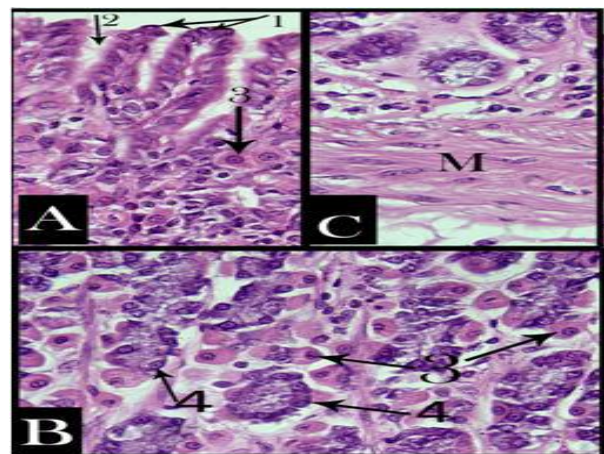


Fig (2): A: showing surface columnar epithelium (1), gastric pit (2), oxyntic cell (3), B: showing basal part of gastric gland rich in oxyntic cells (3) and peptic cells (4), C: showing basal muscularis mucosa (M). H&E x400 control

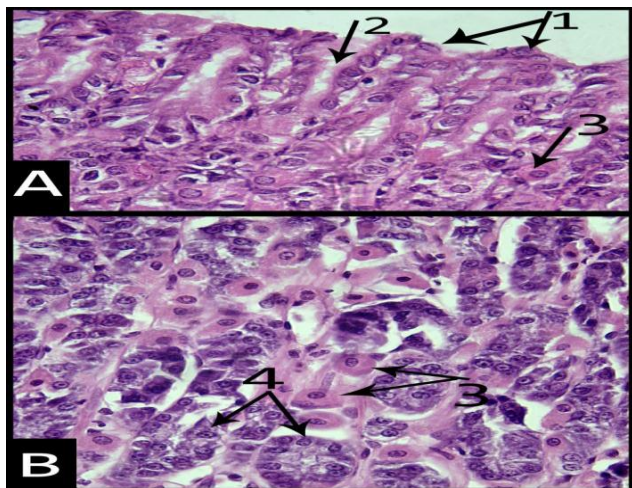


Fig (3): A: showing the surface columnar epithelium (1), gastric pit (2) and oxyntic cell (3), B: showing the basal part of gastric glands, numerous oxyntic cells (3) and peptic cells (4) can be seen. H&E x400 group II

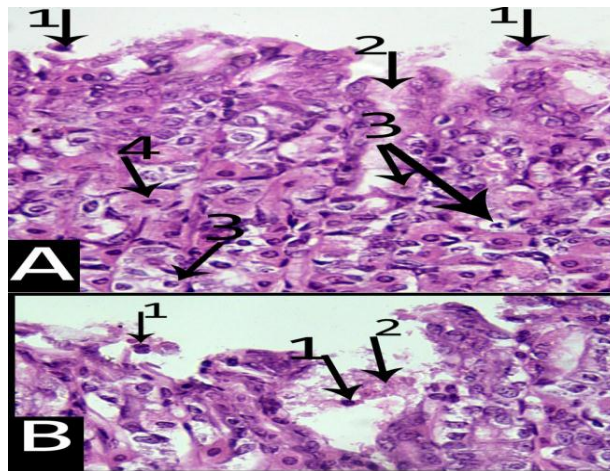


Fig (4): A: showing disrupted surface epithelium, detached cells (1), acidophilic remnants (2), degenerated cells (3) and oxyntic cell with darkly stained pyknotic nucleus (4), B: showing disorganized discontinuous surface epithelium, detached cells (1) and acidophilic remnants (2). H&E x400 group III

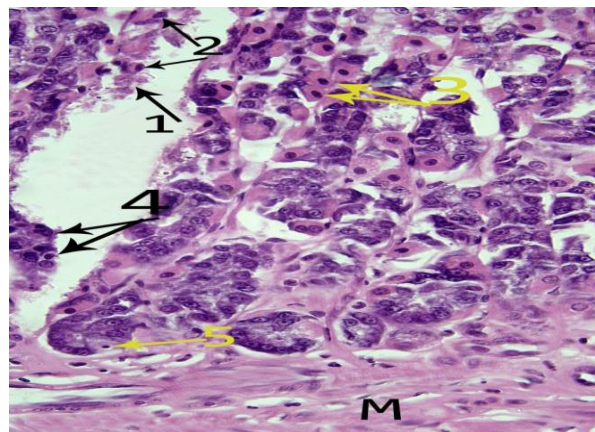


Fig (5): showing gastric ulcer reaching the base of the gastric gland, acidophilic remnants (1), oxyntic cells with darkly stained pyknotic nuclei (3), peptic cells with dark small nuclei (4), peptic cells replaced by pale cell with dark small nuclei, the injury does not reach muscularis mucosa (M). H&E x400 group III

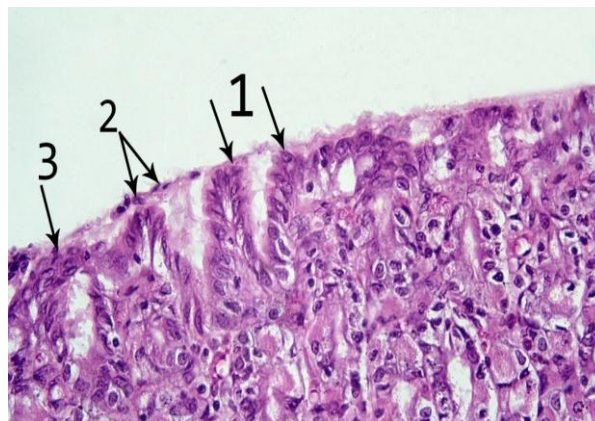


Fig (6): showing the surface columnar cells (1), flat or rounded cells cover part of surface mucosa (2), collection of fusiform cells (3). H&E x400 group IV.

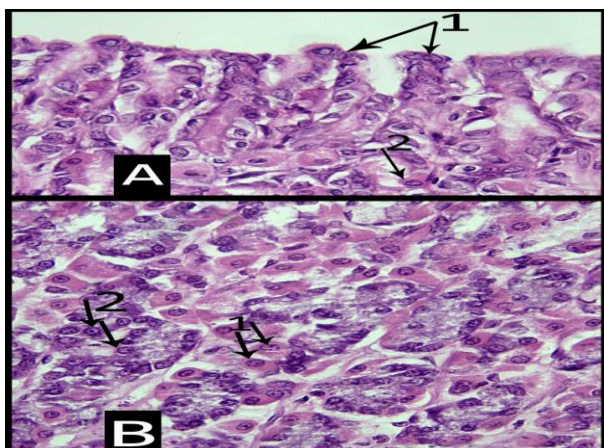


Fig (7): A: showing surface columnar cells (1), oxyntic cells (2), B: showing basal part of the gland rich in oxyntic cells (1), peptic cells (2). H&E x400 group IV

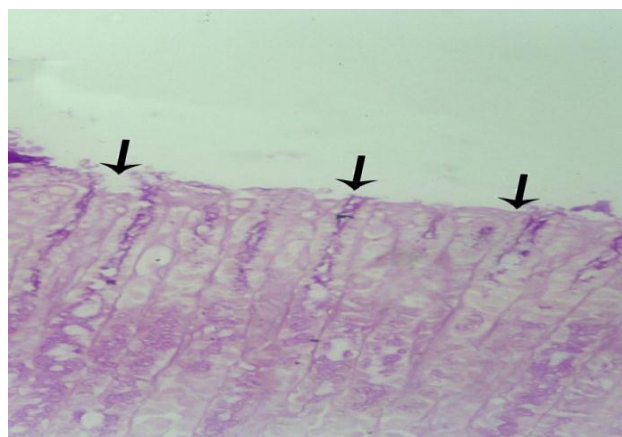


Fig (10): showing raw gastric surface with absent PAS positive mucus layer (arrows). PAS x400 group III

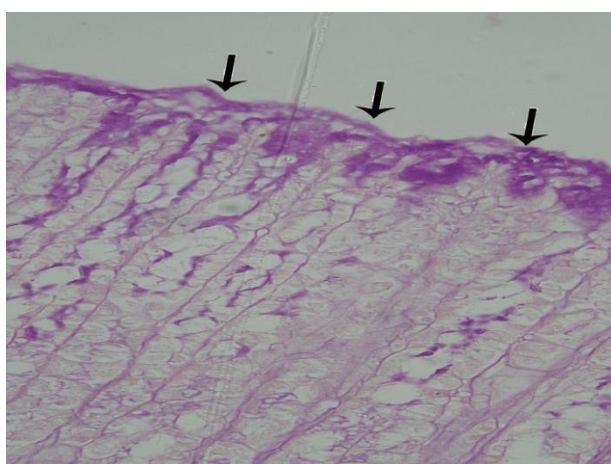


Fig (8): showing PAS positive mucus layer (arrows). PAS x400 control

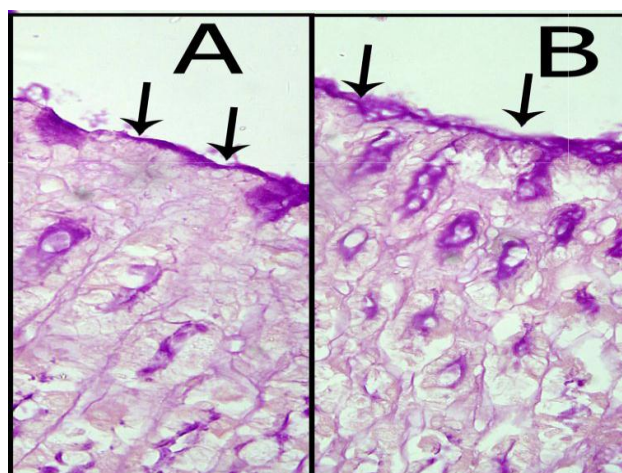


Fig (11): A: showing apparently thin layer of PAS positive mucus layer, B: showing PAS positive mucus layer similar to the control (arrows). PAS x400 group IV

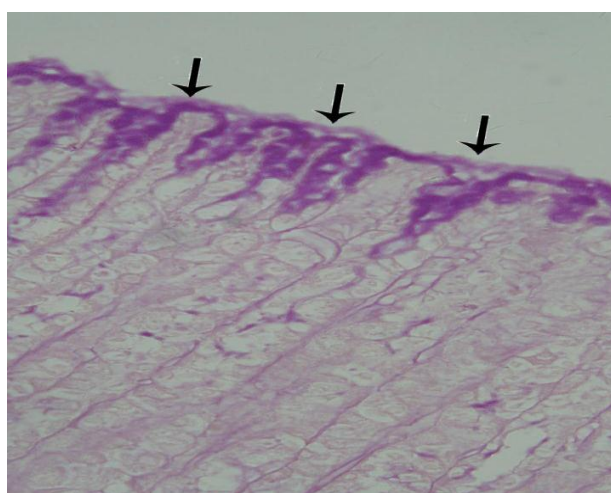


Fig (9): showing PAS positive mucus layer (arrows). PAS x400 group II

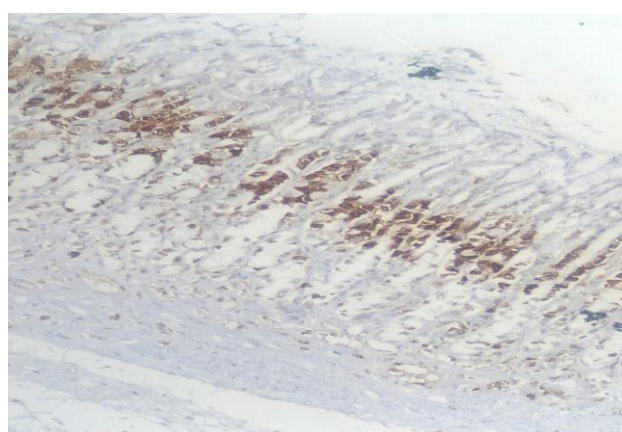


Fig (12): showing the PCNA positive cells appear brown and concentrated at the middle zone of the gastric glands. Avidin- biotin x100 control

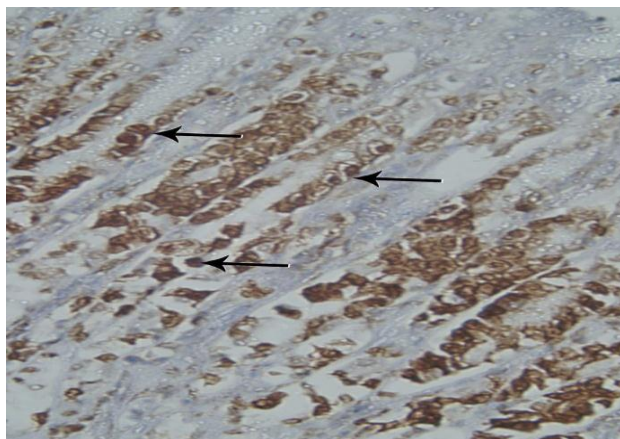


Fig (13): showing the PCNA positive cells (arrows).
Avidin- biotin x 400 control

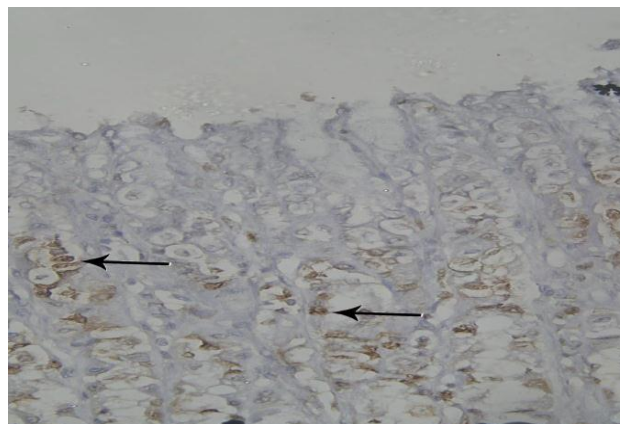


Fig (15): showing fewer PCNA positive cells (arrows).
Avidin – biotin x400 group III

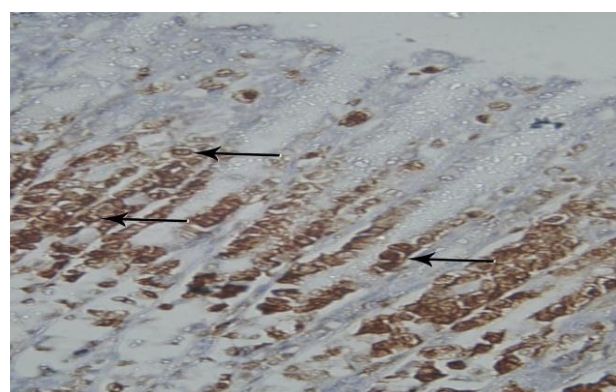


Fig (14): showing the PCNA positive cells (arrows).
Avidin – biotin x 400 group II

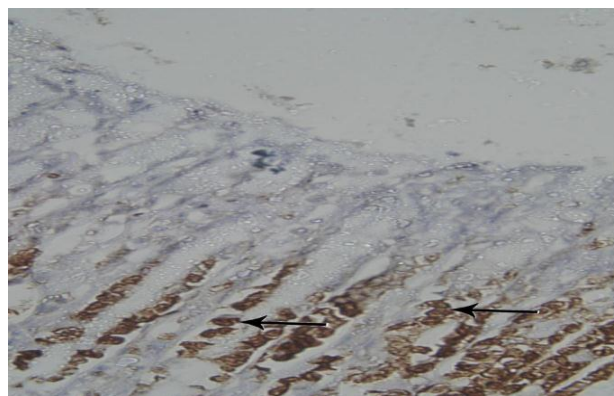


Fig (16): showing the PCNA positive cells (arrows).
Avidin – biotin x 400 group IV.

Table (1): The mean values of gastric pH, pepsin, gastric mucin content and (VEGF) in different experimental groups.

Parameters	Groups				ANOVA	
	Control group Mean± S.E.M	Ellagic Acid treated group Mean± S.E.M	Aspirin administered group Mean± S.E.M	Aspirin +Ellagic Acid group Mean± S.E.M	F	P- value
Gastric pH	4.1±0.02	3.9 ±0.04	2.4 ^a ± 0.03	3.5 ^{b,c} ± 0.01	7.09	0.003
Pepsin (µm/ml)	370.6 ±13.3	354.9 ± 21.4	533.8 ^a ± 18.2	287.4 ^{b,c} ±16.46	17.1	0.000
Gastric Mucin content (ug alcian blue/g of glandular tissue)	410.9 ± 17.3	426.2 ± 24.6	226.7 ^a ±14.6	349.07 ^{b,c} ± 28.7	35.8	0.000
VEGF (pg/mg)	65.3 ±1.2	67.8 ±1.1	31.5 ^a ±0.9	56.9 ^{b,c} ±1.6	8.8	0.001

a: significant values compared to control.

b: significant values compared to aspirin administered group (group III).

c: significant values compared to Ellagic acid treated group (group IV).

Table (2): The mean values of MDA, GSH, MPO and IL-6 in the different experimental groups.

Parameters	Groups				ANOVA	
	Control group Mean± S.E.M	Ellagic Acid treated group Mean± S.E.M	Aspirin administered group Mean± S.E.M	Aspirin +Ellagic Acid group Mean± S.E.M	F	P- value
MDA (µmol/mg ptn.)	17.3 ± 1.5	13.9 ± 0.9	87.03 ^a ± 5.7	39.1 ^{b,c} ±1.7	11.9	0.000
GSH (µmol/mg ptn.)	8.5 ± 1.2	9.4 ± 1.1	4.2 ^a ± 0.2	7.4 ^{b,c} ± 0.46	11.7	0.000
MPO (µ/g)	4.9 ± 0.6	5.2 ± 0.6	19.7 ^a ± 2.6	9.7 ^{b,c} ± 0.7	3.2	0.03
IL-6 (pg/ml)	1.5 ± 0.09	1.8 ± 0.07	16.1 ^a ± 1.4	2.4 ^{b,c} ± 0.09	9.8	0.000

a: significant values compared to control.

b: significant values compared to aspirin administered group (group III)

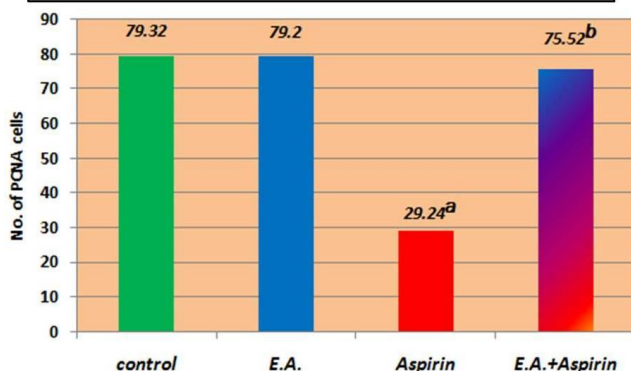
c: significant values compared to E A. treated group (group IV)

Table (3): The mean number of PCNA positive cells in different experimental groups

Parameters	Control group	Ellagic Acid treated group	Aspirin administered group	Aspirin +Ellagic Acid group	ANOVA	
	Mean± S.E.M	Mean± S.E.M	Mean± S.E.M	Mean± S.E.M	F	P- value
No. of PCNA +ve cells	79.3 ± 1.1	79.2 ± 1.2	29.2 ^a ± 5.7	75.5 ^b ± 1.3	6.9	0.000

a: significant values compared to control.

b: significant values compared to aspirin administered group.

Histogram 1 : The mean number of PCNA positive cells in the different experimental groups

a: significant values compared to control.

b: significant values compared to aspirin administered group.

DISCUSSION

Aspirin is widely used as anti-inflammatory analgesic drugs and in prevention of cardiovascular events. Serious gastrointestinal side effects especially peptic ulcerations and gastrointestinal bleeding are the cause of major limitations of its clinical application. One of the new strategies to limit the gastric mucosal injury induced by aspirin was adding antioxidant.^[23] EA is a natural polyphenolic, found in several fruits as pomegranate. The EA has anti-proliferative and antioxidant properties which may play a role in gastric ulcer amelioration.^[3]

In the current experiment, the histological examination of control group and EA group showed no histological variations, this may be attributed to the antioxidant of EA found naturally in many vegetables and fruits.^[3] Some authors^[24] in their study on human patients with carotid artery stenosis demonstrated that the consumption of (121 mg/L) of EA for up to 3 years has no toxic effect.

Examination of aspirin group (group III) in the current experiment showed discontinuous gastric epithelium, the gastric ulcer was superficial or deep to reach the base of the gastric gland. Mucosal erosion, loss of continuity of the epithelial lining is a common feature of acute gastritis.^[25] If the defect is severe enough to penetrate the muscularis mucosa to involve the submucosa this becomes an ulcer.^[26] On contrast^[27] said that peptic ulcers are areas of degeneration and necrosis of gastrointestinal mucosa exposed to acid- peptic secretion, commonly seen in the stomach. It is multifactorial, one of its causes is aspirin intake, the resulting ulcer is shallow and do not invade the muscular layer.

Some researchers^[22] mentioned that in their experiment the administration of aspirin for 2 weeks induced widening of gastric pits and desquamation of mucosal cells, moreover the prolonged period of aspirin administration for 4 weeks resulted in more extensive lesions.

Similar findings were detected by^[28] who explained the cause of these alterations by decreasing antioxidant enzymes with aspirin. On the other side, others^[29] found that the aspirin administration was increasing the volume of gastric juice secretion and total acidity leading to sloughing and ulceration of the mucosa. These previous findings are in accordance to the results noticed in the current experiment as the gastric pH recorded its lowest value in aspirin group (group III) together with highest level of pepsin activity which represent an injurious agent to gastric mucosa.^[30] mentioned that gastric injury after aspirin administration may result from an increase in the number of parietal cells with consequent increase in gastric acidity.

The current experiment showed some degenerative changes of the oxyntic and peptic cells. Some authors^[22] noticed similar changes which could be explained by^[23] that the cause of these changes is the generation of reactive oxygen species (ROS) resulting in oxidative damage in cellular membrane and cell lysis. Another explanation was offered by^[31] who attributed these changes to increased mitochondrial permeability, mitochondrial failure and translocation of intramitochondrial protein (apoptosis-inducing factor).

In the current work, the peptic cells may be more resistant than the oxyntic and mucous columnar cells. This may be explained by the location of these cells which make them more exposed to the injurious effects of aspirin than peptic cells that are present deeper in the gland. Scientists^[32] mentioned that the surface mucous cells line the lumen and the gastric pit, mucous neck cells present in the neck of the glands, parietal cells present among the mucous neck cells and throughout deeper part of the gland while the peptic cells predominate in the lower region of the gastric glands.

The PAS stain showed absence of PAS mucous layer leaving raw unprotected surface of gastric mucosa, this was evidenced by the decrease of the estimated gastric mucus content, that was detected in group III in the current experiment.^[33] explained these findings by the direct cytotoxic effect of aspirin while,^[34] added that the absence of gastric mucus protective layer was due to the

accumulation of oxygen free radicals.^[35] stated that the non-steroidal anti-inflammatory drugs (NSAIDs) cause suppression of cyclo-oxygenase enzyme and inhibition of prostaglandin synthesis which was the cause of mucous layer loss from the gastric mucosa.^[23] had another explanation that aspirin which causes gastric injury might lead to decrease in the number of mucous cells.

The PCNA positive cells in control group and in other groups were concentrated nearly at the middle zone of the gastric glands, because the continuously dividing stem cells are concentrated mostly at this region as described by^[32] who mentioned that the stem cells of gastric glands are pluripotent stem cells producing progenitor cells for all other epithelial cells. These cells are found within the epithelium lined the isthmus (narrow segment between the gastric pit and the gastric gland).

In the present work PCNA positive cells showed significant decrease in their number in aspirin group (group III), which means decrease in the proliferating capacity of stem cells. Similar finding was detected by^[36, 37, 33] explained this finding by that the aspirin reduced the binding capacity of the epithelial growth factors to its receptors thus inhibit cell proliferation. On the other hand,^[38] in their experimental data showed that traditional NSAIDs delay the healing of gastro-duodenal ulcers by interfering with action of growth factors and decrease angiogenesis in ulcer bed.

Administration of EA with aspirin in group VI ameliorated the previous changes as the EA exert a potent scavenging action on both superoxide anion and hydroxyl anion in vitro.^[39] EA can provide significant protection to colonic mucosa during the inflammatory response in dextran sulfate sodium- induced ulcerative colitis and reduce the mucosal injury, by inhibition of myeloperoxidase (MPO) activity as well as lipid peroxidation.^[40] The MPO activity is known to increase under ulcerated condition, and reduced during the healing process.^[41] It is often used as a risk marker and diagnostic tool for assessing severity of gastric ulcer.^[42] Indomethacin showed augment MPO activity in ulcerated area of gastric wall, while EA reduced the MPO activity.^[3] This finding was also noticed in group IV in the current experiment.

In the current work in group IV, rounded or flat cells were detected within the lining epithelium of the gastric mucosa, also the presence of unusual many layers of fusiform cells within the mucosal epithelium. The number of PCNA positive cells were nearly similar to the control group. These findings may be explained by^[43] who stated that, stem cells of gastric glands proliferate to replace all of the specialized cells lining the fundic glands, gastric pits and luminal surface. Newly formed cells migrate to their new location either deep into the gland or up into the gastric pit and gastric lining.

The ulcer healing was described^[44] as epithelial reconstitution performed by proliferation of undifferentiated epithelial precursors, which migrate from the ulcer border to the granulation tissue thus covering the base of the ulcer.^[27] added that the tissue repair is a healing by angiogenesis and proliferation of fibroblasts. Thus the cells which were detected within the epithelial gastric mucosa may be a sign of ulcer healing which was accelerated in group IV by the concomitant administration of EA with aspirin. Some researchers^[44] mentioned that the polyphenols have free radical scavenging properties, that protects the prostaglandins which stimulates mucus and bicarbonate production. They also added that the polyphenol are able to inhibit the proton pump present in the parietal cells.

VEGF was elevated in group VI, this VEGF triggers proliferation and migration of cells and accelerates ulcer healing by promoting angiogenesis.^[45,46,47,3] in their results found that the indomethacin decreased mucosal VEGF and EA administration enhanced growth factor levels as VEGF, EGF, and HGF.

In the present work (group IV) the gastric mucosa has acquired PAS positive mucus layer, also the gastric mucous content was increased. because EA provides mucosal protective action in the stomach against ethanol or ischemia-reperfusion injury. Its potency is equivalent to anti-oxidative agent superoxide dismutase.^[39,48,3] This may explain why the oxidative stress markers were decreased in the current work in group IV.

The current experiment showed that the inflammatory and oxidative stress markers were significantly decreased in group IV. Similar findings were detected by^[3] in their experiment, they recorded a significantly decrease in inflammatory cytokines as IL-6 and TNF- α . Some scientists^[49] mentioned that the EA has anti-inflammatory and anti-oxidative actions.

CONCLUSION

EA have the ability to protect the gastric mucosa in cases of exposure to aspirin to a great extent.

REFERENCES

1. Moghaddam, G.; Scharifzadeh, M.; Hassanzadeh, G.; et al: Anti-ulcerogenic activity of the pomegranate peel (*punica granatum*) methanol extract. *Food and Nutrition Sciences*. 2013; 4: 43-48.
2. Choudhary, M. K.; Boda khe, S. H. and Gupta, S. K. Assessment of the antiulcer potential of moringa oleifera root-bark extract in rats. *J. Acupuncture and Meridian stud*. 2013; 6(4): 214-220.
3. Chatterjee, A.; Chatterjee, S.; Das, S.; et al Ellagic acid facilitates indomethacin- induced gastric ulcer healing via COX-2 up-regulation. *Acta Biochim Biophys Sin*. 2012; XX: 1-12.
4. Suleymana, H.; Cadirci, E.; Albayraka, A.; et al Comparative study on potential of some

- antidepressants in indomethacin- induced ulcer in rats. *Chem. Biol. Interact.* 2009; 15: 318-324.
5. Ishikawa, S.; Inaba, T.; Mizuno, M.; et al Incidence of serious upper gastrointestinal bleeding in patients taking non-steroidal anti-inflammatory drugs in Japan. *Acta. Med. Okayama.* 2008; 62: 29-36.
 6. Sehirli, O.; Tatlidede, E.; Yuksel, M.; et al Antioxidant effect of alpha lipoic acid against ethanani- induced gastric mucosal erosion in rats. *Pharmacology.* 2008; 81: 173-180.
 7. Farzaei, M. H.; Abdollahi, M.; Rahimi, R. Role of dietary polyphenols in the management of peptic ulcer. *W. J. G.* 2015; 21(21): 6499-6517.
 8. Girish, C.; Shweta, O.; Raj, V.; et al Ellagic acid modulates sodium valproate induced reproductive toxicity in male wistar rats. *Indian J. Physiol Pharmacol.* 2014; 58(4): 416-422.
 9. Khalil, J.; Akhter, S.; Shabir, A.; et al Gastric ulcer healing effects of nigella sativa; A comparative experimental study with cimetidine. *Biomedica.* 2010; 26: 61-65.
 10. Drury, R. A. and Wallington, E. A. *Histological techniques.* 5th ed. Oxford. NY. Toronto; Oxford University Press. 1980; 520.
 11. Carson, F. L. and Hladik, C. *Histotechnology, A self instructional text.* 3rd ed. Chicago; American Society for clinical pathology. 2009: 161.
 12. Bancroft, J. D. and Stevens, A. *Theory and practice of histological techniques.* 4th ed. Churchill Living Stone. Edinburgh and London. P. 1996; 100: 276-279.
 13. Sheehan, D. C. and Hrapchak, B. B. *Theory and practice of histotechnology.* 2nd ed. The C. V. Mosby Company. Toronto and London. 1980: 166.
 14. Tomanek, M. and Chronowska, E. Immunohistochemical localization of proliferating cell nuclear antigen (PCNA) in the pig ovary. *Folia Histochemica EJ Cytobiologica.* 2006; 44(4): 269-274.
 15. Corne, S. J.; Morrissey, S. M.; Woods, R. J. A method for the quantitative estimation of gastric barrier mucus. *J. Physiol. (London),* 1974; 242: 116-117.
 16. Parmar, N. and J. Desai, A review of the current methodology for the evaluation of gastric and duodenal antiulcer agents. *Indian J Pharmacol,* 1993; 25: 120-135.
 17. Sanyal, A. P.; Denath, O. K.; Bhattacharya, S. K. and Gode, K. D. (1971): The effect of cyproheptadine on gastric acidity. In C. J. Pfeiffer (Ed.), *Peptic Ulcer:* 312-318. Munksgaard, Copenhagen, Denmark: Scandinavian University Books.
 18. Yao, D.; Wu, X.; Y. Zhu, G. Shi, Z. Dong, D. Yoo, W. Wu, L. Oiu and X. Meng Quantitative analysis of vascular endothelial growth factor, microvascular density and their clinicopathologic features in human hepatocellular carcinoma. *Hepatobiliary Pancreat. Dis. Int.,* 2005; 4(2): 220-226.
 19. Mihara, M. and Uchiyama, M. Determination of malonaldehyde precursor in tissues by thiobarbituric acid test. *Annual Biochem,* 1978; 86: 271-278.
 20. Ellman GL. Tissue sulfhydryl groups. *Arch Biochem Biophys,* 1959; 82: 70-7.
 21. Bradley PP, Priebe DA, Christensen RD, Rothstein G. Measurement of cutaneous inflammation: estimation of neutrophil content with an enzyme marker. *J Invest Dermatol.* 1982; 78: 206-209.
 22. Yehia, N. M.; Abdel Salam, N. F.; Saleh, H. A, et al Effect of α -lipoic acid on fundic gastric mucosal damage induced by acetyl salicylic acid: a histological study. *Egypt. J. Histol.* 2014; 37: 280-291.
 23. Seleem, H. S.; Ghobashy, H. A. and Zolfakar, A. S. Effect of aspirin versus aspirin and vitamin C on gastric mucosa (fundus) of adult male albino rats. *Histological and Morphometric Study.* *Egypt. J. Histol.* 2010; 33(2): 313-326.
 24. Aviram, M.; Rosenblat, M.; Gaitini, D.; et al pomegranate juice consumption for 3 years by patients with carotid artery stenosis reduces common carotid intima-media thickness, blood pressure and LDL oxidation. *Clin. Nutr.* 2004; 23: 423-433.
 25. Levison, D.; Reid, R.; Burt, A. D.; et al *Muir's textbook of pathology.* 14th ed. Edward Arnold. Great Britain. 2008: 221.
 26. Kumar, P. and Clark, M. *Kumar & Clark Clinical Medicine.* 6th ed. International student edition. 2005: 265.
 27. Mohan, H. *Textbook of pathology.* 7th ed. The health sciences publishers. New Delhi, London and Philadelphia. 2015: 116-P: 521.
 28. Prakash, M.; Balamurugan, M.; Parthasarathi, K.; et al Anti-ulcer and anti-oxidative properties of "earthworm paste" of lampito mauritii (kinberg) on Rattus norvegicus. *Eur. Rev. Med. Pharmacol. Sci.* 2007; 11: 9-15.
 29. D'Argenio, G.; Mazzone, G.; Tuccillo, C.; et al Apple polyphenol extracts prevent aspirin- induced damage to the rat gastric mucosa. *Br. J. Nutr.* 2008; 100: 1228-1236.
 30. Martinez, A. O.; Sanchez de Medina, F. Jr.; Sanchez de Medina, F. Effect of psychogenic stress on gastrointestinal function. *J. Physiol. Biochem.* 2000; 56(3): 259-274.
 31. Leung, A. M.; Redlak, M. J.; Miller, T. A. Aspirin-induced mucosal cell death in human gastric cells: role of a caspase-independent mechanism. *Dig. Dis. Sci.* 2009; 54: 28-35.
 32. Mescher, A. L. *Junqueira's basic histology. Text & Atlas.* 13th ed. McGraw Hill New York, Chicago, San Francisco, London and Madrid. 2013: 289.
 33. Wallace, J. L. Prostaglandins, NSAIDs, and gastric mucosal protection: why doesn't the stomach digest itself? *Physiol. Rev.* 2008; 88: 1547-1565.
 34. Kwicien, S.; Konturek, P. C.; Sliwowski, Z.; et al Interaction between selective cyclooxygenase inhibitors and capsaicin-sensitive afferent sensory neurons in pathogenesis of stress-induced gastric

- lesions. Role of oxidative stress. *J. Physiol. Pharmacol.* 2012; 63: 143-151.
35. Perini, R.; Fiorucci, S.; Wallace, J. L. Mechanisms of nonsteroidal anti-inflammatory drug-induced gastrointestinal injury and repair: a window of opportunity for cyclooxygenase- inhibiting nitric oxide donors. *Can. J. Gastroenterol.* 2004; 18: 229-236.
36. Hritz, I.; Herszenyi, L.; Molnar, B.; et al Proton pump inhibitor Co-therapy normalizes the increased cell turnover of the gastric mucosa both in NSAID and selective COX-2 users. *Int. J. Immunopathol. Pharmacol.* 2005; 18: 75-84.
37. Mallika, J.; Vijaimohan, K.; Kannan, K. *Cissus quadrangularis* L extract attenuates chronic ulcer by possible involvement of polyamines and proliferating cell nuclear antigen. *Scan. J. Gastroenterol. Suppl.* 2010; 6: 225-233.
38. Folkman, J. and Shin, Y. Angiogenesis. *J. Biol. Chem.* 1992; 267: 10931-10934.
39. Lino, T.; Nakahara, K.; Miki, W.; et al Less damaging effect of whisky in rat stomachs in comparison with pure ethanol. *Digestion.* 2001; 64: 214-221.
40. Ogawa, Y.; Kanatsu, K.; Lino, T.; et al Protection against dextran sulfate sodium-induced colitis by microspheres of ellagic acid in rats. *Life. Sci.* 2002; 71: 827-839.
41. Krawisz, J. E.; Sharon, P.; Stenson, W. F. Quantitative assay for acute intestinal inflammation based on myeloperoxidase activity. *Gastroenterology.* 1984; 87: 1344-1350.
42. Jones, M. K.; Wang, H.; Peskar, B. M.; et al Inhibition of angiogenesis by nonsteroidal anti-inflammatory drugs: insight into mechanisms and implications for cancer growth and ulcer healing. *Nat. Med.* 1999; 5: 1418-1423.
43. Gartner, L. P. and Hiatt, J. L. *Color textbook of histology.* 2nd ed. W. B. Saunders Company. Philadelphia, London, New York and Sydney. 2001: 379.
44. Talaat, R. M.; Abdel-Hakem, N. E.; El-Toumy, S. A.; et al Anti-angiogenic and anti-inflammatory activity of punica granatum peel on experimentally-induced gastric ulcer in rats. *RJPBCS.* 2014; 5(5): 42-56.
45. Risau, W. Mechanism of angiogenesis. *Nature.* 1997; 386: 671-673.
46. Tarnawski, A.; Szabo, I. L.; Husain, S. S.; et al Regeneration of gastric mucosa during ulcer healing is triggered by growth factors and signal transduction pathways. *J. Physio-Paris.* 2001; 95: 337-344.
47. Takahashia, M. Promoters of epithelialization induce expression of vascular endothelial growth factor in human gastric epithelial cells in primary culture. *FEBS. Let.* 1997; 418: 115-118.
48. Lino, T.; Tashima, K.; Umeda, M.; et al Effect of ellagic acid on gastric damage induced in ischemia rat stomachs following ammonia or reperfusion. *Life. Sci.* 2002; 70: 1139-1150.
49. Beserra, A. M. S.; Calegari, P.I.; Souza, M. C.; et al Gastroprotective and ulcer –healing mechanisms of Ellagic acid in experimental rats. *J. Agri. Food Chem.* 2011; 59: 6957- 6965.