

**INFECTIVE ENDOCARDITIS IN DOGS: A REVIEW**Omobowale T.O.\*<sup>1</sup>, Otuh P.I.<sup>2</sup>, Ogunro B.N.<sup>2</sup>, Adejumobi O.A.<sup>1</sup> and Ogunleye A.O.<sup>3</sup><sup>1</sup>Department of Veterinary Medicine, University of Ibadan, Ibadan.<sup>2</sup>Veterinary Teaching Hospital, University of Ibadan, Ibadan.<sup>3</sup>Department of Veterinary Microbiology and Parasitology, University of Ibadan, Ibadan.**\*Corresponding Author: Dr. Omobowale T.O.**

Department of Veterinary Medicine, University of Ibadan, Ibadan.

Article Received on 12/06/2017

Article Revised on 02/07/2017

Article Accepted on 22/07/2017

**INTRODUCTION**

Endocarditis has been defined as exudative and proliferative inflammatory alterations of the endocardium, characterized by the presence of vegetations on the surface of the endocardium or in the endocardium itself, and most commonly involving the heart valves, but also affecting the inner lining of the cardiac chambers or the endocardium elsewhere (Blood *et al.*, 2007). Bacterial endocarditis is an infection of the valvular and or mural endocardium and it may have both cardiac and extra-cardiac sequelae (Brown, 2004). The term, Bacterial Endocarditis (BE) has been replaced with Infectious Endocarditis (IE) since non bacterial isolates have been incriminated in its pathogenesis. BE refers to endocarditis that is caused by infection with various bacteria. Endocarditis (both the term and the disease) is pathophysiologically and epidemiologically unrelated to the most common form of chronic valvular heart disease in dogs known as endocardiosis (Bruce, 2002). Endocardiosis of which there is no specific etiology is characterized by chronic fibrosis and nodular thickening of the free edges of the atrioventricular valves (Blood *et al.*, 2007). IE is an infection of the valvular or mural endocardium with microbe, which may have both cardiac and extracardiac sequelae. (Valerie, 2004) It is a disease that commonly occurs in dogs. The mitral and aortic valves are the worst affected. Common causative microbial agents include *Staphylococcus spp*, *Streptococcus spp*, *Escherichia coli*, and *Bartonella spp*. Congestive heart failure, immune-mediated disease, and thromboembolism are the major complications of IE. Diagnosis of IE by echocardiography and long-term treatment with broad-spectrum antibiotics may contribute to the timely detection and treatment of the disease.

**EPIDEMIOLOGY**

The epidemiology of endocarditis in companion animals has not been extensively studied (Bruce, 2002). However, difficulty in diagnosis and underreporting of IE in dogs contribute to the reported low prevalence rate of the disease. This disease is relatively uncommon, occasionally observed in dogs but rarely in cats (Larry and John, 2001).

IE is one of the more significant of the endocardial alterations with increased occurrence in middle-aged, large-bred, male dogs are most often affected. Pure-bred dogs are more affected (Maark, 2013).

**PATHOGENESIS AND PATHOPHYSIOLOGY**

Based on experimental studies, the following factors have been suggested to be important in the pathogenesis of IE (Larry and John, 2001).

1. Endocardial damage(which may result from valvular insufficiency, stenosis, or a stunting lesion)
2. Activation of clotting factors
3. Bacteremia and colonization of a noninfective thrombus

It is believed that endothelial damage must be present for infective endocarditis to develop. It is virtually impossible to induce endocarditis in experimental animals unless the valvular endocardium is first traumatized with a polyethylene catheter inserted into the right or left side of the heart (Garrison and Freedman, 1970). High velocity regurgitant vortices and jets from turbulent blood flow may mechanically damage the endocardium (Woodfield and Sisson, 1989; Kasari and Roussel, 1989). The resultant exposure of underlying collagen activates platelet aggregation and the coagulation cascade, and formation of platelet-fibrin matrix. Deposition of fibrin and platelets, is a part of the normal healing process which forms a non-infective thrombus (Yok-Ai and Philippe, 2011). The development of such noninfectious thrombus is the first step in the establishment of infectious endocarditis. Episodes of bacteremia can result in the colonization process that result in infection of the thrombus and the initiation of the process that results in distortion and destruction of the valve leaflets and their associated structures (Larry and John, 2001). The valve colonizing organisms may originate from disrupted oral, gastrointestinal, or urogenital mucosal surfaces, or from any other localized

source of infection (Calvert, 1982; Anderson and Dubielzig, 1984). The manner by which bacteria localize on a valve is not completely clear. The production extracellular polysaccharides, such as dextrans by some bacteria, has been shown to be important in their adherence to the constituents of non-bacterial thrombotic endocarditis and may play a role in the pathogenesis of bacterial endocarditis (Michael *et al.*, 1977; Anderson, 1984; Kasari and Roussel, 1989). Also, the contribution of gelatinase to the pathogenesis of endocarditis caused by *Enterococcus faecalis* in rabbit models have been shown (Lance *et al.*, 2010). Subacute and chronic bacteremia often followed integumentary infections such as abscesses, cellulitis, and infected wounds and was usually the result of gram-positive microbes. Peracute and acute bacteremia was associated with internal infections and was usually the result of *E. coli*. (Calvert *et al.*, 1985).

### BACTERIAL ISOLATES

The most common isolates include *Staphylococcus aureus*, *Escherichia coli*,  $\beta$ -hemolytic streptococci, *Corynebacterium* spp., *Pseudomonas aeruginosa*, and *Erysipelothrix rhusiopathiae* (Calvert, 1982; O'Grady, 2000). It has been speculated that these organisms may originate from disrupted oral, gastrointestinal or urogenital mucosal surfaces or from other sources of infection (Calvert, 1982, Anderson and Dubielzig, 1984). The primary difference between the types of organisms isolated in humans and dogs with infective endocarditis is that dogs have a higher incidence of gram negative infections. In four studies, *Staphylococcus aureus* accounted for approximately 25% of the organisms isolated, hemolytic and non hemolytic *Streptococci* for 20% and *Escherichia coli* for 25%. *Corynebacterium* was isolated in 10% and *Pseudomonas* in 6%. *Erysipelothrix sp.* accounted for 3% of the cases (Mark, 2013). This unusual organism has been reported elsewhere and has recently been determined to be *E. tonsillarum*, not *E. rhusiopathiae*, the swine pathogen. *Bartonella vinsonii*, a rickettsial organism, has been reported in dogs with culture negative vegetative endocarditis. PCR-restriction fragment length polymorphism, sequence and phylogenetic analyses have identified *Bartonella rochalimae* involvement in endocarditis in dogs (Jennifer, 2009). A novel *Bartonella* species, *Bartonella vinsonii* subsp. *berkoffii* subsp. nov which can induce endocarditis in dogs, was reported by Edward *et al.* (1995) using PCR DNA amplification, DNA hybridization and sequencing. Similar techniques were also used by Patrick *et al.* (2006) to identify *Bartonella Quintana* as an isolate also associated with endocarditis in dogs. Nosocomial cases involving *Pseudomonas sp.*, *Proteus sp.*, or other unusual (and often highly antibiotic resistant) isolates as well as anaerobic bacteria (e.g., *Bacteroides sp.*) also occasionally cause infective endocarditis (Dow, 1988).

### NON BACTERIA ISOLATES

*Candida albicans*, is associated with endocarditis in IV drug users and immunocompromised patients (Badley *et al.*, 2008). *Histoplasma capsulatum* and *Aspergillus* are other fungi demonstrated to cause endocarditis (Lamas and Eykyn, 2003). Endocarditis with *Tricosporon asahii* has also been reported in a case report (Izumi *et al.*, 2009).

### PREDISPOSING FACTORS

Predisposing factors for canine infective endocarditis include congenital aortic valve disease and probably other congenital heart diseases that cause disturbances of blood flow and subsequent changes in the endocardium (Bruce, 2002). Prior valvular endocardial damage is one of the most significant factors increasing the chances of endocardial infection (Anderson, 1984). Dogs with congenital heart abnormalities are at a higher risk of developing valvular BE, because altered blood flow favors endocardial trauma (Kasari and Roussel, 1989). Approximately 25% of dogs with BE have some form of congenital heart disease (Calvert, 1982; Kasari and Roussel, 1989). Still, many dogs with valvular BE have no prior history of valvular disease or congenital heart defect (Calvert, 1982). In these cases, BE may be caused by bacteria, such as *S. aureus* or  $\beta$ -hemolytic streptococci, that produce -proteases that damage endothelial surfaces, subsequently exposing the subendothelial matrix (Sisson and Thomas, 1986). Corticosteroid administration has also been known to be a very common predisposing factor. It may be that the immunosuppressive effect of such drugs encourages bacteremia that preludes infective endocarditis. Infection with potentially immunosuppressive organisms (e.g., *Bartonella sp.*, *Ehrlichia sp.*) appears to enhance the risk of endocarditis in dogs. (Bruce, 2002).

Many cases of endocarditis appear to have a nosocomial origin. Infected intravenous catheters, prosthetic heart valves, openheart surgery and interventional cardiac catheterization (e.g., aortic balloon valvuloplasty) all appear to enhance the risk of endocarditis in dogs. There is actually little evidence that periodontal disease is a frequent source of infective endocarditis in dogs. This is in contrast to humans. Other predisposing factors for endocarditis in dogs include other chronic sources of bacteremia (e.g., urinary tract infection, diskospondylitis) or systemic illness that facilitates bacterial infection (e.g., diabetes mellitus, Cushing's disease). (Bruce, 2002). Interestingly, chronic valvular heart disease (endocardiosis) does not appear to predispose to infective endocarditis.

### CLINICAL PRESENTATION

Clinical signs observed in cases of bacterial endocarditis are not limited to cardiac disease and such may result from sepsis, septic embolization and immune mediated complications. Clinical signs associated with septic embolization may vary depending on the location of the embolization, the degree of vascular obstruction and the

degree of collateral circulation remaining (O'Grady, 2000). In the dog, the kidney and the spleen are the commonest sites of embolization (Anderson and Dubielzig, 1984, O'Grady, 2000). With a prolonged course of the condition, deposition of immune complexes in the glomeruli and synoviae of joints may occur (Brown, 2004).

Owners commonly present Patients because they appear ill systemically. Weakness, depression, anorexia (or inappetence) and weight loss are common presenting signs (Mark, 2013). Other dogs have signs of left heart failure. The owners often note respiratory abnormalities (tachypnea, dyspnea, cough) in this situation. Concomitant discospondylitis is a common problem (Mark, 2013).

Infective endocarditis can produce a wide spectrum of clinical signs, including primary cardiovascular effects or signs related to the nervous system, GI tract, urogenital system, or joints. This is because infected thrombi released from the infected aortic or mitral valves enter the circulation and can embolize other organs and limbs (Cynthia *et al.*, 2010). A chronic, intermittent or continuous fever is usually present.

Arrhythmia or sudden death may be caused by very small emboli which may take the first exit that, off the aorta and so travel down a coronary artery, creating a small, septic myocardial infarct (Mark, 2013). Slightly larger emboli may take the brachiocephalic trunk travel through the right subclavian artery and lodge in the right front leg. This causes a right front leg lameness (Mark, 2013). Lameness is a common clinical sign in dogs with IE (Cynthia *et al.*, 2010). Two types of arthritis have been described in dogs with IE (Mark, 2013). One is septic arthritis, presumably secondary to bacteremia or embolization. The other is a sterile arthritis, thought to be due to immune complex deposition that occur secondary to the bacterial antigenemia. The lameness may be stable or shift from leg to leg.

Acute to subacute mitral or aortic valve regurgitation can result in left heart failure (ie, pulmonary edema) and clinical signs of tachypnea, dyspnea, and cough. If the tricuspid valve is affected, ascites and jugular pulsations may be present. (Cynthia *et al.*, 2010).

A cardiac murmur is a common finding (Cynthia *et al.*, 2010). Discovering a new heart murmur in a patient that is febrile is the classic finding to make one suspicious of IE. Of course, most clinicians realize that classic findings usually do not occur in most cases (Mark, 2013). A systolic heart murmur is the most common (Mark, 2013). The murmur associated with mitral valve endocarditis is that of mitral regurgitation. If the murmur is grade III or louder and can be documented to be new and the patient is febrile, IE must be a primary differential diagnosis. Being certain that a systolic heart murmur has only occurred recently, however, is often difficult (Mark,

2013). A loud heart murmur in a young dog with a fever examined previously by a veterinarian, however, should be considered a new murmur until proven otherwise. A loud systolic murmur in a small breed, geriatric dog (even one with a fever) is most commonly due to myxomatous mitral valve degeneration, not to IE (Mark, 2013). A soft systolic murmur in large dog can also be due to IE but can also occur with numerous other cardiovascular lesions or increased stroke volume secondary to fever.

In dogs with aortic valve endocarditis, a diastolic heart murmur (which is difficult to identify) due to aortic regurgitation is commonly present (Mark, 2013). The murmur is heard with maximal intensity over the left cardiac base (Cynthia *et al.*, 2010). It is blowing in character. It starts immediately after the second heart sound and decreases in intensity through diastole. Infective endocarditis is by far the most common cause of an audible diastolic heart murmur secondary to aortic regurgitation in the dog and cat (Mark, 2013).

A soft systolic heart murmur caused by increased stroke volume may also be observed. In this situation, a bounding arterial pulse is noted due to increased pulse pressure caused by diastolic run-off and increased stroke volume (Cynthia *et al.*, 2010).

Lesions of bacterial endocarditis are usually located in those areas where high pressure and velocity gradients exist such as are found in both the mitral and aortic valves (Brown, 2004). One of the most significant factors for the development of endocardial infection is a prior valvular damage (Anderson and Dubielzig, 1984, Kasari and Roussel, 1989). High velocity regurgitant vortices and jets of blood from turbulent blood flow may damage the endocardium mechanically (Kasari and Roussel, 1989, Woodfield and Sisson, 1989). The resultant exposure of sub-endothelial collagen activates the aggregation of platelets and the cascade of events that are involved in coagulation and bacteria are able to adhere to the platelet fibrin matrix (Brown, 2004). Animals that have a congenital cardiac defect are more likely to develop bacterial endocarditis because altered blood flow favours endocardial trauma (Kasari and Roussel, 1989). It has been reported that about 25% of dogs with bacterial endocarditis have some form of congenital heart disease (Calvert, 1982, Kasari and Roussel, 1989). However, bacteria like *Staphylococcus aureus* and  $\beta$ -haemolytic streptococci which produce proteases that are capable of damaging endothelial surfaces and subsequently exposing the subendothelial matrix (Sisson and Thomas, 1986). Once bacterial endocarditis has been established, resolution is difficult because the bacterial colonies become tightly enmeshed in an avascular network of platelets and fibrin that host humoral factors and blood phagocytes cannot traverse (Brown, 2004). The rate of propagation of the vegetative lesion varies with the virulence of the infecting organism. Highly virulent organisms cause rapid necrosis

of the valvular stroma and may even perforate the valve (Woodfield and Sisson, 1989). Conversely, organisms of lower virulence damage the valvular stroma to a lesser degree and produce a slowly enlarging vegetative lesion that evolves over weeks to months (Kittleston and Kienle, 1998). Hyalinization or calcification of the vegetative lesion may be observed in older lesions (Kasari and Roussel, 1989, Woodfield and Sisson, 1989). There could be perforation, tearing or valvular leaflet distortion due to vegetative lesions which alter valvular leaflet coaptation and cause valvular insufficiency. If the regurgitant blood flow is small and develops slowly, the heart can adapt through compensatory measures. If severe regurgitation is however present, the heart cannot compensate and congestive heart failure develops (Brown, 2004).

### TREATMENT

The goal of therapy is to control clinical signs of congestive heart failure, resolve any significant arrhythmias, sterilize the lesion, and eliminate the spread of infection. (Cynthia *et al.*, 2010) Ideally, the choice of antibiotic therapy should be based on culture of the offending organism from blood and on identifying an antibiotic to which the organism is sensitive. Before antibiotic therapy is instituted, blood culture should be carried out on every patient suspected of having IE (Mark, 2013). Parenteral antibiotics are indicated initially for 1–2 wk. This uneconomical start is followed by oral antibiotics for at least 6–8 wk. (Cynthia *et al.*, 2010) Initial broad-spectrum bactericidal antibiotics (a combination of ampicillin plus gentamicin or enrofloxacin, or cephalothin plus gentamicin) should be used and changed, if antibiotic sensitivity studies indicate. (Cynthia *et al.*, 2010) Renal function should be monitored when gentamicin is used because it is nephrotoxic. Antibiotics selected to treat a patient with IE must be bactericidal because bacteria are growing slowly within the vegetations and the vegetations prevent leukocytes from phagocytizing cells. Consequently, a bacteriostatic agent will not successfully sterilize the vegetation (Mark, 2013). Antibiotic prophylaxis is indicated in dogs with subaortic stenosis when any type of procedure that can result in significant bacteremia is performed (Cynthia *et al.*, 2010). Routine dental prophylaxis is not warranted with other types of cardiac disease and especially not in dogs with myxomatous mitral valve degeneration; because there is no evidence that these dogs are at increased risk of infective endocarditis (Cynthia *et al.*, 2010).

Dogs that respond to antibiotic therapy often require long term cardiac medications for heart failure and frequent reevaluations (Cynthia *et al.*, 2010). The choice of cardioactive agents is guided by radiographic and echocardiographic findings (Larry and John, 2001). Controlling heart failure often requires the use of diuretics such as furosemide, an ACE inhibitor and when myocardial failure is present, pimobendan (Cynthia *et al.*, 2010). In addition, a more potent arteriolar dilator,

such as hydralazine, can be very beneficial in a patient that has acute, severe pulmonary edema or that is refractory to the other drugs (Mark, 2013). Hydralazine reduces peripheral vascular resistance and so reduces the amount of regurgitation in both aortic and mitral regurgitation (Mark, 2013). This results in decreased diastolic intracardiac pressures and a rapid reduction in pulmonary edema formation (Mark, 2013). Care must be taken not to produce profound hypotension when administering hydralazine along with an angiotensin converting enzyme inhibitor. This complication can be prevented by monitoring.

Corticosteroid administration is contraindicated IE patients (Mark, 2013). Its use may result in exacerbations of the clinical signs and worsening of the prognosis (Mark, 2013). Moreover, Patients with occult IE will usually develop clinical signs rapidly following corticosteroid administration (Mark, 2013).

### PROGNOSIS

The prognosis for dogs with active IE is poor. By the time of diagnosis, most cases of IE have reached such an extent that there is irreversible damage to the valve (Larry and John, 2001). In one study, of 45 dogs proven to have IE either by fulfillment of clinical diagnostic criteria or by necropsy, only 20% survived (Mark, 2013). Congestive heart failure, common sequelae of IE, may be severe and intractable if the aortic valve is significantly involved; the prognosis is grave in these cases (Cynthia *et al.*, 2010). The prognosis is much more favorable when infection is mild and limited to one of the AV valves (Cynthia *et al.*, 2010).

Severe left heart failure commonly develops in dogs with large aortic valve lesions which is fatal (Mark, 2013). Dogs with severe mitral valve endocarditis may follow a similar course but generally have a better prognosis, depending on the severity of regurgitation. (Mark, 2013). No definitive treatment for valve destruction such as prosthetic valve replacement exists in veterinary medicine. Consequently, once severe regurgitation is produced heart failure and death are ultimately the expected result (Mark, 2013).

Renal infarction and failure are embolic complications that may result in death of IE patients (Mark, 2013).

### DIAGNOSIS

Clinical signs and abnormal heart sounds may help to suggest IE. A Complete Blood Count often shows a neutrophilic leukocytosis (Cynthia *et al.*, 2010). Active infection may be associated with the presence of band neutrophils, and upto 90% chronic infection with a monocytosis (Cynthia *et al.*, 2010). Anemia of chronic disease is frequently present (Cynthia *et al.*, 2010). Serum analysis may reveal abnormalities reflecting organ involvement secondary to infective emboli and may include increases in liver enzymes, BUN, and creatinine. In animals that develop immune complex

glomerulonephritis, significant urinary protein loss and hypoalbuminemia may develop (Cynthia *et al.*, 2010).

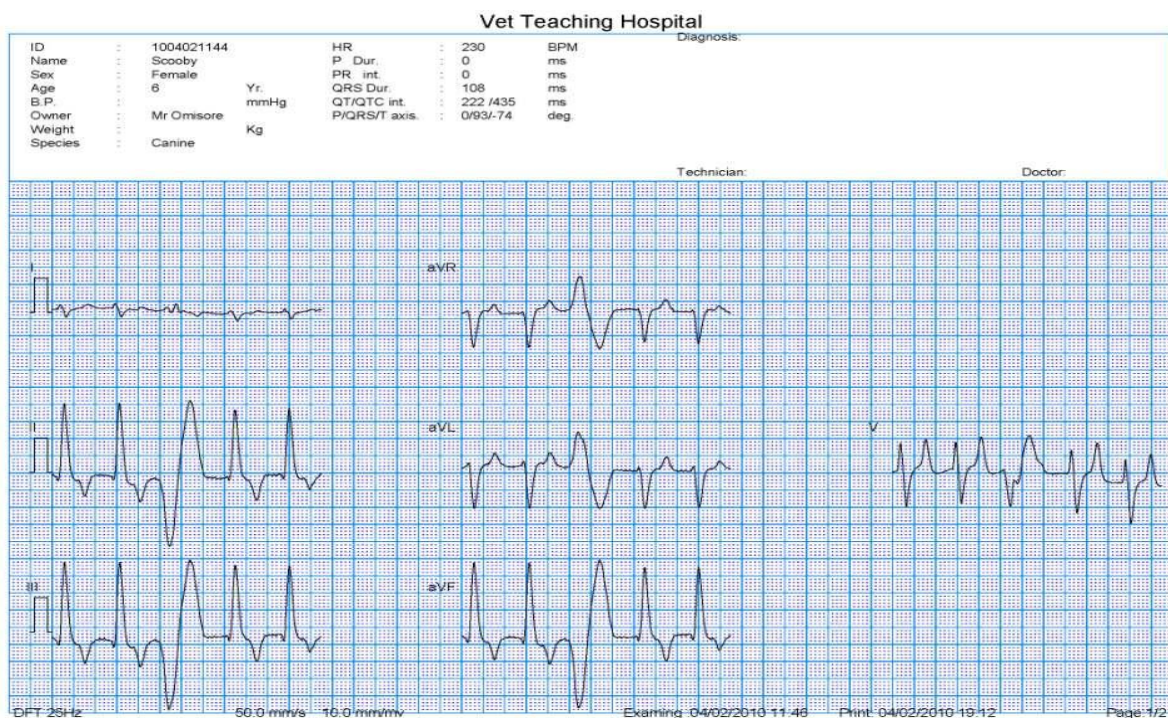
Blood cultures must be obtained to try to identify the offending organism and subsequently to identify the appropriate antibiotic in patients with IE. Critically ill animals frequently develop sepsis and have positive blood culture results. Dogs with discospondylitis can have clinical signs that closely mimic IE (Mark, 2013). To increase the chance of successful identification of bacteremia through the use of blood cultures in a patient with IE, more than one blood culture should always be taken (Mark, 2013). Preferably the patient should not be on antibiotic therapy at the time of culture but positive blood cultures can still be obtained and so antibiotic therapy is not an absolute contraindication (Mark, 2013). It is preferable to draw 2 or 3 blood samples, each 1–2 hr apart, in a 24-hr period (Cynthia *et al.*, 2010). If the patient has already been administered antibiotics, three more cultures can be taken over the following week. Strict aseptic blood collection procedures should be followed (Cynthia *et al.*, 2010). Blood cultures are never used definitively to make a diagnosis of IE due to lack of specificity as blood cultures are also positive in other diseases. In one study, of 165 dogs with positive blood cultures, only 45 were diagnosed as having IE (Mark, 2013). Cultures should be incubated for at least three weeks and Gram stains should be made at intervals, even if no growth is apparent (Mark, 2013).

Radiographic findings in IE are variable (Larry and John, 2001). Radiography may demonstrate cardiac chamber enlargement, depending on the location and degree of insufficiency of the involved valve (Cynthia *et al.*, 2010). If the aortic or mitral valve is severely affected, there will be left atrial and left ventricular chamber dilatation

(Cynthia *et al.*, 2010). Evidence of left heart failure may be seen as an increase in interstitial density or, in severe Congestive heart failure, an alveolar pattern in the pulmonary parenchyma. If the tricuspid or pulmonic valve is affected, right-sided chamber enlargement is expected (Cynthia *et al.*, 2010).

Echocardiography is the diagnostic test of choice because findings using this technique are distinctive (Larry and John, 2001). It is however not 100% sensitive or specific (Mark, 2013). Besides identifying vegetations, dogs with destructive lesions of their valves but without vegetations can be diagnosed with IE based on the presence of a regurgitant lesion and the echocardiographic appearance of the valve, especially when the aortic valve is involved (Mark, 2013). The affected valve is usually easily detected—the involved area is hyperechoic (bright), thickened, and often vegetative (ie, looks like a cauliflower). Erosive lesions may predominate in some animals (Cynthia *et al.*, 2010). Doppler echocardiography will confirm insufficiency of the valve, and chamber enlargement on the side of the affected valve is expected when significant insufficiency is present (Cynthia *et al.*, 2010).

Electrocardiographic findings in IE are not diagnostic (Larry and John, 2001). Electrocardiography may demonstrate atrial and ventricular premature complexes (Cynthia *et al.*, 2010). Ventricular tachyarrhythmias, including ventricular tachycardia, are relatively common, and supraventricular tachyarrhythmias including atrial fibrillation, are also observed (Larry and John, 2001). The height of the R wave may be increased (suggestive of left ventricular enlargement) and the width of the P wave increased (suggestive of left atrial enlargement) (Cynthia *et al.*, 2010).



## REFERENCES

- Anderson CA, Dubielzig RR (1984). Vegetative endocarditis in dogs. *J Am Anim Hosp Assoc*: 20: 149–152.
- Anderson CA, Dubielzig RR. Vegetative endocarditis in dogs. *J Am Anim Hosp Assoc*, 1984; 20: 149–152.
- Baddley JW, DK Benjamin Jr., M Patel, J Miró, E Athan, B Barsic, E Bouza, L Clara, T Elliott, Z Kanafani, J Klein, S Lerakis, D Levine, D Spelman, E Rubinstein, P Tornos, AJ Morris, P Pappas, VG Fowler Jr, VH Chu, and C Cabell. *Candida* Infective Endocarditis: *Eur J Clin Microbiol Infect Dis*. 2008 July; 27(7): 519–529. Published online 2008 February 19. doi: 10.1007/s10096-008-0466-x.
- Blood D.C, Studdert V.P, Gay C.C (Editors). *Sounders comprehensive veterinary dictionary*, Third edition: Elsevier ltd, 2007. ISBN-13:978-0-7020-2788-8.
- Brown, V.A. (2004) Aortic valvular endocarditis in a dog. *Can. Vet. J.* 45: 682–684.
- Bruce W.Keene,: The 26<sup>th</sup> Annual WALTHAM diets/OSU symposium. Small animal cardiology, Ohio state university. Waltham USA, Inc, 2002.
- Calvert CA (1982). Valvular bacterial endocarditis in the dog. *J Am Vet Med Assoc*: 180: 1080–1084.
- Calvert CA, Greene CE, Hardie EM. Cardiovascular infections in dogs: epizootiology, clinical manifestations and prognosis. *J Am Vet Med Assoc*. 1985 Sep 15; 187(6): 612-6.
- Calvert CA. Valvular bacterial endocarditis in the dog. *J Am Vet Med Assoc* 1982; 180: 1080–1084.
- Cynthia M. Kahn (Editor):THE MERCK VETERINARY MANUAL 10<sup>th</sup> ED: MERCK&CO., INC. whitehouse station, NJ., USA, 2010. Pp109-111.
- Dow SW, LeCouteur RA, Henik RA, et al: Central nervous system infection associated with anaerobic bacteria in two dogs and two cats. *J Vet Intern Med*, 1988 Oct-Dec; 2(4): 171-6.
- Edward B. Breitschwerdt, Dorsey L. Kordick, David E. Malarkey, Bruce Keene, Ted L. Hadfield, And Kenneth: Endocarditis in a Dog Due to Infection with a Novel *Bartonella* Subspecies: Wilson.J. Clin. Microbiol, Jan. 1995; p. 154–160 Vol. 33, No. 1 0095-1137.
- Garrison PK, Freedman LR. Experimental endocarditis I. Staphylococcal endocarditis in rabbits resulting from placement of a polyethylene catheter in the right side of the heart. *Yale J Biol Med*, 1970; 42: 394.
- [http://www.bearscompnews.com/health/Waltham%20Center/Infective%20Endocarditis.pdf\(walthman\)](http://www.bearscompnews.com/health/Waltham%20Center/Infective%20Endocarditis.pdf(walthman))
- Izumi K, Hisata Y, Hazama S. 2009. "A rare case of infective endocarditis complicated by *Trichosporon asahii* fungemia treated by surgery". *Annals of Thoracic and Cardiovascular Surgery*, 15(5): 350–353. PMID 19901894.
- Jennifer B. Henn, Mourad W. Gabriel, Rickie W. Kasten, Richard N. Brown, Jane E. Koehler, Kristin A. MacDonald, Mark D. Kittleson, William P. Thomas and Bruno B. Chomel Infective Endocarditis in a Dog and the Phylogenetic Relationship of the Associated "*Bartonella rochalimae*" Strain with Isolates from Dogs, Gray Foxes and a Human\_: *J. Clin. Microbiol.*, Mar. 2009; 47(3): 787–790 0095-1137/09/\$08.00\_0 doi:10.1128/JCM.01351-08.
- Kasari TR, Roussel A (1989). J. Bacterial endocarditis. Part I. Pathophysiologic, diagnostic, and therapeutic considerations. *Compend Contin Educ Pract Vet*: 11: 655–671.
- Kasari TR, Roussel AJ. Bacterial endocarditis. Part I. Pathophysiologic, diagnostic and therapeutic considerations. *Compend Contin Educ Pract Vet*, 1989; 11: 655–671.
- Kittleson MD, Kienle RD (1998). *Small Animal Cardiovascular Medicine*. 1st ed. St. Louis: Mosby: 298–299, 402.
- Lamas, CC; Eykyn, SJ (March 2003). "Blood culture negative endocarditis: analysis of 63 cases presenting over 25 years". *Heart*, 89(3): 258–262. doi:10.1136/heart.89.3.258. PMC 1767579. PMID 12591823.
- Lance R. Thurlow, Vinai Chittezhom Thomas, Sanjeev Narayanan, Sally Olson, Sherry D. Fleming, and Lynn E. Hancock. Gelatinase Contributes to the Pathogenesis of Endocarditis Caused by *Enterococcus faecalis*; *Infect Immun*. 2010; 78(11): 4936–4943.
- Larry P.T, John-K G, 2001. Editors: Manual of canine and feline cardiology, Third Ed. W.B Sounders Company. ISBN 0-7216-7721-5;pg 129-136
- Mark D. Kittleson, Infective Endocarditis:Text from "Small Animal Cardiovascular Medicine" available at [www.vmeth.ucdavis.edu](http://www.vmeth.ucdavis.edu) Accessed March, 29, 2013.
- Michael Scheld W., James A. V'Alone and Merle A. Sande, Bacterial Adherence in the Pathogenesis of Endocarditis: interaction of bacterial dextran, platelets, and fibrin *J. Clin. Invest.* X). The American Society for Clinical Investigation, Inc., 0021 9738/78.1977;0501-1394.
- Michael W. Scheld, James A. V'Alone, and Merle A. Sande. Bacterial Adherence in the Pathogenesis of Endocarditis: Interaction of bacterial dextran, platelets and fibrin. *J. Clin. Invest.*, The American Society for Clinical Investigation, Inc., 0021-9738/78/1394-1404.
- O'Grady MR (2000). Acquired valvular heart disease. In: Ettinger SJ, Feldman EC, eds. *Textbook of Veterinary Internal Medicine: Diseases of the Dog and Cat*. 5<sup>th</sup> ed. vol 1. Philadelphia:WB Saunders:944–959.
- O'Grady MR. Acquired valvular heart disease. In: Ettinger SJ, Feldman EC, eds. *Textbook of Veterinary Internal Medicine: Diseases of the Dog and Cat*. 5<sup>th</sup> ed. vol 1. Philadelphia: WB Saunders, 2000; 944–959.

28. Patrick Kelly, Jean-Marc Rolain, Ricardo Maggi, Sushama Sontakke, Bruce Keene, Stuart Hunter, Hubert Lepidi, Kyle T. Breitschwerdt, Edward B. Breitschwerdt, and Didier Raoult: *Bartonella quintana* Endocarditis in Dogs Emerging Infectious Diseases • www.cdc.gov/eid • Vol. 12, No. 12, December 2006.
29. Sisson D, Thomas WP (1986). Bacterial endocarditis. In: Kirk RW, ed. Current Veterinary Therapy IX. Small Animal Practice. Philadelphia: WB Saunders,; 402–406.
30. Sisson D, Thomas WP. Bacterial endocarditis. In: Kirk RW, ed. Current Veterinary Therapy IX. Small Animal Practice. Philadelphia: WB Saunders, 1986; 402–406.
31. Valerie A. Brown: Can Vet J. 2004 August; 45(8): 682–684 PMID: PMC546447.
32. Woodfield JA, Sisson D (1989). Infective endocarditis. In: Ettinger SJ, ed. Textbook of Veterinary Internal Medicine. Diseases of the Dog and Cat. 3rd ed. vol 1. Philadelphia: WB Saunders: 1151–1162.6.
33. Woodfield JA, Sisson D. Infective endocarditis. In: Ettinger SJ, ed. Textbook of Veterinary Internal Medicine. Diseases of the Dog and Cat. 3<sup>rd</sup> ed. vol 1. Philadelphia: WB Saunders, 1989; 1151–1162.
34. Yok-Ai Que, Philippe Moreillon; Nat Rev Cardiol. 2011; 8(6): 1-15. 2011.