



RENAL PELVIS REDUCTION DURING DISMEMBERED PYELOPLASTY FOR CONGENITAL URETERO-PELVIC JUNCTION OBSTRUCTION: IS IT BENEFICIAL?

Mohammad Daboos¹ and Tarek Abdallah Salem*²

¹Urology Department, Faculty of Medicine, Al-Azhar University, Cairo, Egypt.

²Pediatric Surgery Department, Faculty of Medicine, Al-Azhar University, Cairo, Egypt.

*Corresponding Author: Tarek Abdallah Salem

Pediatric Surgery Department, Faculty of Medicine, Al-Azhar University, Cairo, Egypt.

Article Received on 20/10/2016

Article Revised on 10/11/2016

Article Accepted on 30/11/2016

ABSTRACT

Objectives: To assess the beneficial effect of renal pelvis reduction during dismembered pyeloplasty for congenital ureteropelvic junction (UPJ) obstruction in pediatrics as regard functional and the surgical outcome. **Patients and Methods:** in a prospective manner, over a two years period, 20 children with congenital UPJ obstruction were studied. Pre-operatively, all patients were evaluated by medical history taking, physical examination, routine laboratory investigations, abdominal ultrasonography and diuretic renography. Patients were randomly allocated into 2 treatment groups: group A (10 patients), in which the patients underwent open dismembered pyeloplasty with renal pelvis reduction and group B (10 patients) in which the patients underwent open dismembered pyeloplasty without renal pelvis reduction. Post-operatively, the patients were followed-up regularly after 1, 3 and 6 months. Abdominal ultrasonography was performed at each follow-up visit and diuretic renography scanning only at the end of study. The changes in the renal pelvis diameters and split renal function were assessed and compared between both groups. **Results:** The study included 20 patients ranged in age from 3 to 36 months (mean: 18.40±6.26). Twelve patients were asymptomatic and diagnosed on routine antenatal ultrasonography evaluation and 8 patients presented by abdominal mass. The mean values of pre-operative parameters including age at operation, renal pelvis diameter, and split renal function were comparable in both groups. There were high significant decrease in the anterior-posterior diameter of renal pelvis and improvement of split renal function when comparing the pre-operative and post-operative values in each group (P<0.001). However, no significant differences were observed between both groups during all follow-up time points (P>0.05). **Conclusions:** The study results showed that, the renal pelvis reduction during open dismembered pyeloplasty has no beneficial effect over pyeloplasty without pelvis reduction technique in pediatric congenital UPJ obstruction, regarding the change in the renal pelvis diameter and split renal function.

KEYWORDS: Dismembered pyeloplasty, Renal pelvis reduction, Split renal function Uretero-pelvic junction obstruction.

INTRODUCTION

Ureteropelvic junction (UPJ) obstruction is by far the most common cause of pediatric hydronephrosis, occurring in 1 per 1,000-2,000 newborns. Widespread use of prenatal ultrasonography and the advent of modern imaging techniques have resulted in earlier and more common diagnosis of hydronephrosis.^[1] With the advent of prenatal fetal ultrasonography, most infants born with UPJ obstruction are detected prenatally. Postnatally, some infants are asymptomatic and others may present with failure to thrive, renal mass, vomiting, sepsis secondary to urinary tract infection or hematuria.^[2]

In patients with ultrasonographic evidence of UPJ obstruction diuretic radionuclide renography is typically the next study performed to evaluate differential renal function and drainage, through an assessment of washout

from the individual kidney. In infants this study is best obtained after the age of 6 weeks when the glomerular filtration rate is sufficient to allow accurate functional measurements.^[3]

Various surgical techniques, open and minimally invasive, have been used for correction of UPJ obstruction.^[4] Evolution in the surgical correction of UPJ obstruction has occurred on a number of fronts, with open surgical techniques yielding way to endoscopic and laparoscopic approaches. The open techniques that have had the greatest applicability can be classified into three main groups: the flap type, the incisional intubated type, the dismembered type. The Anderson-Hynes dismembered pyeloplasty has become the most commonly employed "open" surgical procedure for the repair of UPJ obstruction.^[5] With a success rate of about

94%, the Anderson-Hynes dismembered pyeloplasty is the gold standard for the repair of UPJ obstruction.^[6] Although the original technique describes surgical reduction in the size of the renal pelvis, it was in the late 1990s that this practice became popular. This was era when many studies demonstrated histological changes in the renal pelvis together with problem at the ureteropelvic junction.^[7] Thus, removal of abnormal pelvis and UPJ together was advocated. Other possible benefits of excision of renal pelvis are to prevent urine stasis behind a newly created anastomosis and to avoid ureteral kinking. With the increasing popularity of laparoscopic dismembered pyeloplasty, the need for the renal pelvis reduction was re-evaluated, as most of the interventions using this technique were done without this reduction. Many surgeons believe that the redundant renal pelvis is protective, and removing it may deprive the kidney from its benefit at time when it may need it. Also, unnecessary surgery might lead to problems such as leakage or long hospitalization. Limited data are available concerning the effects of renal pelvis reduction on surgical outcome.^[8]

In the present study we evaluated the beneficial effect of renal pelvis reduction during dismembered pyeloplasty for pediatric UPJ obstruction as regard the surgical and functional outcome.

PATIENTS AND METHODS

Over a two years period (from December 2013 to December 2015), 20 patients (18 boys, 2 girls) with congenital UPJ obstruction were studied. All patients were evaluated by detailed history taking, physical examination, urinalysis, blood urea and serum creatinine measurement, abdominal ultrasonography and diuretic renography. Cystourethrogram was done in selected cases to exclude vesico-ureteral reflux. Only patients with confirmed UPJ obstruction with pelvic antero-posterior diameter >30mm (the transverse plane as measured by ultrasound scan) and renal function < 40% were included. Patients with ureteral dilatation, double system hydronephrosis (duplex kidney), aberrant renal vessels, recurrent UPJ obstruction were excluded. According to the operative technique, patients were randomly divided into two groups. Group A (10 patients), underwent open dismembered pyeloplasty with renal pelvis reduction and Group B (10 patients) underwent open dismembered pyeloplasty without renal pelvis reduction.

Operative Technique

Under general and caudal anaesthesia, the patient was placed in the 45° flank position. Exposure to the UPJ was attained. The ureter was dissected cephalic toward the renal pelvis, preserving a large amount of periureteral tissue to ensure adequate ureteral blood supply, the UPJ was identified and the renal pelvis was dissected free of surrounding peripelvic tissue. In group A, reduction of the renal pelvis was done by excision of the dilated renal pelvis up to about (2cm) from the calyceal infundibula.

When the UPJ was excised the proximal ureter is spatulated on its lateral aspect. The apex of this lateral spatulated aspect of the ureter was brought to the inferior border of the pelvis while the medial side of the ureter was brought to the superior edge of the pelvis. The anastomosis was performed with 5/0 running absorbable sutures placed full thickness through the ureteral and renal pelvis wall in a watertight fashion. Then, an indwelling ureteral stent was leaved and nephrostomy catheter was inserted. The stent was removed 4 weeks after surgery. Nephrostomy catheter was removed in post-operative 14th day.

Follow-up

Abdominal ultrasonography was performed on the postoperative month 1, 3, and 6 and diuresis renography on postoperative month 6. The ultrasonography was done by a radiologist who was blinded to the surgical technique. Both groups were compared as regard to the complication rate, differential renal function and anterior-posterior pelvis diameter and the need for re-operation.

Statistical analysis

Data were statistically described in terms of the range, mean standard deviation (SD), median, frequency (number of cases) and percentages when appropriate. Comparison of quantitative variables between the study groups was done using the Mann Whitney U-test for continuous data. For comparing categorical data, the Chi square test was performed. An exact test was used instead when the expected frequency was less than 5. A probability value (p) less than 0.05 was considered statistically significant. All statistical calculations were done using the computer programs Microsoft Excel 2010 (Microsoft Corp., NY, and USA) and SPSS (Statistical Package for the Social Sciences; SPSS Inc., Chicago, IL, USA) version 15 for Microsoft Windows.

RESULTS

The included patients were 18 boys and 2 girls, ranged in age from 3 to 36 months (median: 16.36±8.18 years). Twelve patients were diagnosed antenatally and the remaining patients were presented by abdominal mass. Eighteen patients had unilateral UPJ obstruction and 2 patients had bilateral obstruction (one in each group). No significant differences were observed between both groups in term of age, and pre-operative renal pelvis diameter and differential renal function ($P > 0.05$) (Table 1).

Postoperatively, there was a highly significant decrease in the mean APPD, from the 1st month post-operative till the end of study, in both groups (Table 2). Despite the APPD was larger in group B at each follow-up time point, no significant differences were observed between the two groups till the end of study ($P = 0.463, 0.510$ and 0.172 at the 1st, 3rd and 6th month, respectively) (Figure 1).

The renal scan at 6th month post-operatively showed highly significant improvement of ipsilateral split renal function in both groups. However, no

significant differences were observed between the two groups in the improvement of renal function (Table 3).

Table 1: The pre-operative parameters in both groups.

	Min.	Max.	Mean	SD
Group A				
Age (month)	4	36	18.40	6.26
Pre-operative anterior-posterior pelvis diameter (mm)	42	50	45.20	3.12
Pre-operative differential renal function (%)	23	39	34.20	4.10
Group B				
Age (month)	2	24	10.00	6.86
Pre-operative anterior-posterior pelvis diameter (mm)	35	46	41.60	4.14
Pre-operative differential renal function (%)	26	37	32.80	4.08

Table 2: Comparison of pre-operative and post-operative anterior-posterior pelvis diameter in each groups.

Anterior-posterior pelvis diameter (mm)	Group A	Paired sample t-test	Group B	Paired sample t-test
Pre-operative (mean±SD)	45.20±3.12		41.60±4.14	
1 st month post-operative (mean±SD)	26.10±4.20	<0.001	27.60±4.72	<0.001
3 rd month post-operative (mean±SD)	15.72±1.83	<0.001	16.20±1.32	<0.001
6 th month post-operative (mean±SD)	9.82±1.60	<0.001	10.90±1.79	<0.001

Table 3: Comparison of pre-operative and post-operative split renal function in each group.

Split renal function (%)	Group A	Paired sample t-test	Group B	Paired sample t-test	Independent sample t-test
Pre-operative (mean±SD)	45.20±3.12		41.60±4.14		0.454
6 th month post-operative (mean±SD)	9.82±1.60	<0.001	10.90±1.79	<0.001	0.214

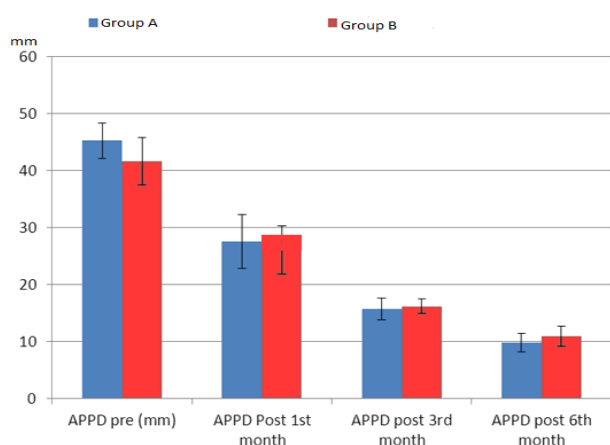


Figure 1: Comparison of the antero-posterior pelvis diameter between both groups, pre-operatively and at each follow-up time point (P>0.05).

DISCUSSION

UPJ obstruction can occur in children of all age groups, the majority of cases are detected in the perinatal period with the advent of modern imaging techniques. In a retrospective studies, functionally significant UPJ obstruction was noted in one in 1500 fetuses screened by antenatal ultrasonography. Boys were affected with UPJ obstruction more commonly than girls.^[9] In our study, 18 male and only 2 female were affected; 12 patients diagnosed antenatally and the remaining were presented by abdominal mass.

Congenital UPJ obstruction is usually caused by intrinsic stenosis of the proximal ureter as a result of an interruption in the development of the circular musculature of the UPJ or an alteration of collagen fibers between and around the muscle cells. Other causes of intrinsic PUJ obstruction include valvular mucosal folds, persistent fetal convolutions and upper ureteral polyps. In all cases in this study, the main pathology at UPJ was severe stenosis, excessive fibrosis, loss of musculature proved by histopathological examination of excised UPJ.^[10]

The surgical management of UPJ obstruction has undergone revolutionary changes over the past few years. In recent decades, resection surgical techniques in particular, that of Anderson-Hynes have gained acceptance. Common to all resection methods is removal of the dysplastic portion of the ureter followed by a microsurgical anastomosis to connect the renal pelvis and the ureter. The Anderson-Hynes technique is seen today as standard. It can be carried out both in open surgery and laparoscopically in older children.^[11,12]

Usually, resection of the dilated pelvis is recommended to avoid postoperative accumulation of urine or re-obstruction due to ureteral kinking. However, the relevance of extensive pelvic resection has not been investigated systematically.^[13] *Reismann et al.*^[14], reported that dismembered pyeloplasty doing without extensive resection avoids the need for extensive

retroperitoneal preparation and reduces the number of sutures, resulting in shorter operating times, especially in laparoscopic, but also in open procedures.

The main expectation from a successful pyeloplasty is to preserve or improve the split function. *In this study*, ultrasound scan and DTPA renography performed pre- and 6 months postoperatively did not show any significant difference between the two groups with regard to APPD and split renal function. Usually, resection of the dilated pelvis is recommended to avoid postoperative accumulation of urine or re-obstruction due to ureteral kinking.^[13] *Stein et al.*^[15], evaluated the role of pelvic reduction in a retrospective study. However, the main evaluation criterion was the intravenous pyelography. They did not detect any significant advantage of pelvic reduction in their study. *Reismann et al.*^[14] published findings supporting the previous study. They did not exhibit any benefit of pelvic reduction against pelvis-sparing including the split renal function.

The study done by *Burgu et al.*^[8] on 42 patients divided into reduction and non-reduction groups has also revealed no effect of pelvic reduction on differential renal function and APPD at the 6th postoperative month, although the APPD decreased significantly in the pelvic reduction group compared to the pelvis-sparing group on the 1st and 3rd month ultrasound scans. However, the difference was not significant in the 6th month. What this study brought to our approach is that excision of large portions of renal pelvis during pyeloplasty is not desirable. When the renal pelvis is not surgically reduced, it reduces spontaneously by 6 months.

Pelvic reduction during pyeloplasty will inevitably have some effect on the early postoperative results. In fact, it may take up to 3-5 months for the repaired UPJ to recover near normal peristalsis according to two experimental studies.^[16,17]

REFERENCES

1. Lee H, Han SW. Ureteropelvic Junction Obstruction: What We Know and What We Don't Know. *Korean Journal of Urology*, 2009; 50(5): 423-31.
2. Thomas DF. Upper tract obstruction. Quoted from David FM Thomas, Patrick G Duffy, Anthony MK Rickwood, (eds.), *Essentials of Paediatric Urology* 2nd Edition. London: informa health care, 2008; 6: 73-92.
3. Groth TW And Mitchell ME: Ureteropelvic Junction Obstruction, *Pediatric Surgery* 7th ed, Arlond G Coran, Elsevier, 2012; 113: 1411-25.
4. El-Ghoneimi A. Laparoscopic management of hydronephrosis in children. *World journal of urology*, 2004; 22(6): 415-7.
5. Wein AJ, Kavoussi L R, Novick AC, et al. Anomalies and surgery of Ureto-Pelvic Junction Obstruction in children, *Campell-Wallsh Urology*, 9th ed, Elsevier, section, 2007; 17(115): 3359-82.
6. Park J, Kim WS, Hong B, Park T, Park HK. Long-term outcome of secondary endopyelotomy after failed primary intervention for ureteropelvic junction obstruction. *International journal of urology*, 2008; 15(6): 490-4.
7. Kim DS, Noh JY, Jeong HJ, Kim MJ, Jeon HJ, Han SW. Elastin content of the renal pelvis and ureter determines post-pyeloplasty recovery. *The Journal of urology*, 2005; 173(3): 962-6.
8. Burgu B, Suer E, Aydogdu O, Soygur T. Pelvic reduction during pyeloplasty for antenatal hydronephrosis: does it affect outcome in ultrasound and nuclear scan postoperatively? *Urology*, 2010; 76(1): 169-74.
9. Senguttuvan P, Jigy J. Profile and outcome of pelviureteric junction obstruction. *The Open Urology & Nephrology Journal*, 2014; 7(1).
10. Bondagji NS. Antenatal diagnosis, prevalence and outcome of congenital anomalies of the kidney and urinary tract in Saudi Arabia. *Urology annals*, 2014; 6(1): 36.
11. León TG, Villalón EA, Marcillán MES, Olivé JB, García LRO, Castro JLH. Resultados de la pieloplastia laparoscópica en el Centro Nacional de Cirugía de Mínimo Acceso. *Revista Cubana de Urología*, 2014; 3(1): 27-37.
12. Piaggio LA, Franc-Guimond J, Noh PH, Wehry M, Figueroa TE, Barthold J, et al. Transperitoneal laparoscopic pyeloplasty for primary repair of ureteropelvic junction obstruction in infants and children: comparison with open surgery. *The Journal of urology*, 2007; 178(4): 1579-83.
13. Gupta M, Cha DY. Ureteropelvic Junction Obstruction. *Ureterscopy*: Springer, 2013; 41-53.
14. Reismann M, Gratz K, Metzelder M, Ure B, Glüer S. Excision of the dilated pelvis is not necessary in laparoscopic dismembered pyeloplasty. *European journal of pediatric surgery*, 2008; 18(01): 19-21.
15. Stein R, Ikoma F, Salge S, Miyanaga T, Mori Y. Pyeloplasty in hydronephrosis: examination of surgical results from a morphologic point of view. *International journal of urology*, 1996; 3(5): 348-55.
16. Rehman J, Ragab MM, Venkatesh R, Sundaram CP, Ali Khan S, Sukkarieh T, et al. Smooth-muscle regeneration after electrosurgical endopyelotomy in a porcine model as confirmed by electron microscopy. *Journal of endourology*, 2004; 18(10): 982-8.
17. Andreoni CR, Lin H-K, Olweny E, Landman J, Lee D, Bostwick D, et al. Comprehensive evaluation of ureteral healing after electrosurgical endopyelotomy in a porcine model: original report and review of the literature. *The Journal of urology*, 2004; 171(2): 859-69.