



**KSHARASUTRA APPLICATION IN PILONIDAL SINUS – A CASE STUDY**

**Dr. Yogeshwar Namdev Surnar\*<sup>1</sup> and Dr. Rashmi Anil Kale<sup>2</sup>**

<sup>1</sup>P.G. Scholar, Department of Shalyatanra, Sumitabhai Shah Ayurved Mahavidhalaya, Malwadi, Hadapsar, Pune.

<sup>2</sup>Guide and Associate Professor HOD of, Department of Shalyatanra, Sumitabhai Shah Ayurved Mahavidhalaya, Malwadi, Hadapsar, Pune, Maharashtra, India.

**\*Corresponding Author: Dr. Yogeshwar Namdev Surnar**

P.G. Scholar, Department of Shalyatanra, Sumitabhai Shah Ayurved Mahavidhalaya, Malwadi, Hadapsar, Pune.

Article Received on 01/09/2017

Article Revised on 22/09/2017

Article Accepted on 12/10/2017

**ABSTRACT**

Pilonidal sinus is a common disease of the natal cleft in the sacrococcygeal region with weak hair accumulation occurring in the hair follicles, which can be chronic and undergo acute exacerbation. The patient presents with the complaints, which are characteristics of inflammation—a painful swelling, redness, local temperature raised or with a sinus discharge. Prolong sitting, presence of deepnatal cleft, obesity, repeated irritation due to hair, family history may increase the risk of disease. In *Ayurvedic* science Pilonidal sinus is better correlated and treated as the *Nadi vrana*. *Acharya Sushruta* mentioned eight types of sinuses as *nadivarna*. Among these, pilonidal sinus can be considered under *shalyaj nadivarna* (sinus due to foreign body) and He had explained *Shastra Chikitsa* with the intervention of *kshar sutra* as one of the treatment for *Nadi vrana* (sinuses). A case of pilonidal sinus in 32y/m patient was thoroughly examined and treated with *ksharsutra* therapy. Tuft (bulk) of hairs were expelled out during procedure. *Ksharsutra* is ideal procedure to be adopted for the management of sinus track for not only it destroys the fibrous wall of track but also helps in its curettage. In this study elicits a case report of a pilonidal sinus treated by the intervention of *kshar sutra*, which cured and No recurrence or No any complain were found in the patient during follow up.

**KEYWORDS:** Pilonidal sinus, *kshar sutra*, *Nadi vrana*.

**INTRODUCTION**

Pilonidal means nest of hair & is derived from the Latin words for hair (*pilus*) and nest (*nidus*).<sup>[1]</sup> The condition was first described by Herbert Mayo in 1833.<sup>[2]</sup> R.M. Hodges was the first to use the phrase Pilonidal cyst to describe the condition in 1880.<sup>[3]</sup> The incidence of Pilonidal sinus is approximately 26 / 100,000,<sup>[4]</sup> it is a benign disease that occurs in young adults in the age group of 15-30 years after puberty when sex hormones are known to affect pilosebaceous glands & change healthy body hair growth.<sup>[5]</sup> A Pilonidal sinus is a cyst or abscess near or on the natal cleft of the buttocks that often contains hair & skin debris. A Pilonidal sinus is usually painful but without draining, the patient might not feel pain. The etiology and pathogenesis of Pilonidal sinus are not clear although the disease is thought to be related to the accumulation of weak and lifeless hair in the intergluteal region. Over time, foreign body reaction occurs, causing abscess and sinus formation. Obesity, trauma, local irritation and a sedentary life style are usually associated with pilonidal sinus. However collection of the lifeless hair depends on the anatomy of the intergluteal area and accompanying risk factors can lead to inadequate surgery and subsequent recurrence. The management of Pilonidal sinus is variable, contentious and problematic. A principle of treatment

requires eradication of the sinus tract, complete healing & prevention of reoccurrence. Several techniques such as cryosurgery, Z-plasty procedure, lancing under local anesthesia, vacuum assisted closure, excision with secondary healing, excision with primary closure, local flap surgery & Bossem procedure have been described by various authors. In *Ayurveda* texts, no direct reference to Pilonidal sinus as a disease entity is found. However, *Acharya Sushruta* had described that hair can be a root cause<sup>[6]</sup> for the formation of a sinus, and also mentioned various methods of management including *agnikarma* and *kshar sutra*.<sup>[7]</sup>

**Ayurvedic view about sinus and ksharasutra**

In *Ayurvedic* science *Acharya Sushruta* described sinuses under the heading of *nadivarna* along with their symptoms and management. According to *Sushruta* the irresponsible person who mistakes a suppurated inflammation for an unripe one, ignore a suppurated one, or when patient allows a lot of pus to accumulate in an ulcer, then that pus having entered into his aforesaid tissues (i.e. skin, subcutaneous tissue, muscle), penetrates inside.<sup>[8]</sup> Because of copious flow, it is known as 'gait' (track) and as it flows like a drain, it is opened as 'nadi' (sinus). That is caused by a combined action of the three dosas (*vata*, *pitta*, *kapha*) or due to each one of them

separately and also due to two together only. The other are due to shalya (foreign bodies) such as hair, straw, wood pieces, stones, dust particles, bone pieces etc.<sup>[9]</sup> So these are eight types of nadi (sinus) are told, among these pilonidal sinus can be considered to shalya nimitta nadi (foreign body sinus). According to Acharya Sushruta a surgeon should excise a sinus by means of a sutra (thread) impregnated with caustic (alkali) material (kshar-sutra) occurring in the emaciated, the weak and the timid and those (sinuses) which occur at the vulnerable areas.<sup>[10]</sup> Kshara is a caustic material obtained after processing from the ashes of various medicinal plants. The kshara are superior to sharp instruments and their substitutes because of their capability to perform excision, incision and scraping, because of their power to alleviate all the three dosas.<sup>[11]</sup> These caustic material are called kshara due to its capability of melting and destroying the lesion.<sup>[12]</sup> So kshara are not only cause the destruction (lysis) of unhealthy tissue but also help in their debridement. Hence this is an ideal procedure to be adopted for the management of sinus track as it not only destroy the fibrous wall of track as it not only destroys the fibrous wall of track but help in its curettage. There is simultaneous cutting and healing of the tract and no pocket of pus is allowed to stay back.<sup>[13]</sup> Thus it provides an environment for healthy granulation tissue to develop providing an avenue for nadivrana (sinuses) to heal completely. Further application of ksharsutra was described by a probe. A ksharsutra was described by Sushruta as direction of the sinus should first be ascertained into the track and brought out from the other end with the help of probe. The two ends of the thread should be firmly tied together. Another ksharsutra should adopt a similar procedure in case fistula-in-ano.<sup>[14]</sup>

#### Properties of Kshara:<sup>[15]</sup>

<b>Rasa</b>	<i>Katu</i>
<b>Veerya</b>	<i>Ushna</i>
<b>Varna</b>	<i>Shukla</i>
<b>Guna</b>	<i>Soumya, Tikshna, Agneya</i>
<b>Doshagna</b>	<i>Tridoshaghna</i>
<b>Karma</b>	<i>Dahana, Pachana, Darana, Vilayana, shodhana, Ropana, Shpshana</i>

#### Preparation of Ksharastra

The Barbour's surgical linen thread no.20 is tied on a hanger. Freshly collected latex of snuhi (*Euphorbia nerifolia*) is soaked in gauze piece and smeared over the thread. Once the thread is soaked with latex, the hanger is placed in a drying cabinet at a temperature of 40°C for a period of 6 hours. The process is repeatedly done for 11 times to achieve desired quantity of latex to adhere on the thread. The above thread is again smeared with latex and passed through fine powder of anhydrous apamarga (*Achyranthus aspara*) kshar and placed in the cabinet. The process is repeated for 7 times. Similarly the above thread was smeared with fine powder of haridra (*curcuma longa*), the procedure is done for 3 times. Thus total number of coating is done for 21 times.

#### CASE REPORT

Patient Name: XYZ.

Age: 32 years/M.

Occupation: Jeep Driver.

Date of 1st visit: 02/09/2017

Date of Recovery: 29/09/2017.

#### CHIEF COMPLAINTS AND DURATION

1. A small opening at sacro-coccygeal Region since 1 month.
2. Puss discharge from that opening.
3. Mild pain and itching over sinus (boil), and discomfort after prolonged sitting.

#### H/O PRESENT ILLNESS

Patient was apparently alright before 2 months. Then he had developed recurrent boil with intermittent discharge between the buttocks from last 1-2 months. He also complained of mild pain and itching over boil, and discomfort after prolonged sitting. Than above complaints occur suddenly. He had taken analgesics for it, but didn't get relief. Therefore for further treatment he came in OPD of Shalyatanra, Sumitabhai Shah Ayurved Mahavidhalaya, Malwadi, Hadapsar, Pune.

#### FAMILY HISTORY

NAD No H/O HTN, DM or any other major illness.

#### GENERAL EXAMINATION

G.C-moderate, Afebrile,

CVS- S1 S2 Normal,

Pulse- 86/min,

BP- 120/80 mm Hg,

RS- Chest clears on both sides,

Digestive System- Regular bowel habits,

Uro-genital System- NAD.

#### LOCAL EXAMINATION

In prone position of patient, the findings were: patient was hairy and having a small sinus opening near sacro-coccygeal region with seropurulent-puss discharge through opening swelling (mild), tenderness ++, foul smell and hair projecting from the opening. At palpation a cord like indurated structure was felt at external opening to gluteal cleft. Probing was done from external opening to accessed branching and extension of track. About 4 cm tract was found during probing midgluteal cleft. Secondary examination done in lithotomy position to access any anal pathology or any anal connection. It is also important to perform a thorough anorectal examination to evaluate for concomitant fistulous disease, Crohn's disease, or other anorectal pathology.<sup>[9]</sup> In that patient perianal skin was normal no dermatitis, no any external opening was present nearby anal verge, no sentinel tag, no prolapsed pile mass and no external pile were found. At digital rectal examination no any induration, tender point, pit, fissure bed, haemorrhoid mass or any pathology was found. By complete thorough examination the diagnosis was confirmed as pilonidal

sinus without anal connection or any associate anorectal disorder.

**CAUSE:** *Aagantuj Shalyaja Nadi Vrana.*

**DIAGNOSIS According to Modern Medicine:** Pilonidal Sinus.

**CHIKITSA:** All routine investigation were ruled out, CBC, Hb, blood sugar, serum creatinine, CT,BT,ECG, were with in normal limit and HBsAG, HIV were non reactive to the patient. All situations about disease and its management were explained to the patient and finally it was planned for ksharsutra therapy under local anaesthesia as per day care procedure.

### KSHARSUTRA APPLICATION

#### Pre operative preparation

Local part preparation, 5gm Haritaki churna (*Termanilia chebulata*) with kosha jala were given to the patient at night before operation. Sope-water enema was given at early morning on day to be operated. After proper bowel clean up patient was taken to recovery room and injection T.T. 0.5ml IM was given and plane xylocaine 2% was given intradermal for sensitivity test.

#### Operative procedure

Patient was taken in prone position on operation theatre table. After proper cleaning and drapping local anaesthesia with 2% xylocaine was infiltrate nearby opening and in gluteal cleft (Figure 3). Reassessment of extention of tract was done by probing. There was a 1cm upword and 3cm downword track seen. Hairs and unhealthy granulation tissue was removed through the opening on skin (Figure 4). The opening of the skin was incised to upword as the scoop can go inside and tract

was cleaned with betadine and normal saline. Probing done through opening and tract traced till its blind end and another opening was made over the skin up to the tip of the probe (Figure 5). Probe removed through another opening after feeding of *kshar sutra* and *kshar sutra* ligated appropriately (Figure 6). Hemostasis achieved and tight bandaging was done. Broad spectrum antibiotics, analgesics, Ayurvedic drugs, Hot sitz bath given. Patient was discharged from hospital on next day after operation.

### ORAL MEDICATION

Antibiotics: Tab. Ciprofloxacin 500mg orally BD.

Analgesic – Anti-inflammatory: Tab. Signoflam orally BD.

Antacid: Tab. Rantac 150mg orally BD before meal..... All for 5 days, Than SOS.

*Triphala Churna:* 1Tsf at bed time.

*Sukshma Triphala:* 2 Tab TDS.

Hot sitz Bath: Twice in Day.

### FOLLOW UPS

Patient was asked for changing *ksharsutra* every 7<sup>th</sup> day (every week) by Railroad technique<sup>[16]</sup> until “cut through” of the tract. Kept continue to Ayurvedic medicine and Hot sitz bath. Patient was advised return to job after 4 days of operation. In 5 sitting (about 35 days) the tract was totally cut by *ksharsutra* and healing of wound was achieved (Figure 8). Patient was advised *jatyadikair tailam* over scar mark.

### OBSERVATIONS

The sinus track cut through and healed simultaneously by 5 weeks. After complete healing of the track. The *Ksharsutra* was tied covering the entire track for simultaneous cutting & healing occurred.

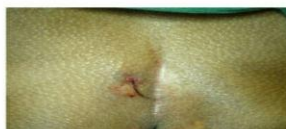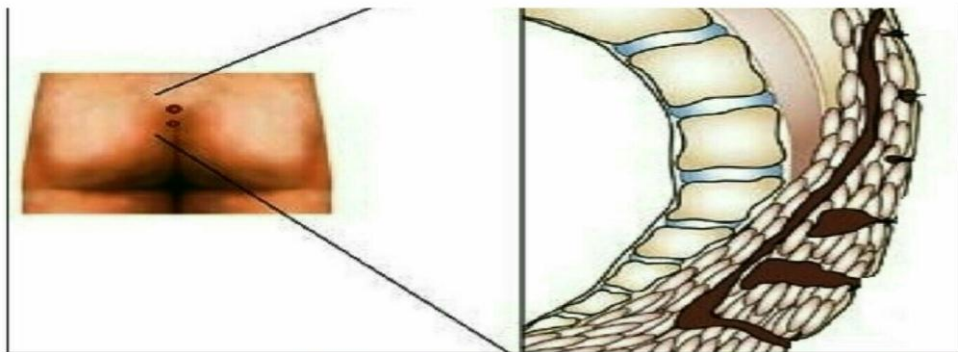


Figure 1: Pilonidal sinus with associate hairs

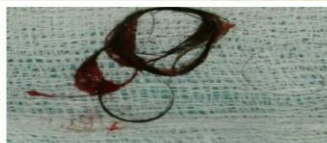

Figure 4: Bulk of hair expelled out

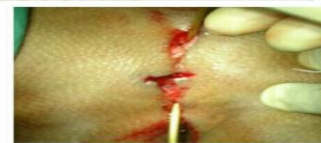

Figure 5: probing and placing of threa

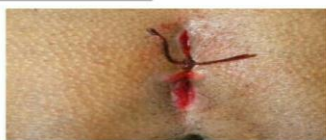

Figure 6: Placing of ksharasutra

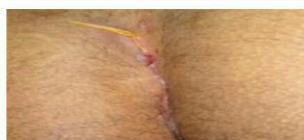

Figure 7: After 14 days

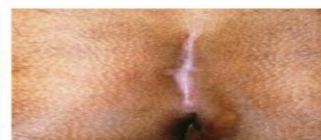

Figure 8: After 40 days complete heali

## DISCUSSION

According to Ayurveda the action of *kshar sutra* is thought to be due to its healing and cleansing effect in the area where it is applied. The *kshar sutra* acted as good drainage for the wound. *Kshar sutra* have alkaline pH so it posses desloughing property. Collectively *kshar sutra* acts as simultaneous cutting and healing procedure. So the healing was good because no collection remain in the wound site. The pain after ligation of *kshar sutra* was bearable as the patient, who is working had not taken a break for this reason. So this is ambulatory method and patient need not take a leave for long period. No side effects or complications were noted during the study. After cut through of the tract, healing of the wound site is done properly & recurrence is not noted.

## CONCLUSION

In ancient time *Acharya Sushruta* mention *Kshar sutra* therapy in *Nadivrana chikitsa*. In this case study Minimum tissue loss is seen in comparison to the other surgery. Minimal bleeding occurs & there is no need to put huge dressings. we also seen *Kshar sutra* is very efficient method for Pilonidal sinus. There was no post operative complication and there is no recurrence and any other complaints. The surgical treatment of Pilonidal sinus has many drawbacks including pain in sitting and recurrence but use of *ksharasutra* has good potential in the management of Pilonidal sinus. *Ksharasutra* helps in the debridement and lysis of tissues, and also exerts antibacterial and antifungal activities (it causes both cutting and healing actions). So we can conclude that in the management of Pilonidal sinus the use of *ksharasutra* minimizes the rate of complications and recurrence, and enables the patient to resume work and normal social activities very early.

## REFERENCES

1. Gray's Anatomy Williams P.L, 38<sup>th</sup> Ed. ELBS, 1995.
2. Maurice BA, Greenwood RK. A conservative treatment of Sacrococcygeal Pilonidal Sinus. Br Journal of Surgery, 1964; 51: 510-12.
3. Hodges R.M. Pilonidal sinus. Boston Med Surg j, 1880; 103: 485-586.
4. Prince ML, Griffiths WAD. Normal body hair: a review. Clin Exp Dermatol, 1985; 10: 87-97.
5. Pilonidal disease, Origin from follicles of hairs and results of follicle removal as treatment, John Bascon, 1975.
6. Acharya Sushruta, Sushruta Samhita; Ayurveda - Tattva - Sandipika Hindi commentary; Edited by Kaviraja Ambikadutta Shastri; Chaukhamba Sanskrit Sansthan, Varanasi, Edition; Reprint 2008; NidhanSthaana-10
7. Acharya Sushruta, Sushruta Samhita; Ayurveda - Tattva - Sandipika Hindi commentary; Edited by Kaviraja Ambikadutta Shastri; Chaukhamba Sanskrit Sansthan, Varanasi, Edition; Reprint 2008; Chikitsa Sthaana-17.
8. Kaviraja Ambikadutta Shastri, Sushruta Samhita of Maharishi Sushruta edited with Ayurveda Tattva Sandipika, Nidana Sthan, Visarpa-nadi-Stanaroga nidana, Chapter 10/9, Chaukhamba Sanskrit Sansthan, Varanasi, Reprint, 2007; 268.
9. Ambikadutta Shastri, Sushruta Samhita of Maharishi Sushruta edited with Ayurveda Tattva Sandipik. Kaviraja a, Nidana Sthan, Visarpa-nadi-Stanaroga nidana, Chapter 10/10, Chaukhamba Sanskrit Sansthan, Varanasi, Reprint, 2007; 268.
10. Gupta Rajesh comparative study of the effect of modified *kshar sutra* with standard *Ksharsutra* in the treatment of fistula-in-ano. International Ayurvedic Medical Journal, Sept-Oct 2014; 2(5): 649-658. Available from: iamj.in
11. Kaviraja Ambikadutta Shastri, Sushruta Samhita of Maharishi Sushruta edited with Ayurveda Tattva Sandipika, Nidana Sthan, Visarpa-nadi-Stanaroga nidana, Chapter 11/3, Chaukhamba Sanskrit Sansthan, Varanasi, Reprint, 2007; 34.
12. Kaviraja Ambikadutta Shastri, Sushruta Samhita of Maharishi Sushruta edited with Ayurveda Tattva Sandipika, Nidana Sthan, Visarpa-nadi-Stanaroga nidana, Chapter 11/4, Chaukhamba Sanskrit Sansthan, Varanasi, Reprint, 2007; 34.
13. Gupta Shyam K, Kghanna Vishal, Gupta Geetanjali, Bhardwaj Ankush. a comparative study to evaluate the efficacy of standard fistulectomy procedure and *kshar-sutra* ligation in the management of fistula in ano. Int. J. Res. Ayurveda Pharm, 201; 5(4): 470-473. <http://dx.doi.org/10.7897/2277-4343.05496>.
14. 14.Kaviraja Ambikadutta Shastri, Sushruta Samhita of Maharishi Sushruta edited with Ayurveda Tattva Sandipika, Nidana Sthan, Visarpa-nadi-Stanaroga nidana, Chapter 17/30,31,32, Chaukhamba Sanskrit Sansthan, Varanasi, Reprint, 2007; 81.
15. Despande P.G., Pathak SN, The Treatment of Fistula in Ano with *Ksharsutra* treatment, Nasarjuna Esition, Varanasi, 1965; 361-367.
16. Chinn BT. Outpatient management of pilonidal disease, Semin Colon Recal Surg, 2003; 1: 166-172. <http://dx.doi.org/10.1053/j.scrcs.2004.03.001>.