

CAVERNOUS HEMANGIOMA OF MAXILLARY SINUS: A RARE CASE REPORT**Rajnish Kalra¹, Deepika Jain², Gurupriya J³, Roomi Yadav^{3*}, Madhulika Parwal³, Rajeev Sen⁴**¹Professor, Department of Pathology, Pt. B.D. Sharma Postgraduate Institute of Medical Sciences, Rohtak, India.²Senior Resident, Department of Pathology, Pt. B.D. Sharma Postgraduate Institute of Medical Sciences, Rohtak, India.³Junior Resident, Department of Pathology, Pt. B.D. Sharma Postgraduate Institute of Medical Sciences, Rohtak, India.⁴Senior Professor and head, Department of Pathology, Pt. B.D. Sharma Postgraduate Institute of Medical Sciences, Rohtak, India.***Corresponding Author: Dr. Roomi Yadav**

Junior Resident, Department of Pathology, Pt. B.D. Sharma Postgraduate Institute of Medical Sciences, Rohtak, India.

Article Received on 16/11/2017

Article Revised on 07/12/2017

Article Accepted on 28/12/2017

INTRODUCTION

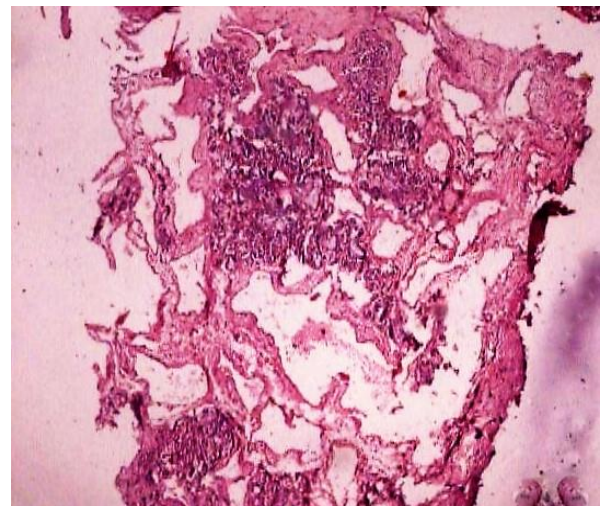
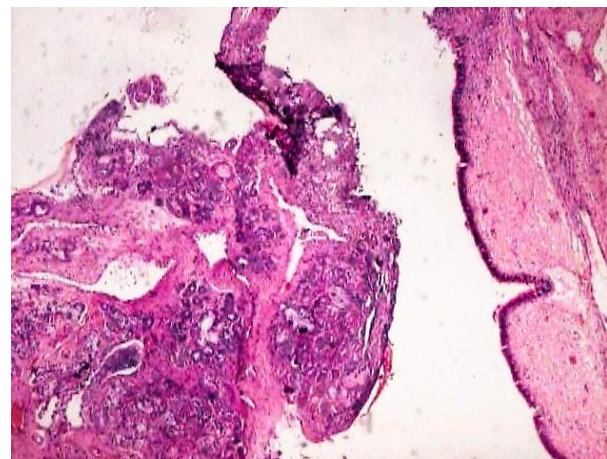
Hemangiomas are one of the most common benign soft tissue tumours, having predilection for the head and neck region.^[1] Though haemangiomas are common in the head and neck region, those of the nasal cavity and para nasal sinuses are rare.^[2] We present a rare case of a 41 year old male with cavernous hemangioma of the maxillary sinus.

CASE REPORT

A 41 year old male presented with swelling around nose and nasal discharge for 5 months. He was known case of adenoid cystic carcinoma of the maxillary sinus, completed radiation therapy and was in full remission for five years. On examination there was a non-tender, firm swelling in the left side of maxilla extending to left lateral side of nose. Mild proptosis was noted in the left eye. Anterior rhinoscopy revealed a bulge present at the floor and lateral wall of left nasal cavity. A bulge was present in the oral cavity at the midline and left half of the hard palate. The patient was admitted and endoscopic nasal biopsy was taken from multiple sites. Biopsy was taken from left maxillary sinus and sent for histopathological examination. There were no immediate complications. Unilateral anterior nasal packing was done. Other laboratory examinations such as complete blood counts, routine biochemical tests were within normal range.

Pathological examination

The histopathology examination showed blood clot, necrotic bony chips, inflammation of sino-nasal epithelium and seromucinous glands. Dilated cavernous vessels, with thickened wall at places infiltrated between seromucinous glands and the soft tissues suggestive of cavernous haemangioma.(Images 1-4).

**IMAGE 1: Low magnification view of cavernous hemangioma showing dilated blood vessels (40X).****IMAGE 2: Low magnification view of seromucinous glands of nasal cavity (40X).**

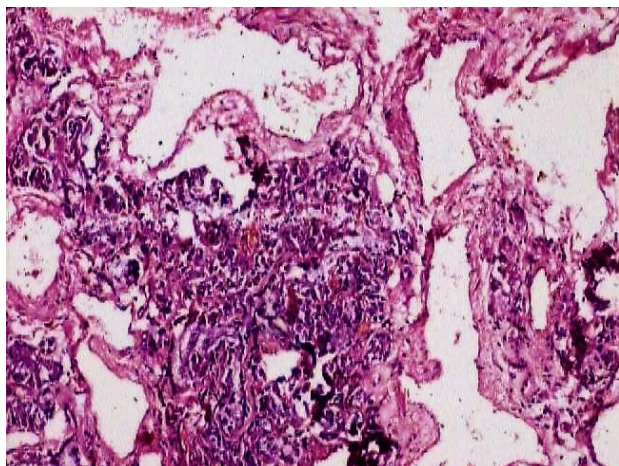


IMAGE 3: High magnification view of cavernous hemangioma showing dilated capillaries in nasal cavity (100X).

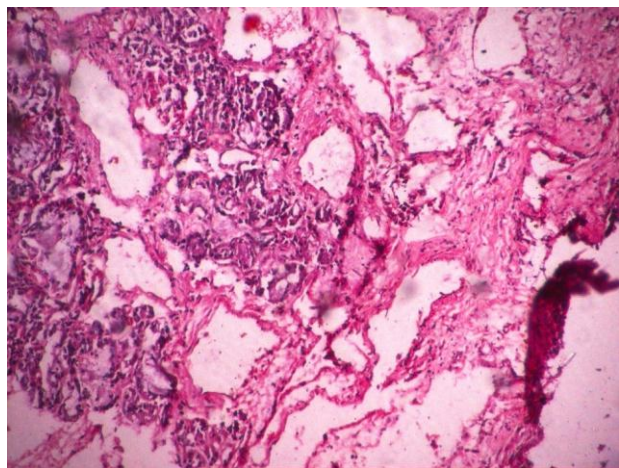


IMAGE 4: High magnification view of cavernous hemangioma showing dilated capillaries in nasal cavity (200X).

DISCUSSION

Hemangiomas are one of the most common benign slow growing vascular neoplasms of infancy and childhood; nevertheless hemangiomas are rare in adulthood.^[1] According to the revised International society for the study of vascular anomalies (ISSVA) 2014, cavernous hemangiomas were described as pseudo-tumoral vascular anomalies, rather than true neoplasm.^[3] Vascular tumours develop mainly by endothelial hyperplasia, while vascular malformations have a quiescent endothelium.^[4] Histologically, based on the dominant vessel type haemangioma can be classified into capillary, cavernous and venous.^[2,5] The characteristic appearance of capillary haemangioma is the presence of multiple small capillaries lined by a single layer of endothelium, while cavernous haemangioma are formed by large; thin walled vessels lined by flat endothelial cells.⁶ Venous haemangioma are very rare and usually present during the adult life.^[5]

Majority of haemangioma of the nasal cavity are capillary, while cavernous haemangioma are rare.

Cavernous haemangioma are frequently encountered in adult women during pregnancy because of the increased blood supply and hormonal influences.^[3] The pathogenesis of haemangioma is not very clear, abnormal levels of matrix metalloproteinase (MMP-9), proangiogenic factors like vascular endothelial growth factor (VEGF) and fibroblast growth factor (FGF) are found to contribute to the pathogenesis.^[6] The present case was a was known case of adenoid cystic carcinoma treated with radiotherapy. The role of various tumor associated growth factors including angiogenic growth factors and radiation induced changes in causation of cavernous haemangioma in this case can not be excluded.

Clinically cavernous haemangioma of the maxillary sinus are solitary, well-demarcated masses. They may be locally aggressive and cause destruction due to the pressure exerted. They do not undergo any malignant transformation.^[3] They do not regress in adults and have a chronic slow progressive course.^[6] Common symptoms include epistaxis, facial swelling and nasal obstruction.^[3] Thrombus within the vascular spaces of cavernous haemangioma may calcify and can be identified as phlebolith in computed tomography.^[2]

The differential diagnosis of Sino nasal cavernous haemangioma includes nasal polyp, antrochoanal polyp, inverted papilloma, hemangiopericytoma etc.^[7] Nasal endoscopy and radiological investigations may be misleading in cases of cavernous hemangioma. Hence angiography is used to demonstrate the vascularity in tumor.^[3] The main treatment for cavernous hemangioma is surgical, radiation therapy is reserved for inaccessible lesions.^[1] Embolization is also done to avoid intraoperative haemorrhage.^[3] Other treatment options include interferon-alfa, sclerosing agents such as 5% sodium morrhuate, cryotherapy and laser.^[6]

CONCLUSION

Cavernous hemangiomas are rare in the maxillary sinus. The lesion ie. cavernous haemangioma is the likely unknown pathogenesis. But role of various growth factors and radiation in their causation needs to be explored further. Clinical and radiological diagnosis can be misleading in these cases. Surgery is thus not only treatment option but also important in the diagnosis. In an adult patient presenting with nasal mass, epistaxis and/or nasal obstruction, cavernous hemangioma should be kept in mind as a differential diagnosis in view of avoiding intra and post-operative complications such as bleeding and for their timely prevention.

REFERENCES

1. Enzinger F, Weiss S, Goldblum J. Benign tumors and tumor like lesions of blood vessels. In: Strauss M, editor. Soft tissue tumours. Fourth edition, 847-9.
2. Archontaki M, Stamou AK, Hajjiioannou AK, Kolomenopaoulou M, Korkolis DP, Kyrmikazis DE.

- Cavernous hemangioma of left nasal cavity. *Acta Otolaryngol Ital*, 2008; 28(6): 309-11.
3. Hamdan AL, Khawaji G, Mahfoud L, Hussein S. Cavernous hemangioma of maxillary sinus: a rare cause of epistaxis. *M.E.J. Anesth*, 2012; 21(5): 757-60.
 4. George A, Mani V, Noufal A. Update on the classification of hemangioma. *J Oral Maxillofac Pathol*, 2014; 18(1): 116-20.
 5. Lin CL, Huang MT, Lin CJ. Snapping hip caused by a venous hemangioma of the gluteus maximus muscle: a case report. *J Med Case Rep.*, 2008.
 6. Mhapushkar A, Shende P. Non involuting cavernous hemangioma of buccal mucosa: A report of two cases. *J Oral Med Oral Surg Oral Pathol Oral Radiol*, 2015; 1(2): 89-92.
 7. Kalina P, Rykken J. Cavernous hemangioma of nasal cavity. *Open J Med Imag*, 2011; 1: 48-49.