

RICKETS WITH LOW 25 VITAMIN D, IS NOT ALWAYS A DEFICIENCY, IT COULD BE INHERITED RICKETS DISORDERSAmal Daghri¹, Fadhel Hazazi¹, Zainanb Saaed¹, Badi Alenazi², Nasir AM. Aljurayyan³ and Amer O. AL Ali^{1*}¹King Fahad Central Hospital, Pediatric Department, Jazan, KSA.²Pediatric Endocrine Assistant Consultant, Alyamamah Hospital, Riyadh, Saudi Arabia. ³Professor and Consultant, Dept. of Pediatric Endocrinology, College of Medicine At King Khaled University Hospital, Department of Pediatrics.**Corresponding Author: Amer O. AL Ali**

King Fahad Central Hospital, Pediatric Department, Jazan, KSA.

Article Received on 20/01/2018

Article Revised on 10/02/2018

Article Accepted on 02/03/2018

ABSTRACT

Rickets is a common disorder of bone mineralization, mostly caused by Vitamin D deficiency, but not uncommon could also result from the other genetically inherited disorder of vitamin D activation, action. One of this disorder is Vitamin D dependent rickets type IB (VDDR-1B). It is a very rare condition that has only been reported to affect around 6 families to date. It is an autosomal recessive disorder caused Mutations of CYP2R1 leading to subnormal level and function of 25 hydroxylase enzyme. like other causes of Rickets patients would present clinically with hypotonia, muscle weakness, growth failure, hypocalcemia seizures in early infancy, and radiographic findings of rickets. Here we report a 2 year old Saudi female who present with valgus deformity of the feet and delayed motor development with biochemical, radiological evidence of vitamin D disorder. Since vitamin D level was low she was assumed and treated as being due to deficiency with cholecalciferol plus one alpha for 1 year, but there was no improvement. Then diagnosis was changed to Vitamin D dependent Rickets 1B, and treatment with Calcitriol show great improvement within 3 weeks, Alkaline phosphatase and PTH both drop to normal levels. 3 months after Calcitriol treatment, radiological evidence of the resolution was clear and the patient start to move by then. In this paper, we raise the awareness that Rickets with low vitamin D25 level not always mean deficiency, especially if patient fail to improve with cholecalciferol, and in such case, a rare inherited disorder of Vitamin D activation and action should be looked for.

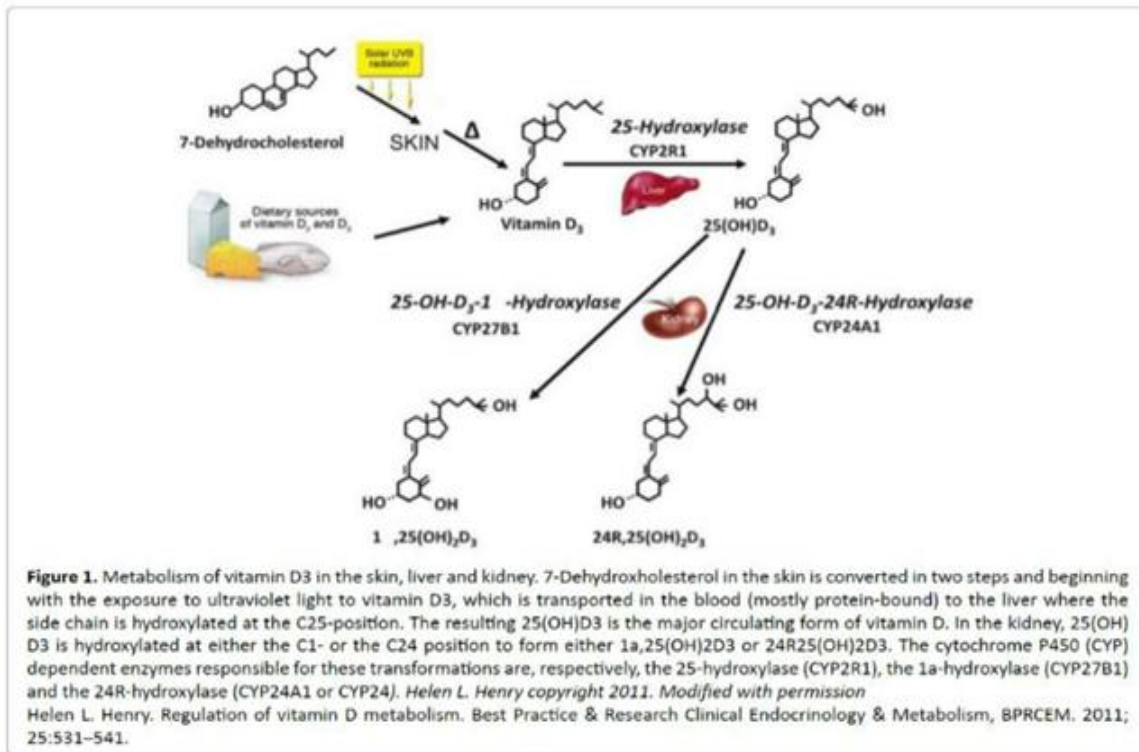
KEYWORDS: Rickets, CYP2R1, VDDR1B, 25-hydroxylase enzyme.**INTRODUCTION**

Classical vitamin D deficiency remains the major cause of rickets among children worldwide. A combination of poor nutritional, social, and climatic conditions explains much of this deficiency. Even in sunny countries such as Saudi Arabia, rickets remains prevalent in different age groups.^[1]

The prevalence of vitamin D deficiency (25-hydroxyvitamin D3 [25(OH) D3] is ≤ 25 nmol/L) and vitamin D insufficiency (25(OH)D3 level is 25-50 nmol/L) in children and adolescents between 6 and 15 years of age in the Kingdom of Saudi Arabia is 44.5% and 49.9% respectively, over all 95.4%.^[2] angham et al). In order to accurately diagnose the cause of the rickets, one should understand its activation pathway. Figure 1, show the pathway of vitamin D activation pathway.

Cholecalciferol (vitamin D-3) is formed in the skin from 5-dihydrovitachysterol. This steroid undergoes hydroxylation in 2 steps. The first hydroxylation step occur in the liver by 25-hydroxylase to produce 25(OH) D3 and the second step of hydroxylation occur in

proximal convoluted tubules in kidney by 1α -hydroxylase to produce hormonally active 1, 25-dihydroxyvitamin D3.



Any defect in this pathway or inadequate level of bone Ca, Po₄ or ALP, may lead to Rickets. VDDR 1B, (MIM 600081), is an autosomal recessive disorder, caused by Mutations of CYP2R1 gene responsible to produce 25 Hydroxylase enzyme in the liver.^[3-6]

It is a very rare condition that has been reported to currently affect around Seven families.^[7-12] patients will have low level of vitamin D 25, this is why it is common to miss it and wrongly labeled and treated as being vitamin D deficiency. In KSA, VDDR1B have been reported in 3 papers.^[2,12,13] those patients with VDDR1B) will respond to calcitriol (Vitamine D which is already hydroxylated with 25 hydroxylase enzyme).^[7]

History

In this report we describe, two years old Saudi female, with a history of delayed walking and feet deformity, she had no history convulsion or malabsorption or any chronic disease. Her nutritional history was adequate and she was not exclusively breastfeeding.

Positive consanguinity and no family history of rickets, and her mother had normal vitamin D25 level during pregnancy.

Her examination shows frontal bossing, rachitic rosary. Growth parameters show growth restriction, height, - 3 SD but her weight was -1 SD. with lower limb abnormalities (genu valgus) and mild hypotonia.

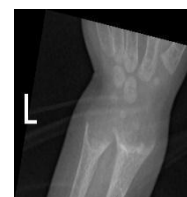Other systemic examination was unremarkable investigations.

test	Result	Normal Range
vitamin D25 level of 10 ng/dl	10 ng/dl (low)	30-70 ng /dl
Vitamin D1, 25	17 pg/ml (normal	15-75 pg/mL),
PTH	120 pmol /l (high)	2-7 Pmol/l
ALP	2800 U/L (high)	150- 350 u/1
Phosphorus	0. 5mmol/L (low)	1. 2 -2. 8 MMOL /
Calcium	1. 8 mmol/L (low)	2. 2-2. 8 mmol/L
Ca /Creatinine ratio in urine =	0. 1 mmol (low)	Less than 0. 2

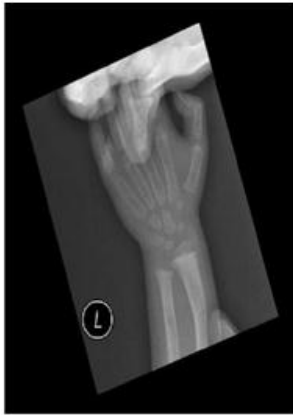Other electrolyte and CBC, Renal, Liver function, Celiac screening was normal.

Radiology

X. ray show active rickets (A), which was resolved 3 months after calcitriol (B).



A. Wrist X. ray before Calcitriol.



B. Wrist X. ray 3 months after Calcitriol.

Diagnosis and Treatment

Since patients received for 1 year cholecalciferol and one alpha without any improvement, our impression was VDDR1B and we start Calcitriol 1 mic od, elemental Calcium 50 mg /kg/day for 1 month in order to avoid hunger bone syndrome plus Phosphorus supplements of 250 mg for 3 weeks then was stopped to avoid stimulation of PTH by phosphate.

Surprisingly, after 3 weeks of Calcitriol, all biochemical parameters was normalized including ALP, PTH, CA, Po₄, and start to move at age of 2 years, after 3 months of calcitriol.

DISCUSSION

Rickets is a common bone mineralization disorder worldwide. most of the cases are caused by vitamin D 25 deficiency which can be diagnosed base on history of poor nutrition, more common in exclusively breastfed infants, those with poor sun exposure or in infants born to a mother with untreated Vitamin D Deficiency during pregnancy.

Most physicians will treat those kids with rickets and low level of Vitamin D 25 with cholecalciferol. And most of them will respond well to this treatment. But sometimes patients might not respond well to cholecalciferol. In such cases one should think and ask why patient is not responding. Causes of poor response include, poor compliance, inadequate dose, malabsorption, if those ruled out, then one should think about the rare inherited genetic causes of Rickets like VDDR1b.^[7]

VDDR1b commonly confused with simple Vitamin D deficiency because both will have same clinical, biochemical, radiological picture of active Rickets, including low level of Vitamin D 25 level. The best way to differentiate between them is to check the gene for VDDR1B named CYP2R1 gene.^[2,4]

In case if this is unavailable like our patient, then a trial of calcidiol or calcitriol can be tried and reassessment of ALP, PTH level few weeks after.

In our patients who have clinical, radiological, biochemical manifestation of Rickets which started early in life (6 months) and was treated in another hospital as being Vitamin D deficiency and given cholecalciferol for 6 months and then one alpha for 6 months then was referred to us. After we review her history, we found that she was not exclusively breastfeeding and nutritional history was adequate, and mother Vitamin D level was normal, but the baby has very low level of Vitamin D25 this raise our concern for the possibility of poor medication adherence but parents ensure that was not the case, then malabsorption was ruled out by the absence of diarrhea, and Celiac screening was negative. After those possible causes of poor response was ruled out, then we thought about the possibility of the inherited genetic cause of Rickets, first come to our mind was VDDR1a, but those should respond well to one alpha supplements which our patient received for 6 months Without a response.

So, since the patient was already in Vitamin D, Ca, supplements for a long time and its confusion if labs done while the patient still on treatment, so we decide to stop all treatment for 2 weeks, then to repeated all labs, and result came as typical picture of Rickets, with low level of Vitamin D 25 (see investigation above). from those labs our diagnosis was VDDR1B, so gene was requested and result still pending, and we start trial of calcitriol 1mic od, and after few weeks of Calcitriol, ALP, PTH, Ca, Po₄ all was dropped to normal levels. 3 months after Calcitriol, radiological evidence of healing was clear (see X ray B above) and patient continue to do fine on Calcitriol 1 mic, and started to walk at age of 2 years and parents are happy.

The choice drug for treatment of VDDR1B is calcifediol which is vitamin D hydroxylated with 25 enzyme, so no need to combine it with cholecalciferol, since it is one form of vitamin D. Same when treating patients with renal failure or VDDR1a with alfalcidol, no need to add cholecalciferol even of vitamin D25 level was low, since alfalcidol is a form of vitamin D hydroxylated with the enzyme one alpha.

In some patients the labs might be confusions like our patient who was on already on treatment, so in such cases, Calcitriol is the best drug to choose since it work for VDDR1a or VDDR1B or VDDR2 (higher dose).

Mutations of CYP2R1 have been associated with vitamin D-dependent rickets type 1B (VDDR1B).

Molin A et al^[7] in 2017 they described the molecular analysis of 7 patients from unrelated families who presented with VDDR type 1B due to loss of function mutation of CYP2R1 and a new mutation. They noted the specific biochemical pattern of the disease and its dramatic improvement with 25- hydroxyvitamine D therapy.

Almutair et al^[12] observed the symptoms of vitamin D deficiency with normal dietary history and poor response of 25(OH)D₃ level to D₂ or D₃ treatment, especially with a strong family history of vitamin D deficiency should raise the suspicion of genetic causes for CYP2R1 mutations (VDDR1B). Patients with CYP2R1 mutations have normal or high 1, 25(OH)D₃ (if received vitamin D and they need supra-physiological doses of Cholecalciferol to see full or partial improvement.^[8-12]

Prognosis of VDDR1B is excellent and Interestingly, adult patients were able to maintain normal mineral metabolism without vitamin D supplementation.^[7]

CONCLUSION

So as topic named, low level of vitamin D₂₅ is not always Vitamin D deficiency. Worldwide, similar cases were recognized and published in order to raise the awareness of VDDR1b and its similarity to Vitamin D deficiency.^[5,6] This should be suspected in any patient with Rickets with low vitamin D₂₅ level, whose nutritional history is adequate and is not exclusive breast feeding, those patients will not respond to cholecalciferol and will respond well to calcitriol or the active form of vitamin D Calcitriol.

REFERENCES AND SUGGESTED READING

1. Al-Atawi, Al-Alwan, Al-Mutair, et al. Epidemiology of nutritional rickets in children. Saudi Journal of Kidney Diseases Transplantation, SJKDT, 2009; 20: 260–265.
2. Almutair Angham N, Yasser A. Vitamin D deficient rickets: Not always nutritional. Journal of Rare Diseases Research and Treatment, 2017.
3. Fraser D, Kooh SW, Kind et al. Pathogenesis of hereditary vitamin-D-dependent rickets. An inborn error of vitamin D metabolism involving defective conversion of 25-hydroxyvitamin D to 1 α , 25-dihydroxyvitamin D. N Engl J Med, 1973; 289: 817–822.
4. Scriver CR, Reade TM, DeLuca et al. Serum 1, 25-dihydroxyvitamin D levels in normal subjects and in patients with hereditary rickets or bone disease. N Engl J Med, 1978; 299: 976–979.
5. Delvin EE, Glorieux FH, Marie et al. Vitamin D dependency: replacement therapy with calcitriol? J Pediatr, 1981; 99: 26–34.
6. Kato Shigeaki; Yanagisawa, Junn; Myrayama et al. The importance of 25-hydroxyvitamin D₃ 1 α -hydroxylase gene in vitamin D-dependent rickets. Curr Opin Nephrol Hypertens, 7: 377- 383.
7. Molin A, Wiedemann A, Demers N, Kaufmann et al. Vitamin D-Dependent Rickets Type 1B (25-Hydroxylase Deficiency): A Rare Condition or a Misdiagnosed Condition?. J Bone Miner Res, 2017 Sep; 32(9): 1893-1899.
8. Casella SJ, Reiner BJ, Chen TC, et al. A possible genetic defect in 25-hydroxylation as a cause of rickets. Journal of Pediatrics, J. Pediatr, 1994; 124: 929–932.
9. Cheng JB, Levine MA, Bell et al. Genetic evidence that the human CYP2R1 enzyme is a key vitamin D 25-hydroxylase. Proc Natl Acad Sci USA, 2004; 101: 7711–5.
10. Levine MA, Dang A, Ding et al. Tropical rickets in Nigeria: mutation of the CYP2R1 gene encoding vitamin D 25-hydroxylase as a cause of vitamin D dependent rickets. Bone, 2007; 40: S60–1.
11. Thacher TD, Fischer PR, Singh et al. CYP2R1 mutations impair generation of 25-hydroxyvitamin D and cause an atypical form of vitamin D deficiency. J. Clin Endocrinol Metab, 2015; 100: E1005–13.
12. Al Mutair AN, Nasrat GH, Russell DW. Mutation of the CYP2R1 vitamin D 25- hydroxylase in a Saudi Arabian family with severe vitamin D deficiency. J Clin Endocrinol Metab, 2012; 97: E2022–5.
13. Afaf AlSagheir, Faiqa Imtiaz, Sarah Bakhamis, et al. Clinical and Molecular Characterization of 25-Hydroxylase Deficiency in Saudi Patients. ESPE Abstracts, 2016; 86: P-P1-116.
14. Demay MB. Rickets caused by impaired vitamin D activation and hormone resistance: pseudovitamin D deficiency rickets and hereditary vitamin D-resistant rickets. In: Favus MJ, editors. Primer on the Metabolic Bone Diseases and Disorders of Mineral Metabolism, 6th ed. Washington: American Society for Bone and Mineral Research, 2006; 338-341. 13.
15. Nicolaidou P, Tsitsika A, Papadimitriou et al. Hereditary vitamin D-resistant in Greek children: genotype, phenotype, and long-term response to treatment. J Pediatr Endocrinol Metab, 2007 Mar; 20(3): 425-30.
16. Wang JT, Lin CJ, Burrige et al. Genetics of vitamin D 1 α -hydroxylase deficiency in 17 families. Am J Hum Genet, 1998; 63: 1694–702.
17. Rani, P. Radha et al. “Seizure as a Presenting Manifestation of Vitamin D Dependent Rickets Type 1.” Indian Journal of Endocrinology and Metabolism, 2013; 17(3): S665–S666. PMC. Web. 17 Jan. 2018.