

**CLINICAL PROFILE OF NEUROLOGICAL COMPLICATIONS OF DENGUE FEVER IN
A TERTIARY CARE CENTER****¹Dr. L. Rajagopala Marthandam MD*, ²Dr. P. Renuga MD and ³Dr. Susan George**¹Professor, Department of Medicine, Tirunelveli Medical College, Tirunelveli.²Senior Assistant Professor, Department of Medicine, Tirunelveli Medical College, Tirunelveli.³Post Graduate in General Medicine, Tirunelveli Medical College, Tirunelveli.***Corresponding Author: Dr. L. Rajagopala Marthandam**

Professor, Department of Medicine, Tirunelveli Medical College, Tirunelveli.

Article Received on 04/04/2018

Article Revised on 25/04/2018

Article Accepted on 15/05/2018

ABSTRACT

Introduction: Dengue fever is highly endemic in India especially in southern parts. In recent years, the virological characteristics of dengue viruses have been changing, resulting in widespread neurological complications. The neurological complication in dengue infection has been mainly hypothesized through three pathogenic mechanisms: like neurotropism leading to encephalitis, meningitis, myositis and myelitis, systemic complications and (3) post-infectious immune-mediated complications. **Materials and Methodology:** In this prospective study, we studied various neurological complications observed in patients admitted in a tertiary care center in south Tamil Nadu during the period from June 2017 to December 2017. Patients with neurological complications with positive serology (IgM antibody) for dengue infection were identified and investigations were done to elucidate the cause.

Results: According to our study neurological complications showed a female predominance with maximum cases among age group 20-29 years. Encephalitis and encephalopathy were the most common neurological manifestations. Shock was the most common etiology leading to encephalopathy. Fever, headache, retro orbital pain, altered sensorium and myalgia were the predominant symptoms. Majority of the patients developing neurological complications showed leucopenia and had elevated liver enzymes. Vast majority had gall bladder wall edema on USG abdomen. Bilateral thalamic hypo density was the most common observation in CT Brain.

Conclusion: Neurological complications of dengue infection are widespread and may involve almost all parts of the nervous system through various mechanisms. So dengue infection should be considered and properly investigated in patients presenting with various neurological disorders without obvious etiology, especially if preceded by a febrile illness compatible with dengue fever.

KEYWORDS: Encephalitis, meningitis, myositis and myelitis.**INTRODUCTION**

Dengue fever is an arboviral infection prevalent in tropics, transmitted via *Aedes aegypti* mosquito. Around 2.5 billion population worldwide is at risk of dengue infection, and the endemic zone comprises more than 100 countries of the world.^[1] 4 antigenically related serotypes cause dengue infection.^[2] Dengue infection can have a wide spectrum, ranging from mild acute febrile illness to lethal dengue hemorrhagic fever and dengue shock syndrome. Neurological complications of dengue infection have been observed more frequently now a days. In recent years, the virological characteristics of dengue viruses have been changing, resulting in widespread neurological complications. The neurological complication in dengue infection has been hypothesized through three pathogenic mechanisms: (1) concerned with neurotropism leading to encephalitis, meningitis, myositis and myelitis, (2) systemic complications resulting in encephalopathy, stroke and hypokalemic paralysis and (3) postinfectious immune-mediated acute

disseminated encephalomyelitis, Guillain Barre syndrome and optic neuritis³. In this prospective study done in a tertiary care center of South Tamilnadu, we describe presenting pattern of various neurological complications associated with dengue fever observed in the last 7 months.

AIMS AND OBJECTIVES

The aim of our study was to find sex distribution, age distribution of neurological complications in cases of dengue fever. We also assessed the most common neurological complication and most common symptoms of neurological involvement and correlated with laboratory and radiological parameters.

MATERIALS AND METHODOLOGY

In this prospective observational study, we analyzed various neurological complications observed in 30 patients admitted in a tertiary care center in South Tamil Nadu during the period from June 2017 to December

2017.1330 proven dengue cases were admitted in our hospital during the study period. Patients with neurological complications with positive serology (IgM antibody) for dengue infection were identified and investigations were done to elucidate the cause. This study was approved by the institutional ethical committee. All the patients of dengue fever presenting with neurological manifestations were included in the study. The dengue fever was diagnosed on the basis of the positive serum IgM antibody to dengue fever. The serum IgM antibody were analyzed by ELISA. The baseline characteristics, including age, sex, occupation and socioeconomic class, were noted. A detailed history, clinical evaluation and detailed neurological examination was performed in all patients. Systemic complications of dengue fever including jaundice, lymphadenopathy, and hepatosplenomegaly, cardiac, gastrointestinal, respiratory and hematological manifestations were specifically examined. The laboratory investigations like

hemoglobin level, blood counts, platelets estimation, hematocrit, blood sugar, liver function test, renal function test, creatine kinase, PT, aPTT and electrolytes were performed in all patients. ECG and chest X-ray were done. CT/ MRI Brain or both were done as required. ELISA for dengue IgM was performed in serum in all patients. The cerebrospinal fluid analysis including IgM antibody for dengue fever, PCR study for Japanese encephalitis virus were performed in the cerebrospinal fluid in patients suffering from encephalopathy/encephalitis.

RESULTS

Thirty patients with neurological complications associated with dengue infection were analyzed during the period June 2017 to December 2017. 60% of the patients were female and rest were male. Study population predominantly belonged to age group 20-29 years (40%) (Chart 1) with mean age 26 years. (Table 1)

Table 1: Prevalence of dengue encephalopathy in relation to age and sex.

Sl. No	Age group	Male	Female	Total
1	13-19 years	5	4	9
2	20-29 years	3	9	12
3	>30	4	5	9
	Total	12	18	30

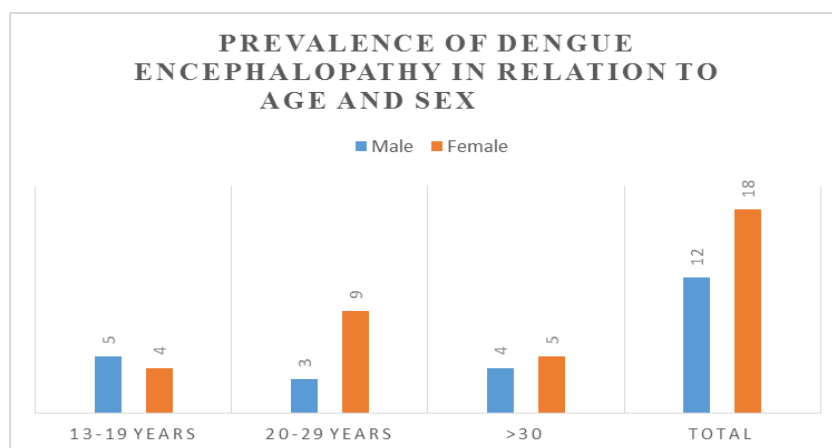


Chart 1: Prevalence of dengue encephalopathy in relation to age and sex

Most common neurological manifestation was encephalitis (15/30) followed by encephalopathy (11/30)

and involuntary movements (4/30) in the form of orofacial dystonia and tics. (Table 2)

Table 2: Profile of neurological manifestations.

Sl.no.	Neurological manifestations	Number of cases	%
1	Encephalopathy	11	36.67
2	Encephalitis	15	50
3	Haemorrhagic encephalitis	1	3.33
4	ADEM	1	3.33
5	GBS	0	0
6	Myositis	2	6.67
7	Internuclear ophthalmoplegia	1	3.33
8	ICH	1	3.33
9	Hypokalemic paralysis	1	3.33
10	Cerebellar involvement	2	6.67
11	Involuntary movements	4	13.33

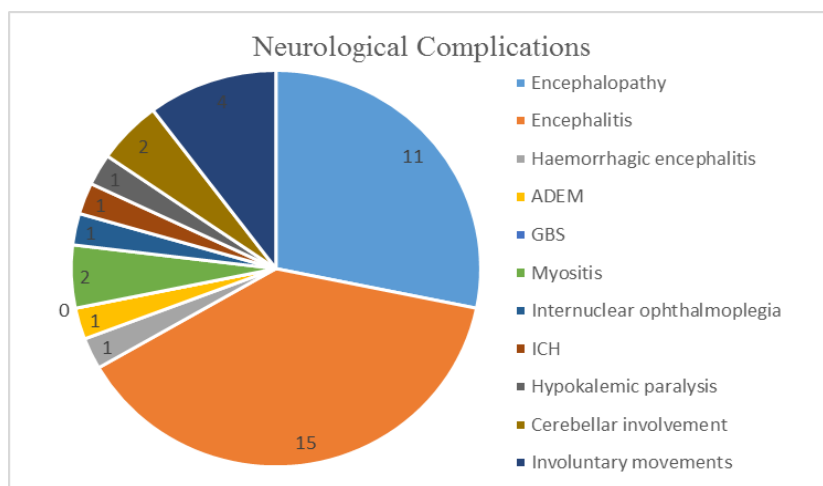


Chart 2: Neurological Complications.

Similarly when we analysed the causes of encephalopathy, Shock (9/11) was found to be the major contributor to encephalopathy followed by cerebral oedema (4/11). (Table 3)

Table 3: Causes for encephalopathy.

Sl no	Cause for encephalopathy	Number of cases
1	Hepatic encephalopathy	2
2	Shock	9
3	Cerebral edema	4
4	Dyselectrolytemia	1
5	Intra cerebral haemorrhage	1

All patients had fever, other common clinical manifestations encountered were headache, myalgia, retro orbital pain and altered sensorium. (Table 4).

Table 4: Prevalence of clinical features in dengue with neurological manifestations.

Sl no	Clinical features	Number of cases
1	Fever	30
2	Headache	26
3	Myalgia	20
4	Retro orbital pain	15
5	Rash	3
6	Bleeding manifestations	5
7	Seizures	5
8	Altered sensorium	12

All patients showed thrombocytopenia, leucopenia was more common than leucocytosis in patients who developed neurological complications. Dengue fever patients who had an increased SGOT/SGPT were found

to develop neurological complications frequently compared to those with normal liver function tests. (Table 5)

Table 5: Prevalence of laboratory abnormalities in dengue with neurological manifestations.

Sl no	Laboratory abnormalities	Number of cases
1	Thrombocytopenia (<1 lakh)	30
2	Leucopenia (<4000)	12
3	Leucocytosis (12000)	3
4	Elevated SGOT(>40)	20
5	Elevated SGPT(>40)	11
6	Abnormal coagulation profile	7

Majority of the patients had only a minimal rise in SGOT (9/20) and SGPT (4/11). (Table 6)

Table 6: Pattern of altered liver enzymes in dengue with neurological manifestations

Sl no	Lab values (units /L)	No of cases with elevated SGOT	No of cases with elevated SGPT
1	40-119	9	4
2	120-199	4	3
3	200-999	5	3
4	>1000	2	1
	Total	20	11

In chest X-Ray ARDS pattern was most common whereas in USG abdomen majority had gall bladder wall oedema. CT Brain bilateral thalamic hypodensity was the characteristic appearance.

Table 7: Prevalence of radiological abnormalities in dengue with neurological manifestations

Investigation	Finding	Number of cases
Chest X-Ray	ARDS	8
	Pleural effusion	7
USG - Abdomen	Gall bladder wall oedema	21
	Ascites	13
CT & MRI Brain	Bilateral thalamic hypodensity	7
	Brainstem encephalitis	1
	Cerebral oedema	5
	Intra cerebral haemorrhage	1
	Haemorrhagic encephalitis	1

DISCUSSION

In our study various neurological manifestations in association with dengue fever were observed. We included patients with age more than 13 years, female's outnumbered males in our study & most patients belonged to age group 20-29 years (40%) with mean age of 26 years. Various studies mentioned age range 18-35 years (mean 27 years), 5-65 years and male sex predominance in a large cohort related to neurological complications associated with dengue infection.^[3,4] The true incidence of neurological complications associated with dengue fever are not clearly mentioned in the literature. One study described 41 cases of neurological complications due to dengue fever and those patients had both central and peripheral neurological complications⁵. Misra *et al* described 17 patients of neurological complications in his prospective hospital-based study, Wasay *et al* mentioned 6 patients with neurological manifestations and Solomon *et al* reported 9 patients with dengue fever having encephalitis.^[4,6,7]

Incidence of neurological complications in dengue fever is about 0.5-6%.^[8] Incidence in our study was 2.2% which is comparable to other studies. It may occur either by direct (neurotropism) or by immunological mechanisms. Some patients with dengue encephalitis showed dengue antigen in brain.^[9] Cerebral edema, cerebral hemorrhage, hyponatremia, hypoxia, renal and hepatic insult are the causes attributed to dengue encephalopathy. Autoimmunity, molecular mimicry or nonspecific activation of autoreactive T cells causing destruction of myelin sheath/self-antigens are found to be the basis for immune-mediated disorders such as Guillain barre syndrome & acute disseminated encephalomyelitis.^[3,10] In a case report of ADEM, patient

was found to have hemorrhagic demyelinating lesions and thrombocytopenia was the explanation for the same.^[11]

Misra *et al* reported 6 cases of pure motor quadriplegia among dengue fever patients.^[6] Nerve conduction study was normal in all of them, electromyography showed myopathic pattern with raised serum creatine phosphokinase which suggested acute viral myositis and all the 6 improved with treatment.^[6] A tertiary care center in north India recently published study describing 7 acute dengue viral myositis in that authors highlighted that acute dengue viral myositis can be fulminant demanding ventilatory support. Early respiratory involvement, severe myalgia and elevated serum creatine phosphokinase levels were considered as markers of severe myositis.^[12]

More and more cases of hypokalemic paralysis in association with dengue fever are being reported. We also report one patient who developed acute onset motor weakness with low serum potassium values who showed drastic improvement upon potassium correction. Several mechanisms for hypokalemia in dengue fever include: (1) redistribution of potassium into cells, (2) transient renal tubular abnormalities causing excessive urinary potassium wasting and (3) increased catecholamine levels secondary to infections, secondary insulin resistance causing intracellular shift of potassium.^[13]

We also report a case of dengue fever with internuclear ophthalmoplegia (INO) which to the best of our knowledge wasn't reported previously in association with dengue in literature. An additional observation was

the presence of involuntary movements in the form of orofacial dystonia and tics.

The investigations for dengue virus infection include virus detection by culture, viral nucleic acid or antigen detection (NS 1) on first 5 days of fever. After acute phase, serology is preferable. Viral RNA nucleic acid detection by PCR are quite specific (100%) and sensitive (70%) in early acute phase, but are more costly, technical and not available freely. They are not of much value in the later part of the illness when various neurological complications arise. As IgM antibody suggest recent infection, the detection of “dengue-specific” IgM antibody (serology) is the preferred investigation modality after 5 days of fever onset.^[14] Dengue infection should always be considered and properly investigated in patients presenting with various neurological disorders without obvious etiology, especially if preceded by a febrile illness compatible with dengue fever as dengue can have umpteen number of neurological manifestations.

CONCLUSION

Globally dengue fever has become a major threat to humanity especially in the tropics like India. Neurological complications of dengue infection are widespread and may involve almost all parts of the nervous system through various mechanisms. So dengue infection should be considered and properly investigated in patients presenting with various neurological disorders without obvious etiology, especially if preceded by a febrile illness compatible with dengue fever. Altered liver function test may be considered as a harbinger of dengue encephalopathy and must be dealt with caution.

REFERENCES

1. Dengue haemorrhagic fever; diagnosis, treatment, prevention, and control. Geneva: WHO; 1997. World Health Organisation.
2. Halstead SB. Dengue. *Lancet*, 2007; 370: 1644–52.
3. Murthy J. Neurological complications of dengue infection. *Neurol India*, 2010; 58: 581–4.
4. Wasay M, Channa R, Jumani M, Shabbir G, Azeemuddin M, Zafar A. Encephalitis and myelitis associated with dengue viral infection clinical and neuroimaging features. *Clin Neurol Neurosurg*, 2008; 110: 635–40.
5. Ferreira ML, Cavalcanti CG, Coelho CA, Mesquita SD. [Neurological manifestations of dengue: Study of 41 cases] *Arq Neuropsiquiatr*, 2005; 63: 488–93.
6. Misra UK, Kalita J, Syam UK, Dhole TN. Neurological manifestations of dengue virus infection. *J Neurol Sci*, 2006; 244: 117–22.
7. Solomon T, Dung NM, Vaughn DW, Kneen R, Thao LT, Raengsakulrach B, et al. Neurological manifestations of dengue infection. *Lancet*, 2000; 25(355): 1053–9.
8. Hendarto SK, Hadinegoro SR. Dengue encephalopathy. *Acta Paediatr Jpn*, 1992; 34: 350–7.
9. Lum LC, Lam SK, Choy YS, George R, Harun F. Dengue encephalitis: A true entity? *Am J Trop Med Hyg*, 1996; 54: 256–9.
10. Varatharaj A. Encephalitis in the clinical spectrum of dengue infection. *Neurol India*, 2010; 58: 585–91.
11. Sundaram C, Uppin SG, Dakshinamurthy KV, Borghain R. Acute disseminating encephalomyelitis following dengue haemorrhagic fever. *Neurol India*, 2010; 58: 599–601.
12. Paliwal VK, Garg RK, Juyal R, Husain N, Verma R, Sharma PK, et al. Acute dengue virus myositis: A report of seven patients of varying clinical severity including two cases with severe fulminant myositis. *J Neurol Sci*, 2011; 300:14–8.
13. Jha S, Ansari MK. Dengue infection causing acute hypokalemic quadriplegia. *Neurol India*. 2010; 58:592–4
14. Dengue guidelines for diagnosis, treatment, prevention and control new edition. Geneva: World Health Organization; 2009. WHO.