

**CURCUMIN AMELIORATES THE HAZARD EFFECT OF PRENATAL  
BETAMETHASONE ADMINISTRATION ON THE FETAL ADRENAL GLAND OF  
ALBINO RATS**

\*Gamal M. Badawy

Zoology Department, Faculty of Science, Menoufiya University, Egypt.

\*Corresponding Author: Dr. Gamal M. Badawy

Zoology Department, Faculty of Science, Menoufiya University, Egypt.

Article Received on 14/10/2018

Article Revised on 04/11/2018

Article Accepted on 25/11/2018

**ABSTRACT**

The present study aimed to investigate the possible adverse effects of maternally injected betamethasone on the developing adrenal gland of the albino rat (*Rattus norvegicus*) fetuses. Another aim was to ameliorate these adverse effects using crude water extract of curcumin. The experimental pregnant rats were injected with betamethasone alone, curcumin alone, betamethasone followed by an oral injection of curcumin while the control ones were injected with distilled water. Injection started from gestation day (GD) 11 and ended at DG 16. For the sake of eliminating differences owing to the time factor, the experiments were terminated at the 20<sup>th</sup> day of pregnancy for all groups. The released fetuses were dissected and the adrenal glands were taken out for investigation. Three integrated approaches namely, histological, immuno-histochemical and ultrastructural were adopted. Betamethasone prenatally administration caused massive destructive changes within the two components of the adrenal gland i.e. the cortex with its three zones and the medulla at all the three adopted levels. The study provided clear evidences for the ameliorative role of curcumin against the hazard effect of the maternally administered betamethasone upon the developing adrenal gland.

**KEYWORDS:** Curcumin, Betamethasone, Adrenal gland, Rat fetuses.**INTRODUCTION**

The adrenal gland is composed of two embryologically different tissues, the cortex and medulla. The primordium of the cortex is derived from mesenchymal tissue, which begins to produce steroid hormones during fetal development, but complete histological and functional maturation of the mineralocorticoid-synthesizing zona glomerulosa (ZG), glucocorticoid-producing zona fasciculata (ZF) and inner zona reticularis (ZR) occurs during the neonatal period.<sup>[1,2]</sup> Chromoblasts are progeny of the neural crest, with a catecholaminergic fate. They migrate into the adrenal gland primordium from GD 15 to form the centrally located medulla.<sup>[3]</sup>

It is well known that numerous factors can affect the differentiation and secretory capacity of the fetal adrenal gland. Among these factors is the status of those maternal hormones that influence the fetal hypothalamo-hypophyseal-adrenal system.<sup>[4]</sup> Due to their potent effect on the maturation of fetal tissues, synthetic glucocorticoids are used in human pregnancy at risk of preterm delivery. Despite the

numerous positive effects, exposure to synthetic glucocorticoids during fetal development may result in intrauterine growth retardation and fetal programming of the hypothalamic-pituitary-adrenal (HPA) axis function which is associated with cardiovascular, metabolic and psychiatric disorders manifested later in life.<sup>[5]</sup> Long-term consequences indicate the need for the implementation of new studies that will provide a better understanding of the link between glucocorticoid exposure during fetal development and adverse outcomes in adulthood.<sup>[6,7,8]</sup> The enzyme 11 $\alpha$ -hydroxysteroid dehydrogenase (11 $\alpha$ -HSD) type 2 is expressed in the human placenta and has been suggested to influence the trans-placental transfer of maternal cortisol to the fetus, by metabolism to inactive cortisone.<sup>[9]</sup> However, alterations in the activity or the expression of this enzyme may expose the fetus to increased levels of maternal glucocorticoid that could potentially program fetal responses leading to cardiovascular and/or metabolic disease in later life.<sup>[10]</sup>

Glucocorticoids affect the development and function of many other endocrine systems in the fetus and placenta, particularly during late gestation.<sup>[11]</sup> In the fetus, they affect almost all of the endocrine systems functional, including the HPA axis itself. Indeed, changes in endocrine function induced by early glucocorticoid exposure *in utero* are known to persist after birth to alter the adult endocrine environment.<sup>[12]</sup> For instance, prenatal glucocorticoid exposure alters adult HPA function at every level of the axis from the brain to tissue glucocorticoid bioavailability.<sup>[13]</sup> In turn, these programmed changes in HPA function may contribute to the adult cardiometabolic dysfunction associated with prenatal glucocorticoid exposure. The regulatory effects of glucocorticoids on intrauterine development, therefore, involve multiple interactions between different endocrine systems, when glucocorticoids are acting as both maturational and environmental signals.<sup>[14]</sup> Synthetic glucocorticoids, such as betamethasone, are poor substrates for the placental 11\_HSD enzyme,<sup>[15]</sup> and consequently pass relatively freely across the placenta into the fetal circulation. As a result, synthetic glucocorticoids are used to enhance fetal lung maturation in women at risk of preterm delivery.<sup>[16]</sup>

Curcumin has been used widely to treat wounds and sprains, and gastrointestinal, pulmonary, and liver disorders,<sup>[17]</sup> Interest in the benefits of curcumin has increased dramatically over the past decade with number of clinical studies currently underway investigating its efficacy for treating and/or preventing a range of diseases. Many pharmacological studies have been conducted to describe multiple biological actions of curcumin.<sup>[18]</sup> These studies have demonstrated that curcumin possesses antioxidant,<sup>[19]</sup> anti-inflammatory,<sup>[20]</sup> anti-carcinogenic,<sup>[21]</sup> anti-bacterial,<sup>[22]</sup> immunomodulatory<sup>[23]</sup>, antimicrobial,<sup>[24,25]</sup> hypoglycemic,<sup>[26]</sup> and hypocholesterolemic<sup>[27]</sup>, hepatoprotective,<sup>[28,29]</sup> activities. In addition, our previous studies found that curcumin has an evident ameliorative effect against betamethasone induced embryo-toxicity in rats,<sup>[29,30,31]</sup>

In mammals, the fetal adrenal gland plays a key role during the last third of gestation since glucocorticoids are involved in the maturation of many fetal organ systems.<sup>[32]</sup> Considering both the possible hazard effect of betamethasone maternally administration on the fetal adrenal gland and the possible ameliorative role of curcumin, this study has been designed with a double target.

## MATERIALS AND METHODS

### Animals and grouping

All the experiments were done in compliance with the guide for the care and use of laboratory animals approved by Faculty of Science, Menoufiya University, Egypt. Healthy mature virgin females and fertile males of Wistar albino rats (*Rattus norvegicus*), weighing  $145 \pm 5$  g were obtained from Hellwan Animal Breeding Farm, Ministry of Health, Cairo, Egypt. Rats were kept in the laboratory for at least one week before initiation of the experiments for acclimatization. They were housed in specially designed plastic rodent cages at Faculty of Science, Menoufiya University and maintained at  $25 \pm 2^\circ\text{C}$  in 12h light: 12h dark cycle. Free access of water and standard diet composed of 50% ground, barely, 20% ground yellow maize, 20% milk and 10% vegetables were supplied. Mating was achieved by housing the females with the males at a ratio of one male with two females overnight. Females were checked daily in the morning for the presence of a copulatory plug and the presence of sperms in unstained native vaginal smears. The day at which vaginal smear was positive has been considered as the day zero of pregnancy. Injection started from GD 11 and ended at GD 16. Time differences among all groups, day 20 was determined as the end point for experimentation.

A total of 24 (16 females + 8 males) rats were used for the present study The pregnant rats were divided equally (4 in each group) into four groups as follows

1. Control, administrated distilled water.
2. Curcumin, given oral administration of curcumin (15.75 mg/kg).
3. Betamethasone, given subcutaneous administration of betamethasone (0.1 mg/kg).
4. Betamethasone and curcumin, received subcutaneous administration of betamethasone first followed by oral administration of curcumin one hour later.

On the GD 20, the pregnant rats were anaesthetized using ether and then sacrificed. Fetuses were removed individually from each horn and living fetuses were anaesthetized by ether and dissected to remove the adrenal gland. A total of 73 fetuses were produced and subjected to investigation.

### Betamethasone administration

Betasone tablets (each tablet contains Betamethasone 0.5 mg) was manufactured in Memphis Company for pharmaceutical and

chemical industries, Cairo, Egypt and purchased from pharmacy in Shebeen El-Koom, Menoufiya. The tablets were ground and dissolved in distilled water and subcutaneously administrated at a dose of 0.1mg/kg body weight.<sup>[33]</sup>

### Water extraction of curcumin

Dry turmeric rhizomes of the plant *Curcuma longa* were purchased from a local market at Shebeen El-Koom, Menoufiya, Egypt. One-kilogram fresh *Curcuma longa* were crushed into powder, macerated in distilled water, filtered and orally given daily, as mentioned, at a dose of 15.75 mg/kg body weight.<sup>[34]</sup>

### Investigated parameters

#### A- Histological investigation

Specimens of fetal adrenal gland of both control and experimental groups were proceeded according to for both histological and ultrastructural investigations. Briefly, adrenal glands were separated and immediately fixed for 4 hours at room temperature in 2.5% Glutaraldehyde and 2% paraformaldehyde in 0.1 cacodylate buffer (PH. 7.4) After rinsing in cacodylate buffer, samples were post fixed in buffered solution of 1% osmium tetra-oxide for three hours at 4°C. This was followed by dehydration in ascending grades of ethanol and embedded in epoxyresin. Semi-thin sections of 1µm thickness stained with Toluidine blue were produced for light microscopical examination.

#### B- Immuno-histochemical examination

Avidin-biotin peroxidase method was used for the immuno-histochemical demonstration of the anti-apoptotic mediator Bcl-2 and proapoptotic antigen Caspase-3. The expression of the anti-apoptotic mediator Bcl-2 and the pro-apoptotic antigen Caspase-3 as an indicator for the occurrence of apoptosis were adopted.<sup>[35]</sup> The criterion for a positive reaction is a dark, brownish, The expression of the anti-apoptotic mediator Bcl-2 and the pro-apoptotic antigen Caspase-3 as an indicator for the occurrence of apoptosis were adopted.<sup>[35]</sup> The criterion for a positive reaction is a dark, brownish intracytoplasmic precipitate. For the negative control, the primary antibody was omitted to guard against any false positive results that might develop from a non-specific reaction. Negative control sections were produced by substituting the primary antibodies of Bcl-2 and Caspase3 by normal goat serum. All stained slides were viewed using Olympus microscope and images were captured by a digital camera (Canon Power Shot

A620). Digital images were analyzed by a semi-quantitative scoring system (Fiji-Image J software, Java based application for analyzing images).<sup>[37]</sup>

#### C- Ultrastructural investigation

For ultrastructural investigation which has been done using transmission electron microscope (TEM), after producing the semi-thin sections for histological investigation, Ultra-thin (50 nm) sections were cut, mounted on formvar-coated grids and stained with uranyl acetate for 10 minutes. Sections were then stained with freshly prepared lead citrate for 10 minutes and washed with distilled water. Examination of grids was done by using JEOL electron microscope. Selected sites were digitally photographed.

#### D- Data evaluation and statistical analysis

All data sets were expressed as mean  $\pm$  standard error of the mean (SEM). The statistical data were based on at least 6 adrenals in each group. The data were analyzed statistically for normal distribution (student's T test) and homogeneity of variances (Levene test) using statistical package of social sciences (SPSS) software for windows, version 22. Differences were considered insignificant whenever  $P > 0.05$ . The significances of the obtained data were classified into two categories, i.e.  $P < 0.0001$  and  $P < 0.05$  according to P values.

## RESULTS

### Histological observation

#### Control group

The fetal adrenal gland was consisted of well-developed cortical and medullary cells like that of adult but zonation was far less distinct. While the ZG and ZF were fairly well delineated, the ZR was poorly defined as was the medulla which was not yet fully formed. The adrenal gland was surrounded by a thin connective tissue capsule followed by the ZG which consisted of clusters of small cells. The region lying beneath the ZG was the ZF, which consisted of large cells arranged in cords and separated by blood sinusoids. The innermost region of the gland was consisted of an intermingling large cells of the future ZR with cells of the undeveloped medulla. Medullary cells were diffusely organized. Islands of medullary cells were often more closely associated with adrenocortical cells. The cells were partly arranged in a net-like structure, and were small with little cytoplasm (Fig. 1A).

#### Curcumin group

The light microscopic examination of sections of the curcumin group revealed normal histological

architecture of the cortical and medullary cells as control group (Fig. 1B).

#### Betamethasone group

In the betamethasone injected group, there was a notable disorganization of the cortical cells. The majority showed striking changes in the form of swelling with vacuolated cytoplasm and pyknotic

nuclei. Hemorrhage and dilatation of blood sinusoids were also evident (Fig. 1C, D & E).

#### Betamethasone + curcumin group

Examination of sections from betamethasone and curcumin injected group revealed that most of the cortical and medullary cells displayed almost normal histological structure. However, a few cortical cells were swollen (Fig. 1F).

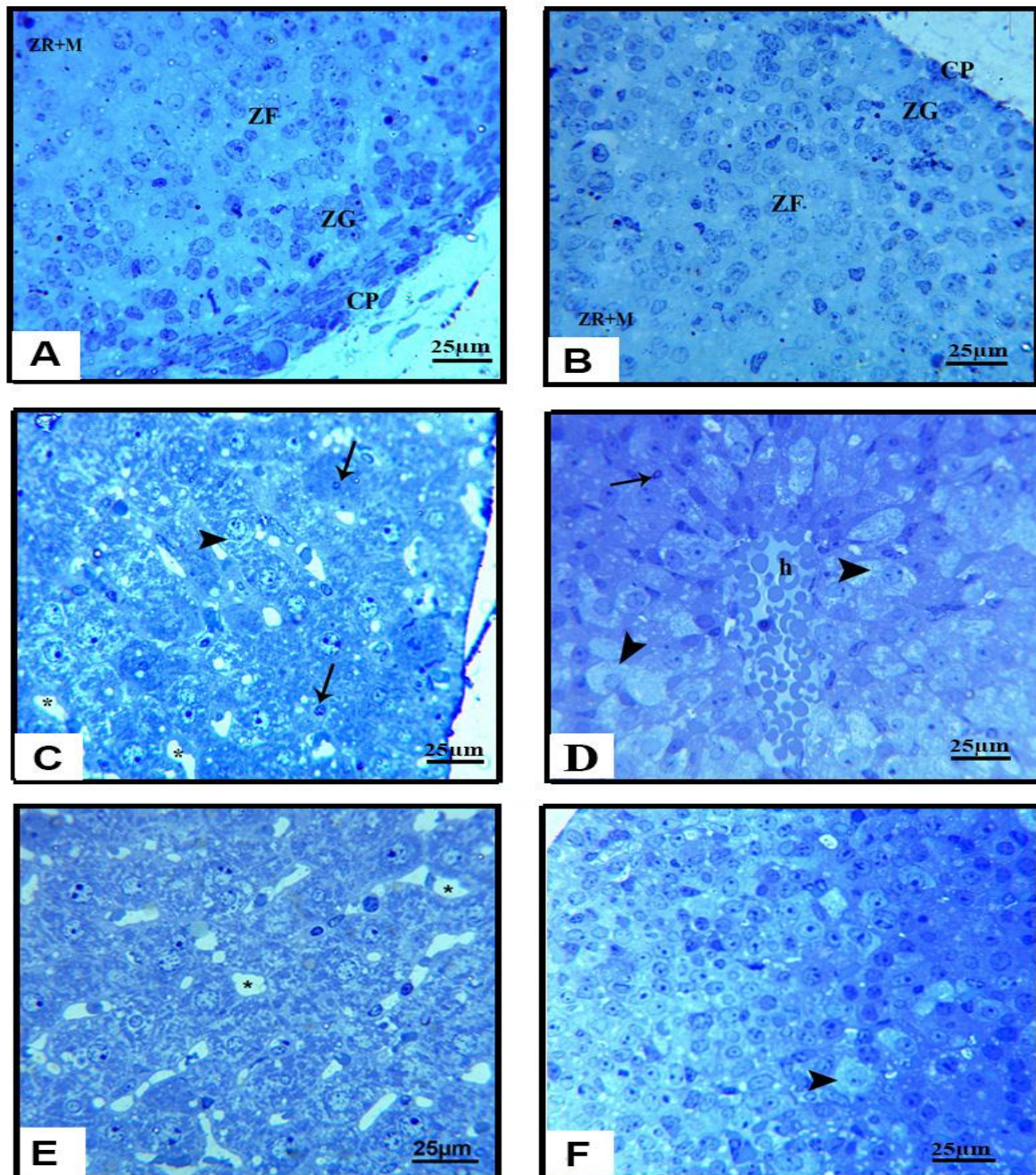
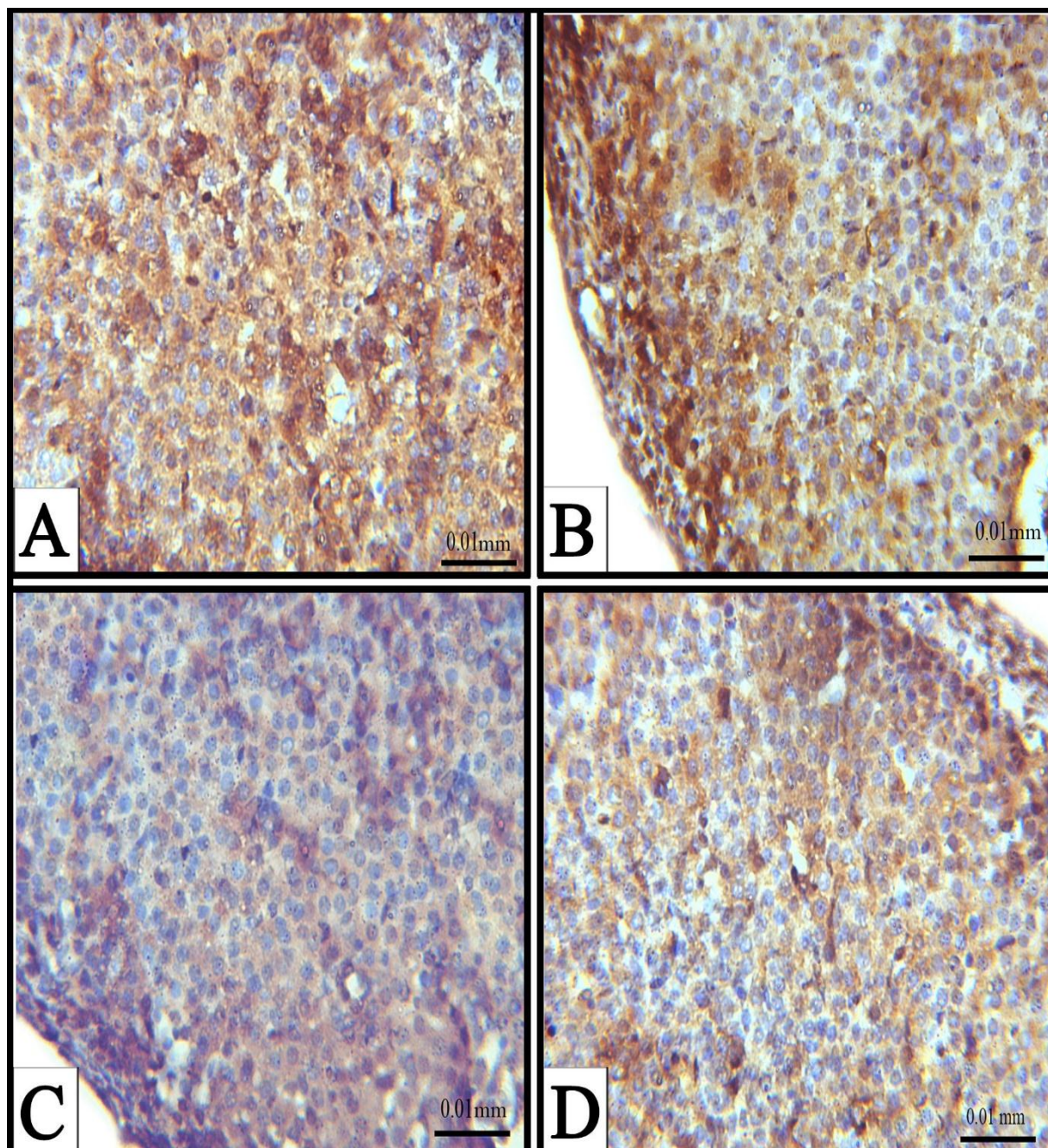


Figure (1): Photomicrographs of semi-thin sections in the fetal adrenal gland of both control and experimental groups, (A) Control, (B) Curcumin, (C, D & E) Betamethasone, (F) Betamethasone + Curcumin group, Capsule (CP), Zona glomerulosa (ZG) Zona fasciculata (ZF) Zona reticularis + Medulla (ZR+M), hemorrhage (h), Sinusoids (\*), Vacuolated cortical cells (Arrow head), pyknotic nuclei (Arrow).

### Immuno-histochemical observation

As Fig. 2 and Table 1 demonstrate, strong immunoreactivity of Bcl-2 was observed in adrenal gland of the fetuses of both control ( $41.60 \pm 0.29$ ) and curcumin ( $40.87 \pm 0.22$ ) group (Fig. 2A & B respectively). However, rat fetuses maternally

injected with betamethasone showed severe decrease in the Bcl-2 immuno-expression ( $8.79 \pm 0.43^{**}$ ) (Fig. 2C). Differently, co-administration of curcumin after betamethasone resulted in very weak expression ( $34.06 \pm 0.37$ ) (Fig. 2D).



**Figure (2):** Photomicrographs showing immuno-histochemical localization of Bcl-2 antigen in the adrenal gland of 20-day old rat fetuses in different groups. A Control, B Curcumin, C Betamethasone and D Betamethasone + Curcumin.

The pattern of Caspase-3 immuno-localization was reversible to that of the Bcl-2 (Table 1). The control ( $8.06 \pm 0.27$ ) and curcumin ( $8.30 \pm 0.56$ ) groups showed weak cytoplasmic expression (Fig. 3 A&B), while betamethasone group displayed very

strong immune-reaction ( $38.25 \pm 0.36$ ) (Fig. 2C). Moderate expression of Caspase-3 antigen was recorded when curcumin was administered after betamethasone injection ( $12.85 \pm 0.35$ ) (Fig. 3D).

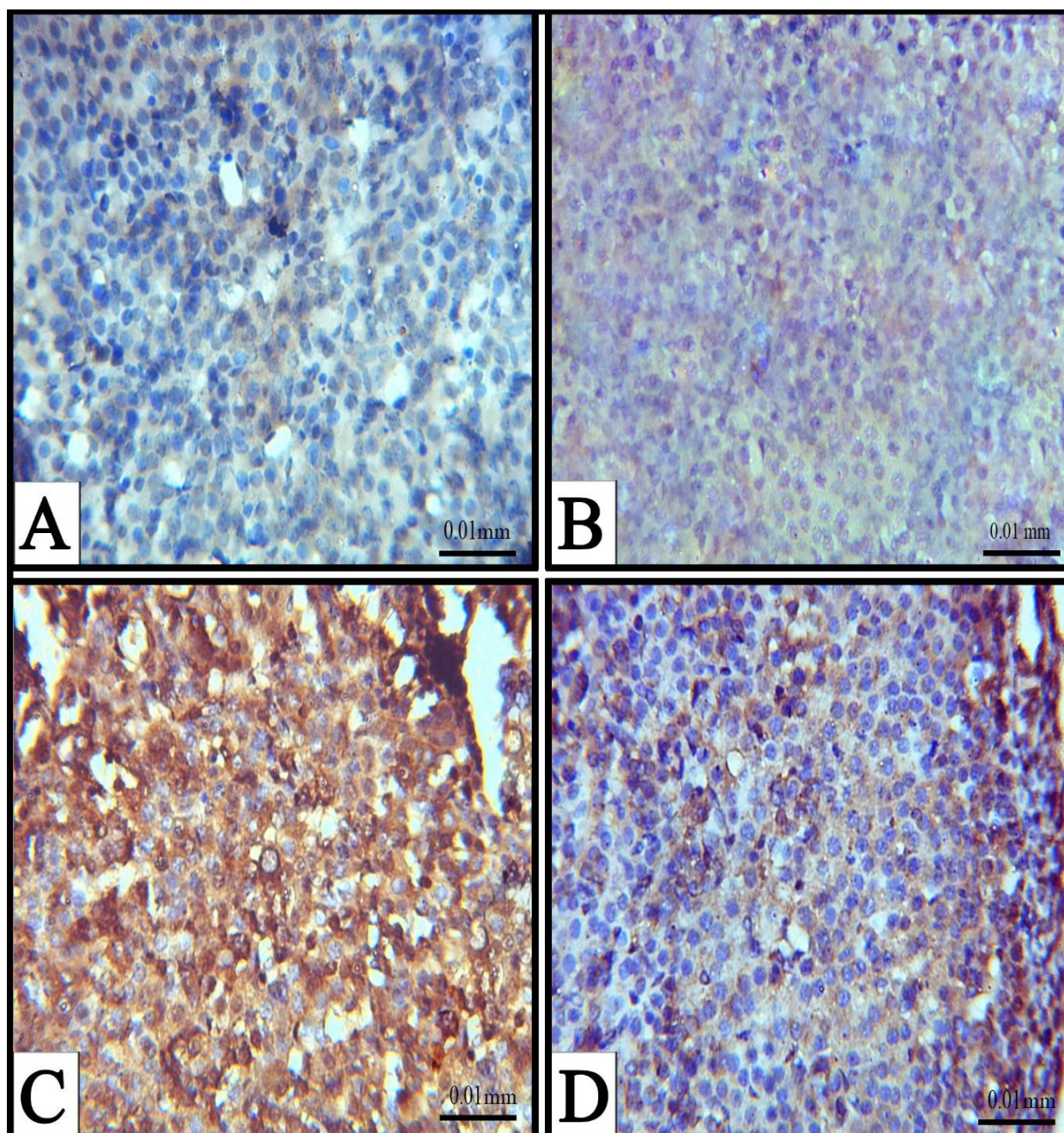


Figure (3): Photomicrographs showing immuno-histochemical localization Caspase-3 antigen in the adrenal gland of rat fetuses in different groups. A Control, B Curcumin, C Betamethasone and D Betamethasone + Curcumin.

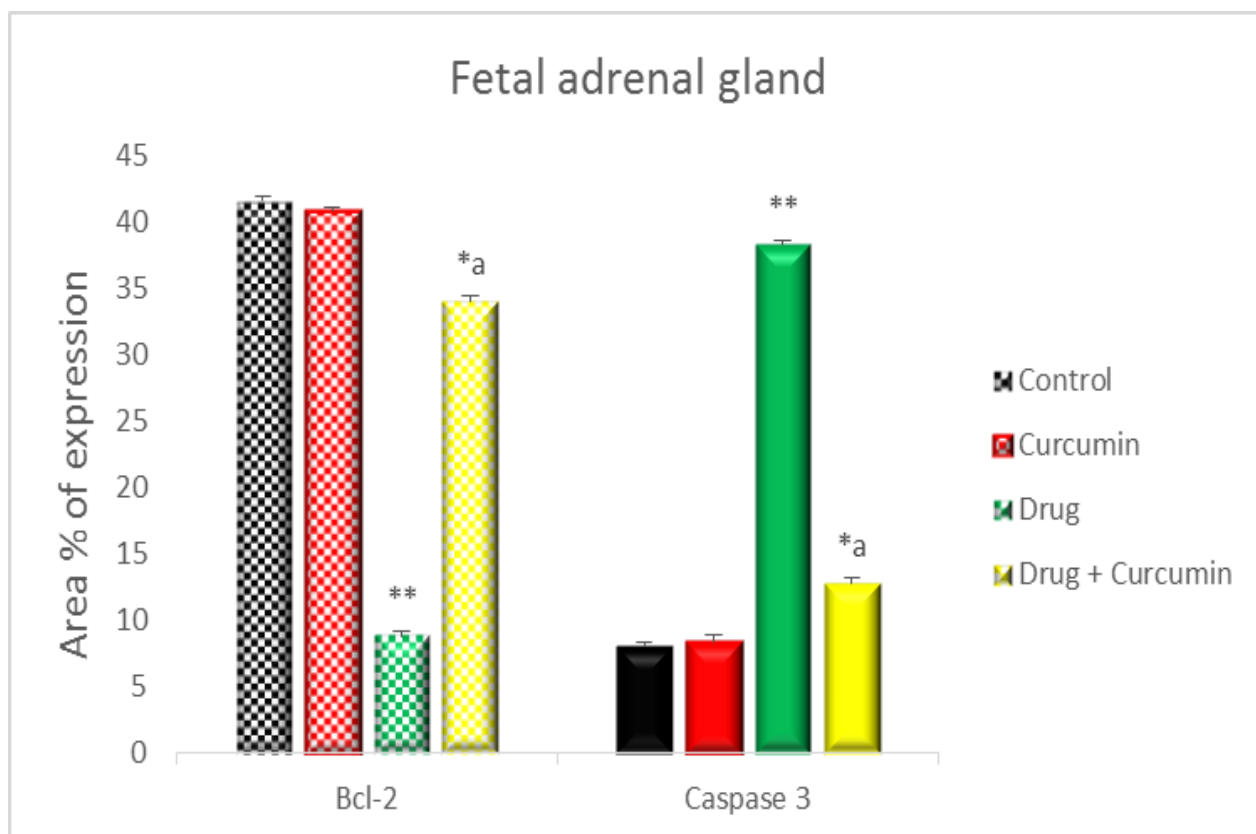
Table 1: The mean area % of Bcl-2 and Caspase-3 expression in the fetal adrenal gland of control and experimental groups.

Groups	Control	Curcumin	Drug	Drug + Curcumin
Bcl-2	41.60 ± 0.29	40.87 ± 0.22	8.79 ± 0.43**	34.06 ± 0.37 <sup>a</sup>
Caspase-3	8.06 ± 0.27	8.30 ± 0.56	38.25 ± 0.36**	12.85 ± 0.35 <sup>a</sup>

Data are represented as mean area % ± SEM.

Asterisks (\* - \*\*) refer to the P value compared with the control group significant differences (\*\* P < 0.0001 & \* P < 0.05) versus control.

a= significant (P < 0.05) compared with betamethasone group.



**Figure (4): Histogram showing percentages of Bcl-2 and Caspase-3 expression (mean  $\pm$  SEM) in the adrenal gland of control and experimental groups. Asterisks indicate the statistically significant differences (\*\*  $P < 0.0001$  & \*  $P < 0.05$ ) versus control.**

a= significant ( $P < 0.05$ ) compared with betamethasone group.

#### Ultrastructure observation

##### Control group

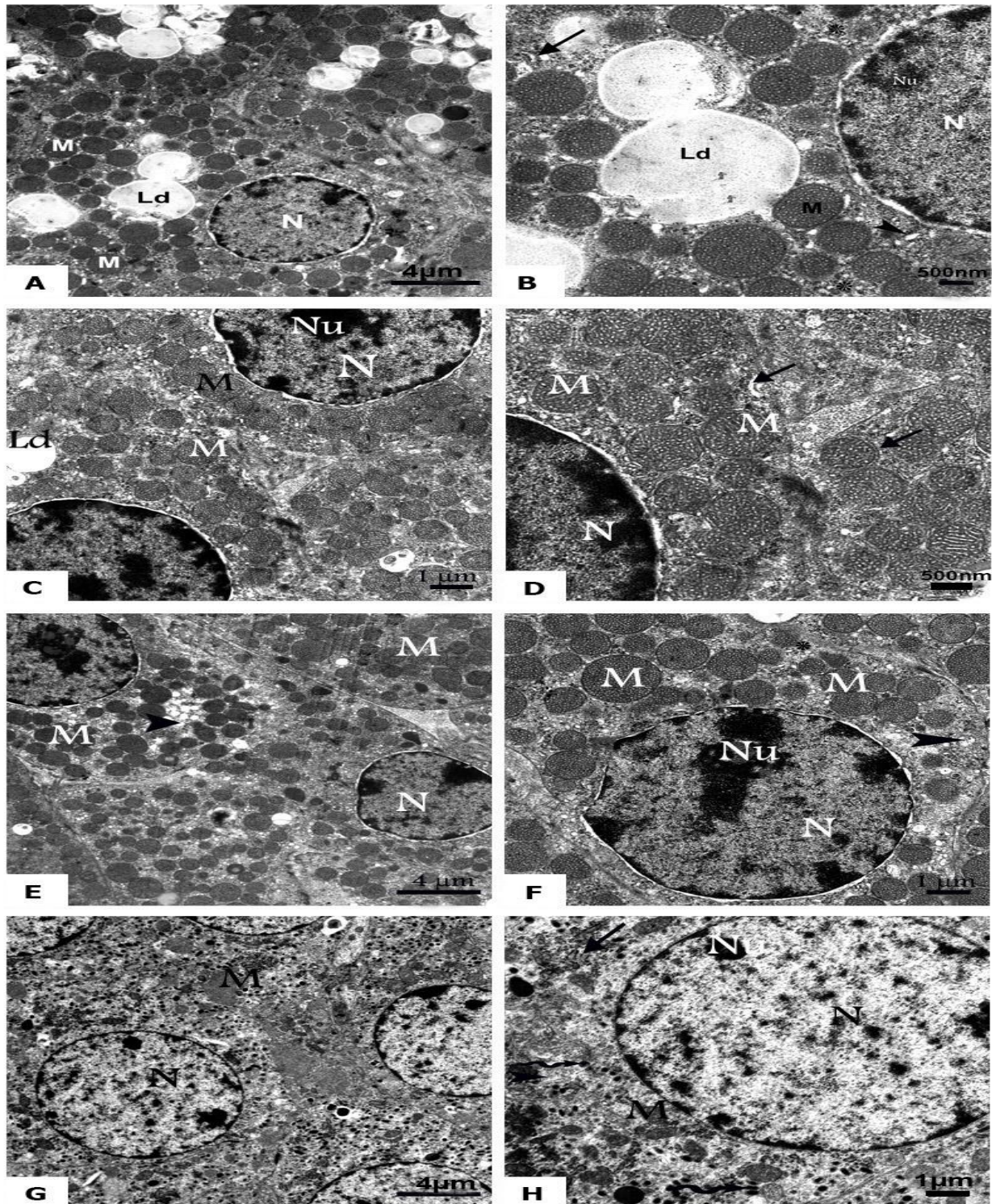
ZG cells were evidently small in size and located immediately adjacent to the capsule. Mitochondria were round or oval and their matrix was relatively electron-dense and contained tubular cristae. Smooth endoplasmic reticulum (SER) profiles were prominent and a few profiles of rough endoplasmic reticulum (RER) were scattered throughout the cytoplasm. Numerous free polyribosomes were dispersed throughout the cytoplasm. The cytoplasm contained a large number of round lipid droplets. The nucleus displayed an irregular round shape uniformly filled with chromatin and a nucleolus (Fig. 5A&B).

Cells of ZF had spherical mitochondria with tubulovesicular cristae which virtually filled the entire matrix. SER cisternae were prominent and scattered throughout the cytoplasm. Elements of the

SER were frequently observed surrounding mitochondria. RER, however, was rarely observed (Fig. 5C&D).

Cells of ZR had spherical nucleus with prominent nucleolus and finely dispersed chromatin. The SER was abundant and frequently observed surrounding the spherical mitochondria. Polyribosomes were well developed and randomly distributed throughout the cytoplasm. Lipid inclusions were observed at random (Fig 5E&F).

The nuclei of the adrenal medulla were round and contain moderate amounts of chromatin. Mitochondria, which were polymorphic in shape and exhibit lamellar cristae, were moderately abundant throughout the cells. SER and RER were randomly distributed throughout the cytoplasm. Polyribosomes were distributed diffusely and membrane-limited granules were numerous in all medulla cells. The cytoplasm contained an electron dense granules (Fig.5G&H).



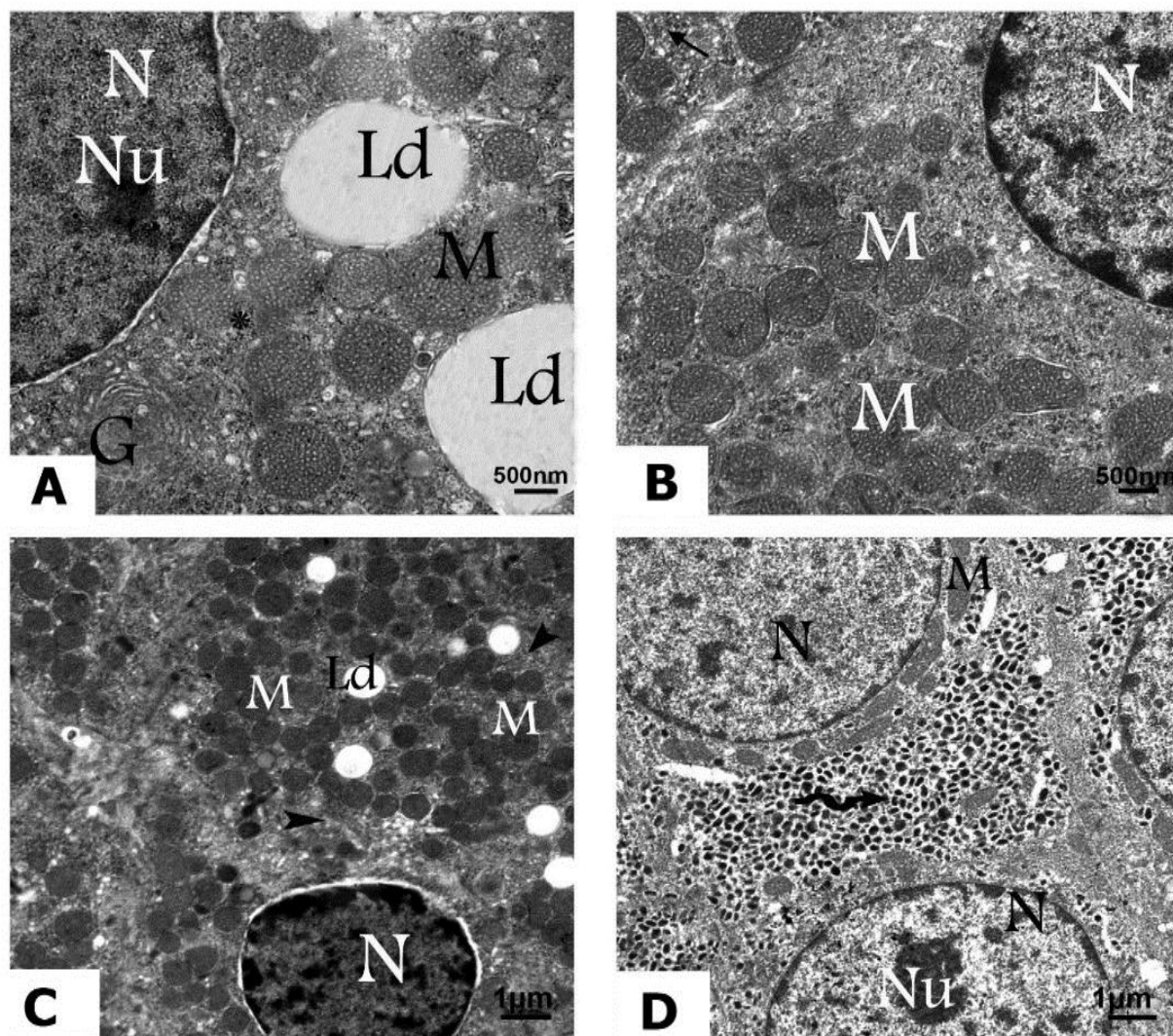
**Figure (5):** TEM Photomicrographs of adrenal gland sections of 20-days old rat fetuses of control group. (A-F) Cells of the adrenal cortex (A&B) from zona glomerulosa (C&D) from zona fasciculata (E&F) from zona reticularis. (G&H) Cells of the adrenal medulla. (N) nucleus, (Nu) Nucleolus, (M) Mitochondria, (Ld) Lipid droplet, (Arrow), RER, (Arrow head) SER, (\*) Polyribosomes, (wavy Arrow) Electron dense granules.

#### **Curcumin group**

The fetal adrenal gland of the curcumin group exhibited no apparent alternations in the structure of the cells of ZG (Fig. 6A), ZF (Fig 6B), ZR (Fig 6C)

or of medullary cells (Fig. 6D). The general arrangement, distribution, the cytoplasmic organelles and inclusions were similar to that of the control group.





**Figure (6): TEM Photomicrographs of adrenal gland sections of 20-days old rat fetuses of Curcumin group. (A) zona glomerulosa cell, (B) Zona fasciculata cell, (C) Zona reticularis cell, (D) Medullary cells (N) nucleus, (G) Golgi apparatus, (Nu) Nucleolus, (M) Mitochondria, (Ld) Lipid droplet, (Arrow), RER, (Arrow head) SER, (\*) Polyribosomes, (wavy Arrow) Electron dense granules.**

#### **Betamethasone group**

Numerous cells with signs of different degenerative stages were found in the cortical cells. The ZG cells displayed a marked increase in lipid deposition throughout the cytoplasm (Fig. 7A). Some cells had pyknotic and shrunken nuclei with condensed peripheral heterochromatin. Degenerated and vacuolated mitochondria with a progressive loss of their cristae were all seen with dilated SER (Fig. 7B&C). Mitochondria with lipid like inclusions and penetration of mitochondria into lipid droplets to form “myelin-like” structures were also observed in many cells (Fig. 7C).

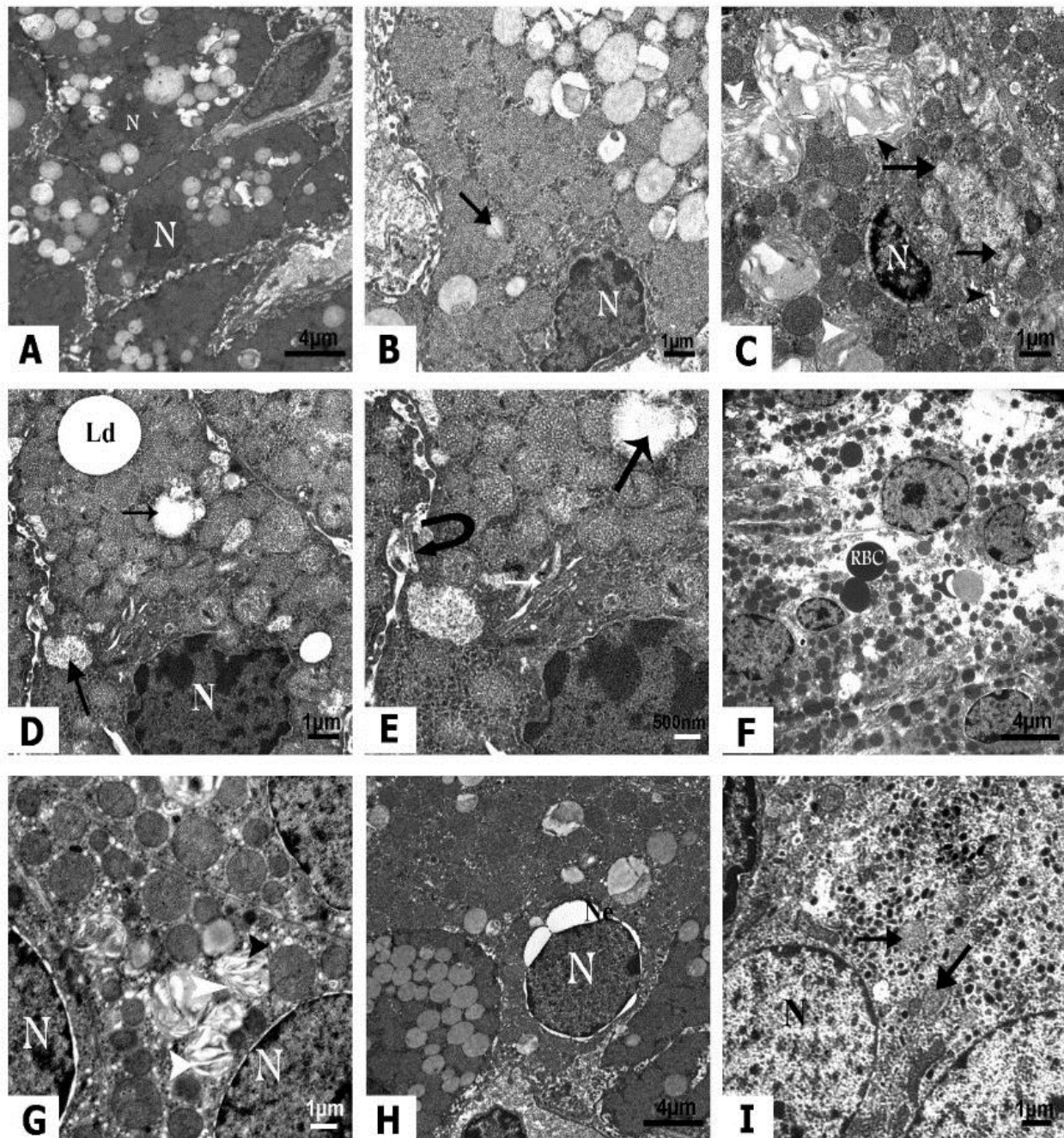
Cells of ZF had swollen mitochondria with accumulation of large sized lipid droplets (Fig. 7D). Nuclei with irregular nuclear envelope and pyknotic

nuclei and dilated Golgi were observed. Widening in the cellular junction appeared between the cells (Fig. 7D&E). In addition, necrotic cells in various stages of degeneration, disruption of cellular membranes, and resorption zones with the presence of hemorrhage were also observed (Fig. 7F).

The most characterized observation in the ZR cells was dilation of the endoplasmic reticulum and the presence of “myelin-like” structures. Other mitochondria whose structure was not as clearly defined were also observed. Mitochondria with lipid like inclusions were observed in other cells. Pyknotic and irregular nuclei were observed between the cells of ZR. Some nuclei showed blebbing in their nuclear envelopes (Fig. 7G&H).

The medullary cells contained ovoid nuclei with irregularly dispersed chromatin. The cells appeared less affected than the cortical cells. The cytoplasm contained large number of electron-dense granules

surrounded by a single membrane. The cellular organelles appeared more or less normal in the structure. Some degenerated mitochondria were also seen (Fig. 7I).



**Figure (7):** TEM Photomicrographs of adrenal gland sections of 20-days old rat fetuses of Betamethasone group. (A-C) zona glomerulosa cells, (D-F) Zona fasciculata cells, (G&H) Zona reticularis cells, (I) Medullary cells (N) nucleus, (G) Golgi apparatus, (Ld) Lipid droplet, (Black Arrow), degenerated mitochondria, (Black Arrow head) dilated smooth Endoplasmic reticulum, (White Arrow head) myelin-like” structures, (curved Arrow) Widening of the cellular junction, (White Arrow) dilated Golgi, (RBC) Red blood cell, (Ne) Nuclear envelop.

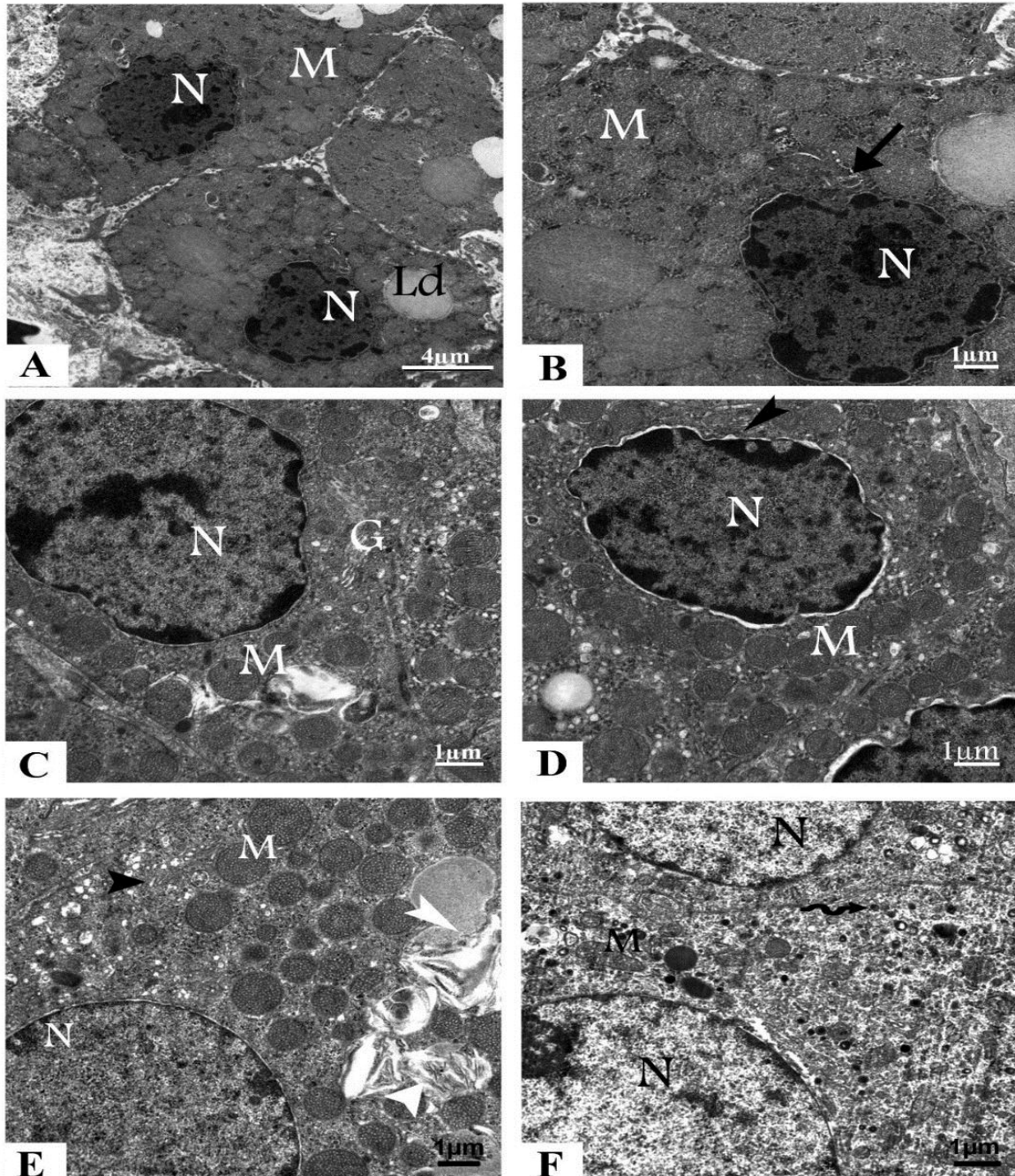
#### **Betamethasone + curcumin group**

Ultrastructural examination of the adrenal cells of the combined group showed a nearly normal

structure compared with the betamethasone group. The cells of ZG displayed irregular euchromatic nuclei with a prominent nucleolus and a few lipid

droplets. The mitochondria and the SER appeared more or less normal in shape and size (Fig. 8A&B). Cells of ZF showed euchromatic nuclei with prominent nucleolus and irregular nuclear envelop. Mitochondria were spherical and variable in size with densely packed vesicular cristae. Golgi apparatus and SER were also seen (Fig. 8C&D). The ZR cells displayed normal rounded nuclei,

numerous spherical mitochondria and SER. However, “myelin-like” structures were also observed (Fig. 8E). The medullary cells showed normal structure compared with the betamethasone group. The cells contain round nuclei, polymorphic mitochondria and few electron dense granules. Numerous membrane limited granules were also scattered in the cytoplasm (Fig. 8F).



**Figure (8):** TEM Photomicrographs of adrenal gland sections of 20-days old rat fetuses of Betamethasone + Curcumin group. (A&B) Zona glomerulosa cells, (C&D) Zona fasciculata cells, (E) Zona reticularis cell, (F) Medullary cells (N) nucleus, (G) Golgi apparatus, (M) Mitochondria, (Ld) Lipid droplet, (Arrow head) smooth Endoplasmic reticulum, (White Arrow head) myelin-like” structures, (wavy Arrow) Electron dense granules.

## DISCUSSION

The development of fetal tissues and organs are dependent on many factors, including the hormonal environment. Endogenous glucocorticoids produced by the fetal adrenal glands have a crucial role in these processes and exert beneficial effects on the development and maturation where glucocorticoid receptors have been located. Under normal circumstances, glucocorticoid levels are significantly lower in the fetus than in the mother.<sup>[5]</sup> It has been reported that the prenatal treatment with synthetic glucocorticoids may expose the fetus to inappropriately high levels of glucocorticoids, which leads to reduced fetal growth and at the same time increases the risks of dysregulation of the metabolic function and endocrine axes, including stress response, growth and reproduction.<sup>[38,39]</sup> In our laboratory, exogenous prenatal betamethasone administration was shown to induce destructive changes in both maternal and fetal tissues and the observations were published in a series of papers.<sup>[29,30,31]</sup> The aim of the present study was to investigate the effects of exogenous betamethasone maternally administered on the adrenal gland of the rat fetuses. It focused on the histological, immunohistochemical, and ultrastructural alterations and the possible ameliorative effect of curcumin administration. The outcome of the three approaches indicates that betamethasone (0.1mg/kg body weight) injected daily into pregnant rats starting from GD 11 and ending at GD 16 leads to destructive changes in the adrenal gland of the fetuses.

The two main apoptotic pathways within a cell are the extrinsic (receptor pathway) and the intrinsic (mitochondrial pathway). The latter pathway is triggered by many intrinsic signals including oxidative stress.<sup>[40]</sup> Caspase-3 is activated by both extrinsic and intrinsic pathways, so it is used as pro-apoptotic marker while Bcl-2 is used as an anti-apoptotic marker. The upregulation and consequently increased expression of the Caspase-3 in the adrenal gland of fetuses in the betamethasone group indicating programmed cell death. The anti-apoptotic marker Bcl-2 on the other hand displayed downregulation and hence decrease expression. This is in agreement with many studies which revealed that Caspase-3 immuno-reaction was increased by apoptosis.<sup>[41]</sup> In addition, previous study showed that maternal treatment with prednisolone increases adrenocortical apoptosis.<sup>[42]</sup>

At the present ultrastructural level, alterations were observed in the cortical and medullary cells of the

fetal adrenal gland. The majority of the cortical cells i.e., ZG, ZF and ZR of the fetuses maternally treated by betamethasone displayed destructive changes. The latter included marked increase in lipid deposition degenerated and vacuolated mitochondria with a progressive loss of cristae. Other destructive changes included the presence of "myelin-like" structures, pyknotic and shrunken nuclei, dilated SER and Golgi apparatus and hemorrhage.

Christi *et al.*,<sup>[43,44]</sup> showed that administration of a single dose of dexamethasone to pregnant rats on GD 16 leads to marked atrophic changes and suppression of the function of the fetal adrenal glands. On the other hand, prolonged treatment of pregnant rats with dexamethasone in the period when intensive differentiation of the fetal hypothalamo-hypophyseal system takes place inhibits proliferative activity of adrenocortical cells and evokes considerable atrophic changes in the adrenal glands of offspring. Another study by Ricciardi *et al.*<sup>[45]</sup> who demonstrated that dexamethasone injection to neonatal rats can decrease the width of the ZF and the ZR, increase the lipid content, and cause degenerative mitochondrial signs in the ZG. In adult animal's adrenal atrophy was expressed mainly as a lowering of the average cell volume, reduction in number and volume of cell organelles involved in steroidogenesis and as inhibition of proliferative activity of adrenocortical cells.<sup>[46,47]</sup>

Atrophic changes in the adrenal cells are likely the consequences of strong inhibition from fetal adrenocorticotropin (ACTH) secretion. The fetal hypophysis is essential for normal differentiation of the adrenal cortex.<sup>[48]</sup> In rat, hypophyseal adrenocorticotropin hormone (ACTH) production begins on day 14 of fetal life.<sup>[49,50]</sup> Synthetic glucocorticoids administered to pregnant rats crosses the placental barrier, enters the fetal circulation and inhibits fetal ACTH secretion.<sup>[51]</sup> The deprivation of ACTH also stimulates apoptosis in the adrenal cortex in neonatal.<sup>[52]</sup> This process is most prominent in the inner cortical zones, particularly in the ZF.

In the cortical cells of fetus rat, accumulation of lipid droplets, as a sign of inhibited steroidogenesis, was detected.<sup>[46]</sup> This was also constant with the data of previous researchers who noticed accumulation of lipid droplets in the cells of the ZF and ZR after suppression of steroidogenesis via dexamethasone administration.<sup>[53]</sup> Recent study by

Khalaf et al.,<sup>[54]</sup> revealed that accumulation of lipid droplets and appearance of cytoplasmic vacuolation in the ZF cells after treatment with nicotine may be due to the impairment in the synthesis of glucocorticoids. As the ZF is responsible for synthesis and secretion of glucocorticoids, the disrupted steroidogenesis had a vital role in the toxicity of the adrenal cortex. This may occur as a result of disruption of cytochrome P450 enzymes; therefore, cholesterol biosynthesis will be inhibited. This will lead to accumulation of lipid droplets and cytoplasmic vacuolation of the ZF cells.<sup>[55]</sup>

Elshennawy and Aboelwafa.<sup>[55]</sup> stated that the swelling and vacuolation of the mitochondria in the ZF cells possibly resulted from the suppression of cholesterol to pregnenolone conversion. As the mitochondria and SER play important roles in steroidogenesis, the lesions detected in them were sufficient to inhibit steroid synthesis, leading to further accumulation of cholesterol in the mitochondria.

Curcumin has attracted increasing attention for the treatment of a range of conditions. It has a protective action on many disorders of the body, so it is considered as a promising source of protection against these disorders.<sup>[17,56,57]</sup> Investigations into the pharmacodynamics of curcumin have consistently demonstrated it to be a potent antioxidant,<sup>[58,59]</sup> at least ten times more active as an antioxidant than vitamin E.<sup>[58]</sup> Also previous studies have demonstrated the ameliorative role of curcumin against betamethasone maternal and fetal toxicity during pregnancy.<sup>[29,30,31]</sup> In addition, Abdel-Aziz and Ahmed<sup>[60]</sup> demonstrated that curcumin administration has protective effect on the cells of the adrenal medulla against the toxicity of nicotine. A few studies have examined the effect of curcumin in regulating HPA disturbances, namely its effect in moderating the hypersecretion of corticosterone and subsequent neuroprotection.<sup>[61,62]</sup> The experimental group which was injected with betamethasone followed by curcumin, the adrenal cells displayed a nearly normal structure compared with the control group. However, few mitochondria with lipid like inclusions and penetration of mitochondria into lipid droplets to form “myelin-like” structures were also observed in the ZR cells.

Based on the outcome of the present study, it can be concluded that prenatal betamethasone administration has enormous destructive effects on both the structure and fine structure of the developing adrenal gland. Therefore, it is highly

recommended that its use must be restricted to the urgent necessity and in such case, curcumin as a potent antioxidant, can be utilized to ameliorate these adverse effects.

## REFERENCES

1. Mitanni F, Mukai K, Miyamoto H, Sue Matsu M, Ishimura Y. Development of functional zonation in the rat adrenal cortex. *Endocrinology*, 1999; 140: 3342-53.
2. Xing Y, Lerario A, Rainey W, Hammer G. Development of Adrenal Cortex Zonation. *Endocrinol Metab Clin North Am*. 2015; 44(2): 243-74.
3. Yamamoto M, Yanai R, Arishima K. Study of migration of neural crest cells to adrenal medulla by three-dimensional reconstruction. *J Vet Med Sci.*, 2004; 66(6): 635-41.
4. Pepe G, Albrecht E. Regulation of the primate fetal adrenal cortex. *Endocrine Reviews*. 1990; 11(1): 151-76.
5. Manojlović-Stojanoski M, Ristić N, Singh S, Milošević V. Antenatal Treatment with Glucocorticoids and the Hypothalamic-Pituitary-Adrenal Axis. *J Med Biochem.*, 2014; 33: 307-16.
6. Sloboda D, Challis J, Moss T, Newnham J. Synthetic glucocorticoids: antenatal administration and long-term implications. *Curr Pharm Des.*, 2005; 11(11): 1459-72.
7. Challis J, Sloboda D, Matthews S, Holloway A, Alfaidy N, Patel F, Whittle W, Fraser M, Moss T, Newnham J. The fetal placental hypothalamic-pituitary-adrenal (HPA) axis, parturition and post-natal health. *Mol Cell Endocrinol.*, 2001; 185: 135-44.
8. Agnew E, Ivy J, Stock S, Chapman K. Glucocorticoids, antenatal corticosteroid therapy and fetal heart maturation. *J Mol Endocrinol.*, 2018; 61(1): R61-R73.
9. Burton P, Waddell B. Dual function of 11hydroxysteroid dehydrogenase in placenta: modulating placental glucocorticoid passage and local steroid action. *Biology of Reproduction*, 1999; 60: 234-40.
10. Seckl J. Prenatal glucocorticoids and long-term programming. *Eur J Endocrinol.*, 2004; 151 Suppl 3: U49-62.
11. Fowden A, Forhead A. Glucocorticoids as regulatory signals during intrauterine development. *Experimental Physiology*, 2015; 100: 1477-87.
12. Moisiadis V, Matthews S. Glucocorticoids and fetal programming part1: outcomes. *Nat Rev Endocrinol.*, 2014; 10(7): 391-402.

13. Jellyman J, Valenzuela O, Fowden A. Glucocorticoid programming of the hypothalamic-pituitary-adrenal axis and metabolic function: Animal studies from mouse to horse. *J Anim Sci.*, 2015; 93: 1-16.
14. Fowden A, Forhead A. Endocrine regulation of foeto-placental growth. *Horm Res.*, 2009; 72(5): 257-65.
15. Ostrea E, Mantaring J, Silvestre M. Drugs that affect the fetus and newborn infant via the placenta or breast milk. *Pediatr Clin North Am.*, 2004; 51(3): 539-79.
16. Feldman D, Carbone J, Belden L, Borgida A, Herson V. Betamethasone vs dexamethasone for the prevention of morbidity in very-low-birth weight neonates. *Am J Obstet Gynecol.*, 2007; 197(3): 284.e1-4.
17. Akram M, Uddin S, Ahmed A, Usmanghan K, Abdul Hannan A, Mohiuddin E, Asif M. *Curcuma longa* and curcumin: A review article. *Rom J Biol - Plant Biol.*, 2010; 55(2): 65-70.
18. Quiles J, Mesa D, Ramirez-Tortosa C, Aguilere C, Battino M, Gil A, Ramirez-Tortosa M. *Curcuma longa* extract supplementation reduces oxidative stress and attenuates aortic fatty streak development in rabbits. *Arterioscler Thromb Vasc Biol.*, 2002; 22(7): 1225-31.
19. Agarwal R, Goel S, Behari J. Detoxification and antioxidant effects of curcumin in rats experimentally exposed to mercury. *J Appl Toxicol.*, 2010; 30(5): 457-68.
20. Sharma R, Steward W, Gesher A. Pharmacokinetics and pharmacodynamics of curcumin. *Adv Exp Med Biol.*, 2007; 595: 453-70.
21. Johnson S, Gulhati P, Arrieta I, Wang X, Uchida T, Gao T, Evers B. Curcumin inhibits proliferation of colorectal carcinoma by modulating Act/mTOR signaling. *Anticancer Res.*, 2009; 29: 3185-90.
22. Bagchi A, Mukherjee P, Bhowmick S, Raha A. Synthesis, characterization and antibacterial activity of a novel curcumin metal complex. *Int J Drug Dev Res.*, 2015; 7(2): 011-014.
23. Qasem M, Alhadj M, El Nabi G, Al-Mufarrej S. Effects of turmeric powder as a dietary supplement on performance indicators and immune responses in broiler chickens. *J Animal Vet Adv.*, 2015; 14(2): 30-5.
24. Nisar T, Iqbal M, Raza A, Safdar M, Iftikhar F, Waheed M. Turmeric: A promising spice for phytochemical and antimicrobial activities. *Am Eur J Agric Environ Sci.*, 2015; 15(7): 1278-88.
25. Othman A, Hussein M. In vitro Antibacterial, antioxidant and hepatoprotective effect of curcumin-zinc oxide nano-particles in combination. *Int J Pharm Bio Sci.*, 2015; 6(4): 105-18.
26. Soto-Urquieta M, López-Briones S, Pérez-Vázquez V, Saavedra Molina A, González-Hernández G, Ramírez-Emiliano J. Curcumin restores mitochondrial functions and decreases lipid peroxidation in liver and kidneys of diabetic db/db mice. *Biol Res.*, 2014; 47(1): 1-8.
27. Manogaran E, Ramanathan M, RamaRao T. Neuroprotective effect of curcumin against cholesterol induced neuro-inflammation *in-vitro* and *in-vivo* Models. *J Pharm Sci Res.*, 2015; 7(4): 189-96.
28. Varatharajalu R, Garige M, Leckey L, Reyes-Gordillo K, Shah R, Lakshman R. Protective role of dietary curcumin in the prevention of the oxidative stress induced by chronic alcohol with respect to hepatic injury and antiatherogenic markers. *Oxid Med Cell Longev.*, 2016; 2016: 1-10.
29. Badawy G, Saker S, El- Borm H. The ameliorative role of curcumin administration against betamethasone- induced maternal and fetal hepatotoxicity in rats. *JBSAR*, 2017; 2(3): 118 -30.
30. Badawy G, Saker S, El- Borm H. Ameliorative effects of curcumin on betamethasone- induced maternal and fetal nephrotoxicity in rats. *EJPMR*, 2016; 6(3): 123 - 36.
31. Badawy G, Sakr S, El- Borm H. The ameliorative role of curcumin on the morphological and skeletal malformations induced by betamethasone in rat fetuses. *Egypt. J. Exp. Biol. (Zool.)*, 2018; 14(1): 53 – 68.
32. Kota S, Gayatri K, Jammula S, Meher L, Kota S, Krishna S, Modi K. Fetal endocrinology. *Indian J Endocrinol Metab.*, 2013; 17(4): 568-79.
33. Cibele S, Borgesa C, Dias Am Rosa J, Silva P, Silva R, Barros A, Sanabria M, Guerraa M, Gregory M, Cyr D, Kempinasa W. Alterations in male rats following in utero exposure to betamethasone suggests changes in reproductive programming. *Rep. Toxicol.*, 2016; 63: 125-134.
34. Hashem M, Atta A, Arbid M, Nada S, Mounir S, Assad G. Toxicological impact of Amaranth, sunset yellow and curcumin as food coloring agents in albino rats. *JPMS.*, 2011; 1(2): 43-51.

35. Sternberger L. *Immuno-cytochemistry*. 3<sup>rd</sup> ed., John Wiley Medical, New York, 2006; 190-209.
36. Schindelin J, Arganda-Carreras I, Frise E, Kaynig V, Longair M, Pietzsch T, Preibisch S, Rueden C, Saalfeld S, Schmid B, Tinevez J, White D, Hartenstein V, Eliceiri K, Tomancak P, Cardona A. Fiji: an open-source platform for biological-image analysis. *Nature Methods*, 2012; 9: 676-82.
37. Karnovsky M. A formaldehyde - glutaraldehyde fixative of high osmolarity for use in electron microscopy. *J Cell Biol.*, 1965; 127-37.
38. Kurtoğlu S, Sarıcı D, Akin M, Daar G, Korkmaz L, Memur Ş. Fetal adrenal suppression due to maternal corticosteroid use: case report. *J Clin Res Pediatr Endocrinol.*, 2011; 3(3): 160-2.
39. Manojlović-Stojanoski M, Nestorović N, Ristić N, Trifunović S, Ajdžanović V, Sošić-Jurjević B, Milošević V. Pregnancy reduces the responsiveness of the pituitary-adrenal axis to dexamethasone. *Acta Histochem.*, 2012; 114(6): 562-70.
40. Green D, Kroemer G. The pathophysiology of mitochondrial cell death. *Science*, 2004; 30: 626-9.
41. Luiz F, Camila R, Carla C, Ricardo S, Maria C, José M, et al. Melatonin action in apoptosis and vascular endothelial growth factor in adrenal cortex of pinealectomized female rats. *Rev Bras Ginecol Obstet.*, 2010; 32(8): 374-80.
42. Wyllie A, Kerr J, Currie A. Cell death in the normal neonatal rat adrenal cortex. *J. Pathol.*, 1973; 111: 255-61.
43. Hristic N, Kalafatic D, Plecas B, Manojlovic M. The effect of dexamethasone on the adrenal gland in fetal and neonatal rats. *The Journal of Experimental Zoology*, 1995; 272: 281-90.
44. Hristic N, Kalafatic, D. Plecas, B, Manojlovic M. The influence of Prolonged Dexamethasone Treatment of Pregnant Rats on the Perinatal Development of the Adrenal Gland of Their Offspring. *The Journal of Experimental Zoology*, 1997; 279: 54-81.
45. Ricciardi M, Pellegrini A, Giannessi F. and Paparelli A. Morphological and histochemical study on the adrenal cortex of the dexamethasone-treated albino rat. *Int J Tissue React.*, 1984; 6(4): 333-7.
46. Nussdorfer G. Cytophysiology of the adrenal cortex. *Int. Rev Cytol.*, 1986; 98: 1-405.
47. Lesniewska B, Nowak K, Malendowicz L. Dexamethasone-induced adrenal cortex atrophy and recovery of the gland from partial, steroid induced atrophy *Exp. Clin. Endocrinol.*, 1992; 100: 133-9.
48. Manolović-Stojanoski M, Nestorović N, Negić N, Filipović B, Sošić-Jurjević B, Milošević V, Sekulić M. The pituitary adrenal axis of fetal rats after maternal dexamethasone exposure. *Anat Embryol.*, 2006; 211: 61-9.
49. Stoeckel M, Hindelong C, Klein M, Poissonnier M, Felix J. Early expression of the glycoprotein hormone alpha-subunit in the pars tuberalis of the rat pituitary gland during ontogenesis. *Neuroendocrinology*, 1993; 58: 616-24.
50. Gerginov M. Investigation and validation of animal models for the development of the human fetal and neonatal hypothalamic-pituitary-adrenal axis. A Dissertation Research, Institute of Psychobiology University of Trier, Germany, 2011; 1-247.
51. King M, Baertschi, A. The role of intracellular messengers in adrenocorticotropin secretion in vitro. *Experientia*, 1990; 46: 26-40.
52. Bursch W, Oberhammer F, Schulte-Hermann R. Cell death by apoptosis and its protective role against disease. *Trends Pharmacol. Sci.*, 1992; 13: 245-57.
53. Thomas M, Keramidas M, Monchaux E, Feige J. Dual hormonal regulation of endocrine tissue mass and vasculature by adrenocorticotropin in the adrenal cortex. *Endocrinology*, 2004; 145: 4320-9.
54. Khalaf H, Ghoneima F, Arafat E, Mahmoud E. Histological effect of nicotine on adrenal zona fasciculata and the effect of grape seed extract with or without withdrawal of nicotine. *Journal of Microscopy and Ultrastructure*, 2017; 5: 123-31.
55. Elshennawy W, Aboelwafa R. Structural and ultrastructural alterations in mammalian adrenal cortex under influence of steroidogenesis inhibitors drug. *J Am Sci.*, 2011; 7(8): 567-76.
56. Lopresti A, Hood S, Drummond P. Multiple antidepressant potential modes of action of curcumin: a review of its anti-inflammatory, monoaminergic, antioxidant, immunomodulating and neuroprotective effects. *Journal of Psychopharmacology*, 2012; 26(12): 1512-24.
57. Yan F, Sun J, Xie W, Shen L, Ji H. Neuroprotective Effects and Mechanisms of Curcumin-Cu(II) and -Zn(II) Complexes Systems and Their Pharmacological Implications. *Nutrients*, 2018; 10: 28: 1-11.

58. Ak T, Gulcin I. Antioxidant and radical scavenging properties of curcumin. *Chemico-biological interactions*, 2008; 174: 27-37.
59. Menon V, Sudheer A. Anti-inflammatory and anti-oxidant properties of curcumin. In: Aggarwal B, Surh Y, Shishodia S, (eds), *The Molecular Targets and Therapeutic Uses of Curcumin in Health and Disease*. Springer, 2007; New York.
60. Abdel-Aziz H, Ahmed S. Curcumin Protection against Nicotine Induced Histological Changes of the Chromaffin Cells of Adrenal Medulla in Mice. *Journal of American Science*, 2011; 7(9): 698-703.
61. Li Y, Wang F, Pan Y, Qiang L, Cheng G, Zhang W. et al. Antidepressant-like effects of curcumin on serotonergic receptor-coupled AC-cAMP pathway in chronic unpredictable mild stress of rats. *Progress in Neuro-psychopharmacology & Biological Psychiatry*, 2009; 33: 435-49.
62. Huang Z, Zhong X, Li Z, Feng C, Pan A, Mao Q. Curcumin reverses corticosterone-induced depressive-like behavior and decrease in brain BDNF levels in rats. *Neuroscience Letters*, 2011; 493: 145-8.