

OUR TACTICS IN TREATMENT SLIPPED CAPITAL FEMORAL EPIPHYSIS

*S. S. Kadirov

Specialized Scientific-Practical Center of Traumatology and Orthopedics of Ministry of Health of Uzbekistan.

*Corresponding Author: Dr. S. S. Kadirov

Specialized Scientific-Practical Center of Traumatology and Orthopedics of Ministry of Health of Uzbekistan.

Article Received on 28/06/2019

Article Revised on 18/07/2019

Article Accepted on 07/08/2019

ABSTRACT

Purpose: Slipped capital femoral epiphysis (SCFE) is often treated by surgical fixation; however, no agreement exists regarding technique. We analyzed the outcome of in situ fixation with cannulated screw. **Materials and methods:** The work is based on the results of observation and treatment of 36 patients (48 joints) with different forms of juvenile epiphysiolysis of the femoral head, treated in the specialized scientific - practical center of traumatology and orthopedics from 2011 to 2018. Among these patients there were 75% of boys and 25% of girls aged 11 to 16 years (mean age was 13.5 years). **Results:** The total number of cases of SCFE was 36, half of the children had bilateral SCFE. 2 subjects required additional surgery and mild avascular necrosis of the femoral head was seen in 1 patient. None had slip progression or chondrolysis. **Conclusion:** In situ pinning of SCFE with partly threaded cannulated screw appears to be a feasible and safe method, with few complications. The technique allows further growth of the femoral neck.

KEYWORDS: Slipped capital femoral epiphysis, hip, cannulated screw, epiphysis of femur head, acute, chronic.

INTRODUCTION

Slipped capital femoral epiphysis (SCFE) is one of the most serious diseases of the hip joint. In the absence of early diagnosis and appropriate treatment, SCFE may lead to a significant dysfunction of the hip joint, early development of coxarthrosis and disability.^[1,2,6] As a result of displacement of the epiphysis of the head, cervical-epiphyseal deformity of the proximal femur develops.

To characterize the pathological process, the most commonly used term is the epiphysis dislocation, it is not entirely correct, as the epiphysis is retained in the acetabulum with the help of the ligamentous apparatus, and the metaphysis moves up and out. However, for the convenience of differentiation and characterization of forms of SCFE, it is generally accepted to characterize the change in the position of the epiphysis relative to the thigh, and not vice versa. The pathological process in the paraepiphyseal zone and the metaphyseal region of the femoral neck during the SCFE leads to a disruption of the junction of the epiphysis of the head and the femoral neck and subsequent dislocation of the epiphysis of the femoral head. There is a weakening of the strength properties of the perichondral complex and a decrease in the mineral density of the para-epiphyseal zone of the neck. Under the influence of the load, the posterior epiphysis gradually deviates by the amount of resorption of the dorsal part of the femoral neck. In the tilt position, the epiphysis and cervix are collapsed. The inclination of the epiphysis due to the loss of cervical tissue does not

mean a real displacement and can reach a large extent, due to which the lower pole of the epiphysis can be located close to the intertrochanteral fossa. Such manifestations of the disease are referred to as chronic course (fig.1).

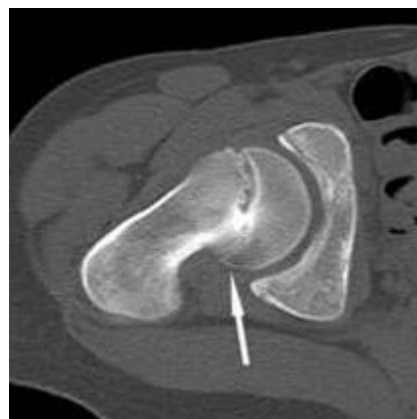


Figure 1: CT scan of SCFE. Chronic form. Deviation of the epiphysis of the head by the magnitude of the resorption of the dorsal, paraepiphyseal part of the cervix. Local synostosis at the level of the germ zone.

The true displacement should be considered as the position of the epiphysis of the femoral head, when it slips off in acute forms. X-ray logically, this movement is characterized by the appearance of "steps" on the ventral side of the neck (Fig. 2). The case of acute displacement of the epiphysis in the presence of cervical

transformation in the posterior sections is classified as "acute to chronic". An important feature of mechanogenesis of the SCFE is to consider it, not simply as the femoral head slipping down and backwards, but as a process of gradual transformation at the level of the paraepiseal zone of the dorsal part of the cervix, the consequence of which is the deviation of the posterior epiphysis and downward. Thus, the slope and slippage of the pineal gland in the SCFE are fundamentally different types of displacement, causing a difference in history, clinical and x-ray manifestations.

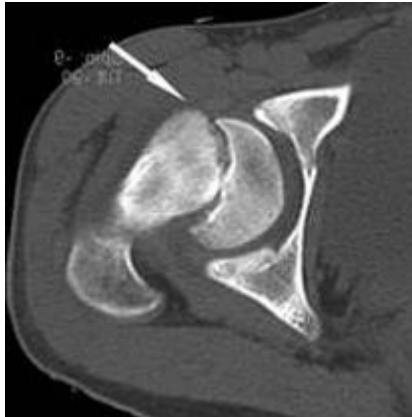


Fig. 2: CT scan of SCFE. Form "acute on chronic". The displacement of the epiphysis of the head against the background of resorption of the dorsal part of the neck. "Step" on the ventral side of the neck.

The nature of the displacement of the epiphysis of the femoral head (EFH) must be considered when determining the indications for surgical treatment. In addition to the traditional division of SCFE by severity and form of manifestation (chronic, "acute to chronic", acute), the definition of tactics uses gradation that takes into account the stability criterion of R.T. Loder.^[5] The prognosis of treatment of the unstable form is more cautious than stable. And if in the treatment of severe stable forms, the views of orthopedists mostly coincide - these are extracapsular intertrochanter osteotomies, but in the treatment of unstable forms, two approaches can be traced.

I. The first stage is the stabilization of the epiphysis of the femoral head, without correction of its position. The second stage is the delayed inter-coronary intertrochanteric osteotomy after reaching synostosis.

II. Various options for open reposition of the femoral head. We adhere to the tactics of one-stage treatment. A technically correctly performed open reposition of the femoral head with corrective osteotomy of the cervix allows restoring the normal anatomical relationships and the function of the affected joint, rehabilitating the patient in a short time.

Summarizing the opinion of most authors, it can be concluded that the main tasks of the SCFE treatment are: stabilization and prevention of the displacement of the

epiphysis of the femoral head; stimulation of early closure of the growth zone; correction of cervical-epiphyseal deformation; prevention of the development of such complications as avascular necrosis, chondrolysis, and deforming arthrosis.

All these tasks are based on the fact that the subsequent development of degenerative changes in the joint depends on the severity of the displacement of the epiphysis of the femoral head, which means that the earlier the treatment is started, the better the outcome and prognosis. However, many issues of treatment of SCFE remain open, and the various versions of therapeutic algorithms described in the literature indicate the ambiguity of the views of orthopedists on the solution of this problem.

MATERIALS AND METHODS

The work is based on the results of observation and treatment of 36 patients (48 joints) with different forms of juvenile epiphysiolysis of the femoral head, treated in the specialized scientific - practical center of traumatology and orthopedics from 2011 to 2018. Among these patients there were 75% of boys and 25% of girls aged 11 to 16 years (mean age was 13.5 years). The majority of sick children (85%) were overweight and hypersthenic constitution. Right-sided lesion occurred in 43% of cases, left-sided in 57%. Bilateral in 8% of cases.

The results of the treatment were evaluated according to the scheme J. Ireland.^[3] The best outcomes were observed in the group of patients with light and moderate degree of SCFE bias, which were performed with the wire or screw epiphysiodesis of the grown zone. Comparative analysis showed the best results in the surgical treatment of acute, unstable forms by way of open reduction in comparison with the results of treatment of severe stable forms by performing the interversion osteotomy.

Based on the experience of many authors and summarizing our own, we came to a number of provisions. When choosing a treatment strategy, you should first focus on the degree of displacement of EFH. With moderate and severe degree, it is necessary to determine the indications for the optimal method, taking into account the form of the SCFE (stable, unstable).

Expectant tactics are unacceptable, and after the diagnosis of the SCFE has been established, treatment should be initiated to prevent further progression of the disease. The procedure for rendering medical assistance to the patient with SCFE.

Measures to prevent additional displacement of the epiphysis of the femoral head: If SCFE is suspected, as a first step, it is necessary to remove the load from the sore limb (crutches).

After a standard X-ray examination of both hip joints and diagnosis, the patient should be hospitalized in the hospital. It is advisable to conduct a multispiral computer tomography.

In accordance with our experience and the opinion of a number of authors, we abandoned skeletal elimination in the treatment of SCFE.^[2,4,6] With an unstable form and pronounced displacement, it is not only ineffective, but also unsafe, to achieve the reposition of the epiphysis with the help of skeletal traction, since such traction increases the risk of ANFH. For the same reason, the closed reposition of EFH should not be attempted with a stable form, this is meaningless, since the epiphysis has already partially merged with the neck in a vicious position.

In case of acute form of SCFE, it is advisable to carry out stabilization (or open reposition and stabilization when EFH is shifted more than 40 °) within 24 hours from the onset of symptoms, and if it is impossible, delay the intervention for a week to relieve post-traumatic inflammation.

Definition of indications for surgical treatment:

- 1) Displacement of the SCFE up to 40 ° posterior stabilization of the EFH by a single conulated screw;
- 2) Unstable form, displacement of EFH more than 40 ° posteriorly, open reposition of the epiphysis of the femoral head with corrective osteotomy of the cervix.
- 3) Stable form, displacement of EFH more than 40 ° posteriorly - corrective intertrochanteric osteotomy (40-60°), rotational (40 ° and more).

When determining the indications for the type of surgical intervention in stable forms, in addition to the magnitude of mixing EFH, the amplitude of movements in the affected hip joint should be taken into account. So, if the patient allows to pass the thigh up to 90 ° passively without pain, without external rotation, then it is safer to stabilize EFH, even with a shift greater than 40 °.

CONCLUSION

The pathological process in SCFE is characterized by a long, graduated course and a variety of clinical and radiological manifestations. The use of classification according to the forms of the SCFE allows differentiation according to the difference in the formation of patho-morphological disorders in the hip joint. Such differences in the mechanogenesis of cervical-epiphyseal deformities are due to the individual anatomical features of the pelvic joint, the severity of the pathological process, the presence of additional traumatization at the stages of the disease.

In determining the treatment tactics for shifting EFH to 40°, we consider the most correct solution to the epiphyseodesis with a single screw, under the control of an electron-optical converter. With stable chronic form and displacement of EFH over 40°, anterior rotational or

flexion-valgizing, derotational intertrochanteric osteotomy. With unstable (acute, "acute on chronic") form and displacement of EFH > 40°, open reposition. In addressing the need for preventive fixation of EFH from the opposite side, we follow the tactics of monitoring patients who have risk factors for bilateral lesion.

It should again emphasize the importance of early diagnosis for this disease. Timely rendered surgical care allows stopping the pathological process, preventing gross anatomical disturbances in the hip joint, ensuring a low risk of complications, minimal possibility of degenerative arthrosis, and a favorable long-term prognosis.

REFERENCES

1. Aronson D. D., Loder R. T. Treatment of the unstable (acute) slipped capital femoral epiphysis // *Clin. Orthop.*, 1996; 322: 99–110.
2. An epidemiological analysis of bilateral slipped capital femoral epiphysis in children / P. Koczewski // *Chir. Narzadow Ruchu Ortop. Pol.*, 2001; 66: 357-364.
3. Ireland J., Newman P. H. Triplane osteotomy for severely slipped upper femoral epiphysis // *J. Bone Jt. Surg.* 1978; 60-A: No 3. P. 390-393.
4. Does unstable slipped capital femoral epiphysis require urgent stabilization? / S. Kalogrianitisa [et al.] // *J. Pediat. Orthop.*, 2007; 16-B: 6–9.
5. Acute slipped capital femoral epiphysis: the importance of physeal stability / R. T. Loder [et al.] // *J. Bone Jt. Surg.*, 1993; 75-A: 1134-1140.
6. Martin T., Fayad F. Severe upper femoral epiphysiolysis. Invasive reduction by Dunn's technic: 11 cases // *Rev. Chir. Orthop.*, 1986; 72(8): 587-598.