



## CLINICAL DIAGNOSING AND TREATMENT OF CONGENITAL HIGH CONDITION OF THE SHOULDER-BLADE IN CHILDREN

<sup>1</sup>\*Dzhuraev Ahror Makhmudovich DSc and <sup>2</sup>Alimukhamedova Feruza Shavkatovna

<sup>1</sup>Professor, Head of Department of Pediatric Orthopedics The Republican Specialized Scientific and Practical Medical Center of Traumatology and Orthopedics, Tashkent, Uzbekistan.

<sup>2</sup>Physician of Department of Pediatric Orthopedics The Republican Specialized Scientific and Practical Medical Center of Traumatology and Orthopedics Tashkent, Uzbekistan.

**\*Corresponding Author: Alimukhamedova Feruza Shavkatovna**

Physician of Department of Pediatric Orthopedics The Republican Specialized Scientific and Practical Medical Center of Traumatology and Orthopedics Tashkent, Uzbekistan.

Article Received on 01/07/2019

Article Revised on 21/07/2019

Article Accepted on 11/08/2019

The article based on the analysis found that the frequency of occurrence of patients with high standing scapula which called Sprengel's disease in world literature is compiled 0.2-1% of total congenital diseases of the musculoskeletal system in children. Analyzing the data of statistics, it can be noted that the congenital high standing of the scapula in girls occurs twice as often as in boys.

The results of diagnostics and surgical treatment of 85 patients with congenital high standing of the shoulder blade at the age of 3 to 14 years who were in the Department of Pediatric Orthopedics of the The Republican Specialized Scientific and Practical Medical Center of Traumatology and Orthopedics (Uzbekistan) from 2005 to 2019 were analyzed using two methods.

Ternovsky's operations were performed on 11 (13%) patients and Pozdeev's operations were performed on 74 (87%) patients.

Long-term results showed that out of 85 (100%) patients, 73 (86%) operated were good and 12 (14%) were satisfactory.

**Relevance.** The high condition of the scapula is a complex of developmental abnormalities, the main signs of which are: a disorder of spatial condition, a disorder of a growth and deformation of the scapula, a displacement in the cranial direction of the distal end of the clavicle, hypoplasia of the upper arm and trunk muscles, until their full aplasia, a disorder of functional state of the neuromuscular apparatus, pathology of the great vessels and a disorder of peripheral blood flow. This pathology draws up 0.2-1% of all congenital diseases of the musculoskeletal system in children.

Hypoplasia, trapeziform aplasia, rhomboid, supraspinatus, subosseous, deltoid, anterior serratus muscles and scapula lifting muscle, accompanying heavy muscle and bone pathologies significantly compound the course and complicates the prognosis of the disease (Yu.A. Veselovsky, 1973; DN, N. Skopichenko, 1999; Yu. A. Veselovsky, M. V. Volkov, 1980 V.G. Abushkina, 2001; G. Langlais, 1989; G. Bornes, 1996;

TGCho, 2000; Khairouni A., 2002, etc.). Heretofore, there is no single view on the cause of the development of Sprengel's disease, the results of treatment are widely diverse.

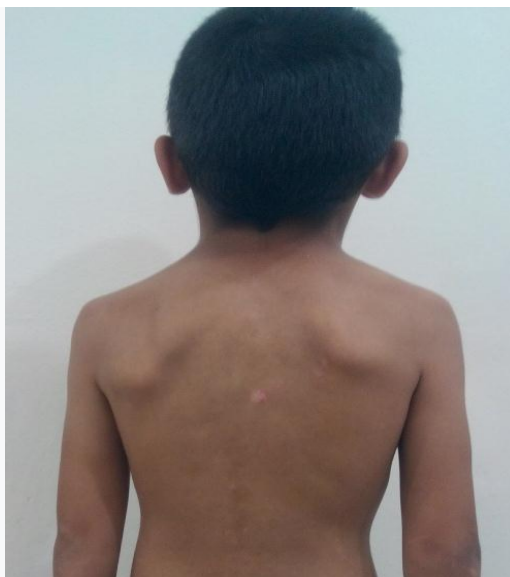The purpose of this work was to study the course and results of surgical treatment in children with congenital high standing of the scapula, taking into account the shape and characteristics of the pathology.

### MATERIALS AND METHODS

In the Department of Pediatric Orthopedics of the RSNPMTSTO, from 2005 to 2019, there were 85 children with congenital high scapula aged from 3 to 14 years in an inpatient treatment. There were 26 were boys (31%) and girls - 59 (69%) among them. The deformation on the sides of the lesion were distributed as follows: left-sided in 41 (48%) children, right-sided - 33 (39%) children and bilateral in 11 (13%) children.

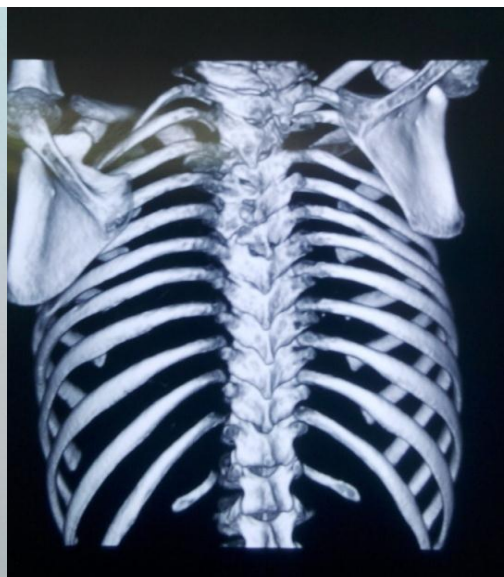All patients took conservative treatment at the place of residence. Conservative treatment included: paraffin, massage, electrophoresis, exercise therapy and gymnastics, but there were no visible results and they applied for RSNPMTSTO in the Department of Pediatric Orthopedics.

To obtain objective information about the initial state of the disease, a comprehensive assessment of changes, as well as the quality of surgical treatment, the following research methods were used: paraclinical, clinical and instrumental, such as digital radiography, ENMG, CT. These research methods allowed us to diagnose accurately and in time, and provide specialized assistance to the patient, depending on the age and severity of the lesion.



Picture. 3

Appearance of the patient's back N. 5 years old, with congenital high standing of the scapula on the right II degree.



Picture. 4

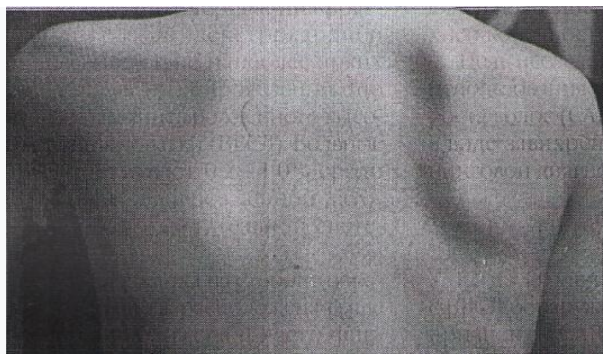
Fig. four Computed tomography of the shoulder blades of the same patient, which determines the high standing of the shoulder blades on the right II degree.

#### The results of the study and their discussion

A study of the history of the disease and a survey of parents revealed the following: 44 mothers out of 85 sick children were pregnant against the background of toxicosis, among them 38 mothers had toxicosis in the first half of pregnancy. In addition, 32 mothers have suffered from an acute respiratory disease during pregnancy and 9 mothers were in inbred marriages. In

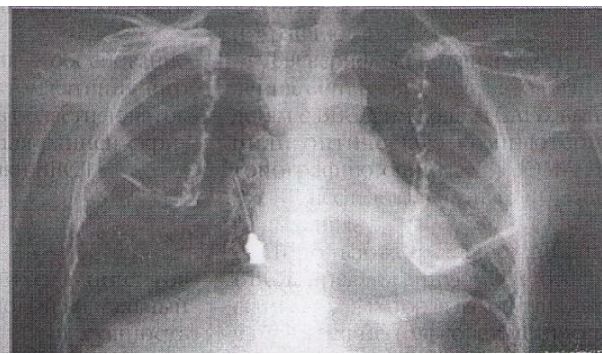
the study of family history in any case it was not revealed burdened heredity for the disease.

X-ray examination was carried out at the initial treatment of a patient, when he was admitted to the hospital, immediately after the completion of surgical treatment and then after 3-6 months.



Picture. 1

Appearance of the back of a patient N. 5 years old, with congenital high standing of the scapula on the right II degree.



Picture. 2

X-ray of the blades of the same patient, where the high standing of the scapula on the right II degree is determined.

In patients on their radiographs of the shoulder girdle performed in the anterior-posterior projections, the following disorders was observed:

- The spatial position of the scapula, its cranial and medial displacement in 59 patients, pathological rotation in 9 patients.
- Options for breaking of its development, i.e. changes in transverse and longitudinal dimensions in 77 patients.
- Characterization of the fixation of the scapula to the spine, the absence of the omovertebral bone in 71

patients and the presence of the omovertebral bone in 10 patients.

- The length of the clavicle and the breaking of its spatial condition had been measured in 7 patients.

The functional state of the neuromuscular apparatus, the shoulder girdle and upper limb, and the blood flow of the upper limb in children with congenital high condition of the scapula had been examined by electromyography. It was performed the electromyography on the muscles of the body, shoulder girdle and shoulder "Trapeziform,

rhomboid, upper axle, front, serrated, deltoid (front, middle and rear portions), large pectoral, two-headed and three-headed.”

There were performed a computed tomographic study on a multi-spiral x-ray computed tomography using standard axial slices and various 3D image reconstruction techniques (multiplane image reconstruction (MPR), reconstruction with a shaded outer surface (SSD), volumetric rendering (VRT)). The variants of the deformation of the scapula in the frontal and sagittal planes, its spatial relation to the adjacent bone structures were studied. In the presence of the omovertebral bone, its shape, option and level of its articulation with the scapula and spine were evaluated. The size and shape of the clavicles, as well as the magnitude of the displacement of their acromial end in the cranial direction, were determined.

The analysis of computer tomograms provided objective data on the variants of the deformation of the scapula, its anatomical and topographic location, as well as on the presence and severity of concomitant pathology (collarbone, spine and chest).

Children with a muscular form of mild disease severity are subjected to conservative treatment. It is assigned a complex of physical therapy aimed to maintaining the amplitude of the movements in the shoulder joint, massage the neck area, back and upper limb, to improve trophism and muscle function of the shoulder girdle and torso. Physiotherapeutic treatments aimed at improving the functional state of the vascular and nervous systems (electrophoresis with aminophylline, pentoxifylline on the collar area), as well as electrical stimulation of the muscles involved in shoulder abduction, are carried out. It was recommended the swimming in the pool, and spa treatment.

In the surgical treatment of children with congenital high condition of the scapula, it is widely used the methods of Ternovsky-Adrianov (Ternovsky, SD, 1959, APPozdeev, 2003, 2004, SPMironova, GPPotelnikova; 2008). Taking into account the option of the severity and course of pathology A. P. Pozdeev, A. A. Pozdeev developed a surgical procedure involving the mobilization above the scapular neurovascular bundle, adaptation of the scapula to the chest, plastics of underdeveloped muscles that shorten the osteotomy of the clavicle, which allows to eliminate completely or substantially the cosmetic defect, restore or improve the function of the upper limb.

The indications of a surgical treatment are the average and severe degree of the disease in children older than 3 years.

A surgical intervention in children with bone and soft tissue forms of moderate and severe A degree of the disease (S.P.Mironova, G.P.Kotelnikova; 2008) are performed an osteotomy of the coracoid process. The

scapula is relegated by turning the acromioclavicular joint. It is performed the transverse osteotomy of the inner and osteoclasia of the outer cortical lamina of the scapula, adapting the contacting surfaces of the scapula and the chest.

The surgical treatment of children with soft tissue and bone forms of the disease of severe B degree. It is performed the osteotomy of the coracoid process. It is formed a pocket between the chest and the latissimus dorsi. The scapula is reduced to the level of healthy one and its lower level is fixed with a formed pocket with three U-shaped sutures to the latissimus muscle; they are replaced with paravertebral muscles.

The shortening of the clavicle is performed by resection of the part on which the fragments overriding each other. It is carried out a retrograde osteosynthesis of clavicle fragments with a Kirschner spoke.

The immobilization of the shoulder girdle during osteotomy of the clavicle was performed with a Smirnov-Weinstein plaster cast for 6 weeks. To eliminate the cosmetic defect and restore the function of the upper extremity, depending on the variant of the course of the disease, it is used the technique in full or individual techniques of the developed techniques. The result of treatment in all forms was fixed after the operation with a complex of rehabilitation therapy. (S.P.Mironova, G.P.Kotelnikov, 2008).

At the postoperative period, it is fit for the patients with congenital high position of scapula the rehabilitation, including immobilization of the cervical spine with an inclination of the head in a healthy direction, exercise therapy, physiotherapy and drug treatment tended to restoring upper limb movements in the shoulder joint, increasing tone and muscle function, resorption of scar, an improvement of regional blood flow and the trophism of the nervous system. A clinical observation of patients carried out until the end of their growth.

The indications for surgical treatment were a moderate and severe degree of the disease in children over 3 years old. The main principles for the restoration of cosmetic defects of the scapula were:

1. Mobilization of the scapula, notably its medial edge, upper medial and lower angle, the front surface of the scapula;
2. Elimination of the pathological rotation of the scapula;
3. The reduction of the scapula to the level of healthy;
4. Adaptation of the front surface of the scapula to the chest.

The restoration of the function of the upper limb was carried out by the following techniques:

1. Mobilization of the suprascapular neurovascular bundle. For this purpose, a semicircular osteotomy of the transverse incision of the scapula was

performed. This technique allowed the supra-scapular neurovascular bundle to become mobilized and prevented a disinervation of the supraspinatus and infraspinous muscles at the bringing down of the scapula.

2. The physiological fixation of the scapula was carried out by stitching its lower corner in the "pocket" between the rib cage and the latissimus dorsi muscle.

The elimination of the cosmetic defect and the restoration of the function of the upper limb was carried out as follows:

Technique of operation. Endotracheal anesthesia. The position of the patient is a lying on the belly with a roller enclosed under the shoulders. A skin incision is made, bordering the upper and medial edges of the scapula, to the level of the VII ribs. The skin-subcutaneous fascial flaps are mobilized: lateral - to the upper and outer edges of the scapula and its lower angle; medial - to the spinous processes of vertebrae. Trapezius and rhomboid muscles are cut off from the medial edge of the scapula, the fibrous cord is cut through. The muscle, lifting the shoulder blade, is crossed at the place of its attachment to the shoulder blade. Along the medial edge of the scapula, on the front of its surface, the muscle fibers of the anterior serratus and subscapularis muscles are cut off. Soft tissues are separated from the front surface of the scapula to transverse cutting, keeping the periosteum as much as possible.

A transverse incision of the scapula is highlighted subperiosteal, an osteotomy of the scapular bone is performed with a grooved chisel, retreating from the transverse incision of the scapula by 3-5 mm. Subperiosteally an osteotomy of the base of the coracoid process is isolated and produces, while the bit is directed from the bottom up and from the middle outwards. By turning in the acromioclavicular joint the pathological rotation of the scapula is eliminated and a bringing down is conducted (the orientation is the spine of the scapular bones, and in bilateral lesion the physiological norm is the lower edge of the second thoracic vertebra).

The congruence of the sliding surface of the chest and scapula is assessed. In case of severe deformity of the latter, an osteotomy of the inner cortical plate and osteoclasia of the outer at the apex of the deformity are produced.

In the interval between the rib cage and the latissimus dorsi muscle, a back pocket is formed into which the lower corner of the scapula is immersed. The scapula is fixed at a new place by stitching its lower corner in the formed "pocket" to the latissimus 3-4 U-shaped seams.

The wound is sutured in layers. Drainage of wounds is performed in the upper and lower sections by two rubber graduates. In the postoperative period, the limb was immobilized with a scarf bandage for 10-14 days.

In the postoperative period, rehabilitation patients, including immobilization of the cervical spine with an inclination of the head in a healthy direction, exercise therapy, physiotherapy and drug treatment aimed at restoring upper limb movements in the shoulder joint, increasing tone and muscle function, resorption of scar, an improvement of regional blood flow and the trophism of the nervous system are prescribed to patients with congenital high scapula. Clinical observation of patients carried out until the end of their growth.

In case of severe deformity, the shoulder joint with the scapula is raised upwards and displaced to the front side and the scapula is reduced in size above the healthy one by more than 5 cm to 10 cm. Muscles that are strongly hypotrophied are not exceeding 120-90.

The results of surgical treatment showed that a severe degree of the disease in 10 patients was combined with accessory omovertebral bone, and in 6 patients it was combined with Klippel-Feil disease. In addition, varying degrees of deformity of the ribs and scoliosis were found in other patients.

Ternovsky's operations were performed on 11 (13%) patients and Pozdeev's operations were performed on 74 (87%) patients. After the operation, the discharge thoracobrachial plaster cast was applied to the patients for 4 weeks. In addition, exercise therapy was prescribed on the fingers of the hand and UHF through a plaster cast.

The massage, electrophoresis with potassium iodide alternating with novocaine, exercise therapy, active sports (swimming, basketball and volleyball) were prescribed after the removal of the plaster bandage.

Long-term results showed that out of 85 (100%) patients, 73 (86%) operated were good and 12 (14%) were satisfactory, since these patients had a neurological and endocrine changes accompanied by a severe degree of the disease.

Thus, the analysis of the obtained results correlates with the data of domestic and foreign literature and allows us to conclude that the operation according to Pozdeev's method is the method of choice in the surgical treatment of congenital high position of the scapula in children.

## REFERENCES

1. Geht B.M. Teoretical and clinical elektromiography. L. Nauka, 1990-129 page.
2. Greitemann B. Treatment of congenital elevation of the scapula. 10 (2-18) year follow-up of 37cases of Sprengel's deformity / B. Greitemann, J. Rondhuis, A. Karbowski // Acta Orthop. Scand, 1993; 64(3): P.365-368.
3. Congenital High Scapula / A. Khairouni, H. Bensahel, Z. Csukonyi et al. // J. Pe diatr. Orthop, 2002; 11(1): P.85-88.

4. Pozdeev A.A. Surgical treatment of children with congenital high standing of the scapula the topic of the dissertation and abstract on the Higher Attestation Commission of the Russian Federation 14.00.22, candidate of medical sciences Pozdeev, Andrei Aleksandrovich, 2006, St. Petersburg.