

**ULTRASONOGRAPHIC DIAGNOSIS OF THE HIP JOINT DYSPLASIA IN CHILDREN
OF THE FIRST YEAR OF LIFE**

Salieva N. I.*

Republican Specialized Scientific and Practical Medical Centre of Traumatology and Orthopaedics.

***Corresponding Author: Salieva N. I.**

Republican Specialized Scientific and Practical Medical Centre of Traumatology and Orthopaedics.

Article Received on 30/07/2019

Article Revised on 19/08/2019

Article Accepted on 10/09/2019

ABSTRACT

Early detection of the pathology of the hip joints in children is an important task of modern orthopedics. We conducted an ultrasound examination in 59 children from 2 months to 1 year of life. The study was conducted according to the method of R. Graf. The obtained ultrasound data are analysed. Depending on the changes in the elements of the hip joint, the studied children are divided into groups: children with mature hip joints, children with changes in the acetabular and femoral component (congenital dislocation of the thigh), children with changes in the acetabular and femoral components (congenital dislocation of the hip and rickets), children with changes in the femoral component (rickets). Ultrasonic changes are relatively studied. The role of ultrasound studies in the differential diagnosis of pathology of the hip joint in children is proved.

KEYWORDS: Hip joint, ultrasound, dysplasia, rickets, children.**INTRODUCTION**

Dysplasia is the common name for disorders in the development and growth of organs and tissues, regardless of the time and cause of their occurrence. The most common dysplasia in young children is bone, of which hip dysplasia (TPA) is up to 15% in the structure of orthopedic pathology, leading to static-dynamic disorders and early disability.^[2] In recent years, there has been a trend towards an increase in the absolute number of patients with TPA. According to several authors, TPA occurs in 5-16 children in each 1000 newborns, dysplastic hip dislocation - in 3-4 children per 1000 normal births.^[2,4,5]

Suspected, but not confirmed, hip dislocation indicates only the attentiveness of the physician and will not cause harm to the child. An undiagnosed disease can make a child disabled for life-long.^[2,5] Dysplasia is often found on the background of rickets. A delay in ossification of the hip joints with rickets is often combined with a delay in the physiological development of the hip joints, thus complicating not only the diagnosis, but also the treatment of TPA and congenital dislocation of the hip.

Ultrasound examination (ultrasound) allows you to visualize the cartilage and soft tissue structures, which, basically, presents the hip joint in children in the first months of life. The method is non-invasive, it is possible to reuse it and use functional tests in real time. This type of study of the hip joints can be a marker of ossification of its structures as reliably as x-rays. First of all, we have the opportunity to assess the dynamics of ossification of

the hip joints by the timing of the appearance of the ossification core.^[7]

OBJECTIVE

To improve the diagnosis of underdevelopment of the elements of the hip joint in children by analysing x-ray / sonographic changes.

MATERIALS AND METHODS OF RESEARCH

Ultrasound was performed in the area of both hip joints in 59 children of the first year of life (118 hip joints). The studies were carried out in the X-ray diagnostic department of the Republican Specialized Scientific and Practical Medical Center for Traumatology and Orthopedics using an SonoScape ultrasound scanner using a multi-frequency linear scan sensor with 5-7.5 MHz.

For proper ultrasound of the hip joints in children of a younger age group, it was necessary to observe the following conditions: 1) the correct placement of the child to provide reliable data; 2) the position of the sensor relative to the axis of the body should be only vertical, that is, the plane of scanning of the joint should pass exactly in the middle of the greater trochanter; 3) knowledge of the ultrasound anatomy of the hip joints in children of the first months of life; 4) the correct determination of the coordinate points of the joint for further adequate angular measurements.

Assessment of the formation of the hip joints was carried out on the basis of the ultrasound technique of the hip

joints of Professor R. Graf (Austria, 1984), which assesses the formation of the bony acetabulum, bone and cartilage bay window. The undoubted advantage of the R. Graf technique that distinguishes it from all alternative methods is the detailed standardization of the implementation of ultrasound of the hip joint in a morphologically unambiguous standard plane, differentiated classification of the hip joint according to the degree of maturity of the formation, taking into account the age of the child, including the concept of instability and decentration.^[4]

The Graf lines (along the surface of the ilium), the acetabulum roof (its bony part) and the acetabulum (cartilaginous lip) comprise two measured angles: the α -angle of the acetabulum roof, β -angle of the acetabulum.

RESULTS AND DISCUSSION

Within the framework of this project, clinical and diagnostic studies were carried out, a prospective analysis of clinical, digital radiological, ultrasonographic and laboratory data was carried out (Table 1.)

Research Methods	Number of Children
Clinical examination	59
Digital radiography	31
Ultrasonography	59
Laboratory blood test (calcium, phosphorus, alkaline phosphatase, vitamin D)	7

Clinical research method

- Limitation of abduction of legs bent at right angles in the hip and knee joints;
- Asymmetric arrangement of skin folds on the hips;
- Asymmetric location of the gluteal folds on the hips;
- Shortening of the lower extremities;
- Excessive rotation of the thigh;
- Symptoms of "slipping" or "clicking" in the hip joint;
- External rotation of the feet.

During the examination of the hip joints in 59 children (118 hip joints) were distributed by gender (Table 1). Distribution of children by gender:

Overalln=54	Male		Female	
	One side	Both side	One side	Both side
№	5	18	4	27
%	9,2	33,3	7,4	50,1


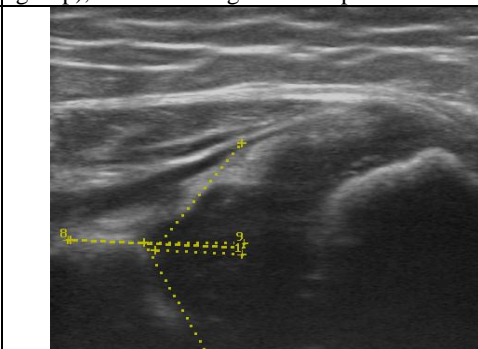
According to the table, only 59 children were examined, of which 5 children showed no deviations from the hip joints, 5 boys (9.2%) and 4 girls (7.4%) were diagnosed with unilateral changes, and 18 boys (33,3%) and in 27 girls (50.1%) bilateral.

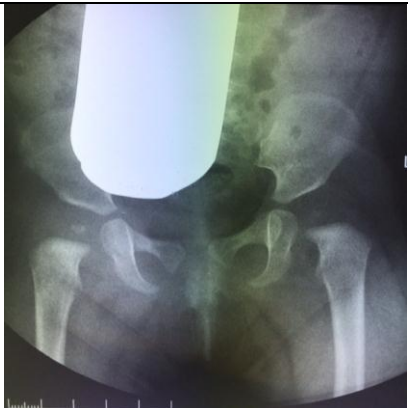
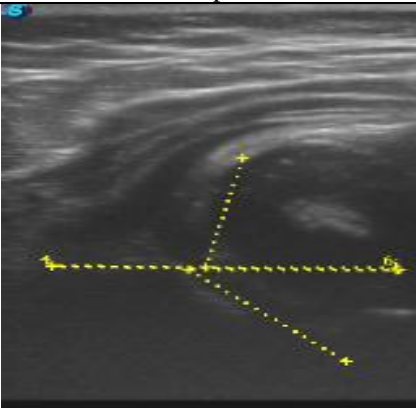
Forms of hip dysplasia in children of the first year of life (according to R. Graf) (Table 2).


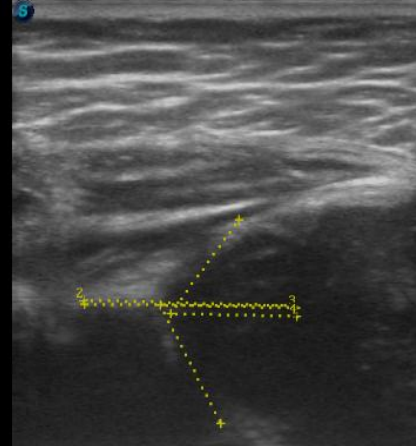
Overall (n=59)	1gr.		2gr.			3gr.		4gr.
	A	B	A	B	C	A	B	C
Till 3 Months	1(1,7%)	3(5,0%)	5(8,4)	2(3,3%)	4(6,7%)	0	0	0
3-6 Months	2(3,3%)	1(1,7%)	2(3,3%)	9(15,2%)	6(%)	2(3,3%)	0	1(1,7%)
6-9 Months	3(5,0)	2(3,3%)	2(3,3%)	4(6,7%)	1(1,7%)	1(1,7%)	0	0
9-12 Months	1(1,7%)	1(1,7%)	1(1,7%)	1(1,7%)	1(1,7%)	1(1,7%)	1(1,7%)	1(1,7%)
Overall	7(3,3%)	7(11,8%)	10 (16,9%)	16 (27,1%)	12 (37,2%)	4 (6,7%)	1 (1,7%)	2 (3,3%)


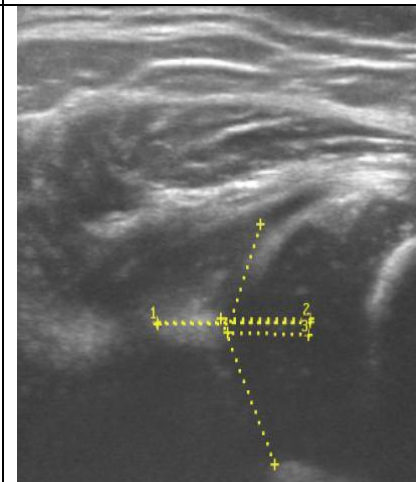
According to the table, it can be noted that among the studied children more often there were changes corresponding to group 2 - with a physiological delay in

the development of components of the hip joint, while taking into account the data of the most altered side.

I control group		
X-ray diffraction pattern mature hip joints child M., 6 months.	Sonogram of the hip joint, mature joint (control group), with a rectangular bone protrusion.	Blood tests Average performance
		Vitamin D 32 (n` 30-100) ng / ml Osteocalcin 28 (n` 11-43) ng / ml Alkaline phosphatase 495 (n` <= 644) u / L Phosphorus 1.6 (n` 1,30-2,26) mmol / L Calcium 2.30 (n` 2,02-2,60) mmol / L Ionis. calcium 1.5 (n` 1,1-1,4) mmol / L

II group VVB		
Dysplasia of both hips with a pre-dislocation of the head of the left femur and rickets on both sides.	Sonogram of the hip joint of group II - with the presence of congenital dislocation of the hip	Blood tests Average performance
		Vitamin D 21 (n`30-100) ng / ml Osteocalcin 8 (n`11-43) ng / ml Alkaline phosphatase 729 (n` <= 644) u / L Phosphorus 0.8 (n`1,30-2,26) mmol / L Calcium 1.4 (n`2,02-2,60) mmol / L Ionis. calcium 0.8 (n`1,1-1,4) mmol / L

III group: dysplasia during rickets		
Photo radiograph of the child K., 8 months. Hip dysplasia with congenital dislocation of the femur.	Sonogram of the hip joint of group III - dysplasia on the background of rickets	Blood tests Average performance
		itamin D 11 (n`30-100) ng / ml Osteocalcin 8 (n`11-43) ng / ml Alkaline phosphatase 832 (n` <= 644) u / L Phosphorus 0.7 (n`1,30-2,26) mmol / L Calcium 1.40 (n`2,02-2,60) mmol / L Ionis. calcium 0.9 (n`1,1-1,4) mmol / L

IV group: VVB + rickets		
Photo radiograph of the child K., 8 months. Hip dysplasia, the presence of congenital dislocation of the femur.	Sonogram of the hip joint of group IV, with the presence of VVB + rickets	Blood tests Average performance
		Vitamin D 8 (n`30-100) ng / ml Osteocalcin 7 (n`11-43) ng / ml Alkaline phosphatase 843 (n` <= 644) u / L Phosphorus 0.8 (n`1,30-2,26) mmol / L Calcium 1.30 (n`2,02-2,60) mmol / L Ionis. calcium 0.9 (n`1,1-1,4) mmol / L

On an ultrasound examination in children of the control group, the angle α did not exceed 600, the angle β no more than 550, with the presence of a pointed or smoothed bone protrusion, which corresponds to the first type according to the Count.

In children of the second group, with congenital dislocation of the hip, the angle α was in the range of 50-430, the angle β was less than 55-770, the immature hips, bone roofs were flattened, the cartilaginous protrusion does not cover the head, which corresponds to the second third type according to the Count.

In children of the third group, dysplasia against rickets, angle α does not exceed 600, angle β does not exceed 550, bone roofs are flattened, lack of a bone core, sharpening of the internal X-ray angles of the proximal metaphyses of the femurs.

In children of the fourth group, with congenital hip dislocation and dysplasia due to rickets, the angle α varies from 43 to 490, the angle β is less than 770 immature hip joints, the bone roofs are flattened, the cartilaginous protrusion does not cover the head, the absence of the bone core, the sharpening of the internal x-ray angles of the proximal metaphyses of the femur.

CONCLUSIONS

An analysis of the sources of literature and our observations showed that X-ray and ultrasonographic methods of research allow us to determine rickets dysplasia and differentiate it with congenital pathology of the hip joint in children. The study should be carried out in children at risk, with clinical symptoms of dysplasia and congenital dislocation, diseases and malformations of the musculoskeletal system. The most optimal time for conducting ultrasound screening: - 2-3.5 months to exclude dysplasia of the acetabulum and proximal femur (congenital dislocation of the thigh) - at this age, all elements of the joint develop very quickly, and pathological changes detected during this period joints are best suited to orthopedic correction; - 6-12 months to exclude rickets. With the modern development of diagnostic equipment, ultrasound of the hip joints seems to be a profitable alternative to the X-ray method, since it allows you to visualize the cartilage structures of the hip joint with a high degree of reliability at an earlier date, while avoiding unjustified radiation exposure.