ejpmr, 2020,7(1), 135-143

SJIF Impact Factor 6.222

EUROPEAN JOURNAL OF PHARMACEUTICAL AND MEDICAL RESEARCH

www.ejpmr.com

Research Article

ISSN 2394-3211

EJPMR

CURATIVE EFFECTS OF CACTUS "*OPUNTIA STREPTACANTHA*" TO REDUCE PHOTO-INDUCED DERMATOSIS IN PUBERTAL MICE

Mohamed Nizar Zourgui[a,b], Sabrine Ben Lataief[a], Lazhar Zourgui*[a] and Mohamed Amri[b]

[a]University of Gabes Research Unit of Active Biomolecules Valorisation, Higher Institute of Applied Biology of Medenine, 4119 Medenine, Tunisia.

[b]University of Tunis El Manar Research Unit of Neurophysiology, Faculty of Sciences of Tunis, Tunis, Tunisia.

***Corresponding Author: Prof. Lazhar Zourgui**
University of Gabes Research Unit of Active Biomolecules Valorisation, Higher Institute of Applied Biology of Medenine, 4119 Medenine, Tunisia.

Article Received on 06/11/2019 **Article Revised on 27/11/2019** **Article Accepted on 17/12/2019**

ABSTRACT

In traditional medicine extracts of plants (Cactus) are widely employed for the treatment of skin, epithelium wounds and mucous membrane irritation. Photo-induced dermatosis is the result of the harmful effect of UV irradiations on the skin. The aim of this study was to clarify whether *O. streptacantha* cladodes has a curative effect against the irradiations ultraviolet C (UVC). We examined the effects of cactus extract on skin damage including changes in cutaneous cover and histological modifications caused by long-term ultraviolet C irradiation. The extract of the cactus cladodes (50mg/kg every day) restored the normal tissular architecture of the skin irradiated better than that observed for the treatment by the MTX (0.5mg/kg/week). Our present study has shown that the irradiation of mice is made by their exhibition an ultraviolet hand lamp (UVC) of wavelength 254 nm evidenced by a significant increase or decrease of certain biochemical parameters.

KEYWORDS: *Opuntia streptacantha; Methotrexate; Ultraviolet irradiations; Skin damage; Dermatosis.*

INTRODUCTION

The sun, the origin of any life on earth, is synonymic to be well and essentially associated with the happiness, with the holidays and with the pleasure. However, since good about twenty years, the attention gradually focused on the fatal effects of the ultraviolet irradiation, in particular on the skin. The radiations of the sun consist of visible rays, of infrared rays and of ultraviolet rays.[1] The invisible ultraviolet rays to the human eye penetrate more at least profoundly into the skin. They have beneficial effects such as the bronzing, the antirachitic action; except his prevention initiative of rickets, the vitamin D has a protective effect on cancers (cutaneous but also colon, breast and prostate).[2] While the fatal effects of ultraviolet rays[3] show themselves by the sunburns, the premature skin aging[4], depress the immunizing function of the skin[5] and the skin cancers.[6,7,8]

Natural products such as herbs, fruits, and vegetables become popular in recent years due to public awareness and increasing interest among consumers and scientific community.[9] In this respect, our laboratory gives special interest to the curative effects of cactus to reduce photo-induced dermatosis.

Opuntia streptacantha a member of the Cactaceae family is a tropical or subtropical plant originally grown in South America and is cultivated in dry regions as an important nutrient and food source.[10,11,12]

It is utilized in arid and semiarid zones as a fruit and forage crop.[13] According to several studies, cactus yields high values of important nutrients such as minerals, carotenoids, fatty acids, and essential oil.[14] It is also very rich in vitamins.[15,16]

In traditional medicine, extracts of polysaccharide-containing plants are widely employed for the treatment of skin and epithelium wounds and of mucous membrane irritation.[17] The extracts of *Opuntia* cladodes are used in folk medicine for their antiulcer and wounds-healing activities.[18,19] Another study described the wounds-healing potential of two lyophilized polysaccharide extracts obtained from *O.ficus indica* cladodes applied on large full-thickness wounds in the rat.[20] Recently, there are many reports that substances isolated from many dietary herbals such as grape seed proantocyanidins, green tea catechin, tomato paste (lycopene), pine pycnogenol, and vitamine C etc. are used as oral administration for the protection against ultraviolet (UV)-induced skin damage. The oral administration of mixture of vitamine C, vitamine E, pycnogenol and evening primrose oil also prevented UVB-induced skin wrinkle formation.[21]

Maho and Yoshiyuki reported that turmeric prevents chronic ultraviolet B (UVB)-irradiated skin damage.[22] They examined the effects of a turmeric extract on skin damage including changes in skin thickness and elasticity, pigmentation and wrinkling caused by long-term, low dose ultraviolet B irradiation in melanin-possessing hairless mice.

This desert plant can be used as an anti-inflammatory, analgesic, hypoglycemic, antiviral, and antioxidant agent and may protect against numerous chronic diseases, including cancer[23,24], cardio-and cerebrovascular, ocular, and neurological diseases.[25,26]

In this study, we examined the effects of a cactus *O. streptacantha* extracts on chronic UVC irradiation-induced skin damage including changes in skin thickness and pigmentation. The objective of our experimental study is to explore the curative effect of the extract of cactus to limit dermatosis photo-induced by comparing it with the curative effect of a pharmaceutical product: the methotrexate (MTX) in female mice of *"Mus musculus"* strain.

MATERIALS AND METHODS

Plant Material and Extract Preparation

Cactus *(O. streptacantha)* young cladodes (2-3 weeks of age) were collected from the local area of Kasrine City (Tunisia), washed with water, and cut into small pieces (without removing the small leaves and spines) and then pressed using a handpress. About 30g of resulting extract was homogenized with 1,000 ml of distilled water and centrifuged at 4,000 rotations per minute (rpm) for 15 min at 4° C to remove any impurity resulting from the extraction process. *Opuntia* supernatant was stored at -20 °C until use.

The Medicine: The Methotrexate (MTX)

Methotrexate, abbreviated MTX is widely used in dermatology for several years and formerly known as amethopterin, is an antimetabolite and antifolate drug. It is anti-inflammatory drug and is particularly interesting in the chronic inflammatory affections.[27]

It is used in treatment of cancer, autoimmune diseases, ectopic pregnancy, and for the induction of medical abortions.
In our study, the dose that we injected by respecting the physical weight of mice is 0.5 mg / kg.

Induction of the dermatosis

The irradiation of mice is made by their exhibition has an ultraviolet hand lamp (UVC) of wavelength 254 nm. The intensity of the lamp UV is equal to 2 lux (lx).

The period of irradiation was varied to control the UVC energy applied to the dorsal region.

Photos on the modifications of the cutaneous cover are taken every 4 days after the initiation of UV irradiation. Since inflammation of the skin: erythemic patch, defective hurts with edema was developed after 4 weeks of irradiation.

Animals' treatments

Forty-eight Mus musculus female mice (average body weight 26 g; age: 6 weeks old). Animals are distributed according to their treatment in 8 cages placed in a pet shop where the temperature is regulated in 22±3 °C with alternations of 10 an hour of darkness and 14 an hour of light.

These mice were given a standard granulated food and drinking water and were divided into eight groups as follows:
- Group1 (C): Control mice receiving a normal food.
- Group 2 (CT):Mice receiving from the food and from the water of at will drink during 2 months further to a treatment by the extract of cactus cladodes (50 mg / kg) during a month.
- Group 3 (MTX):Mice receiving from the food and from the water of at will drink during 2 months further to a treatment by the MTX (0.5mg / kg) during a month because of an injection a week.
- Group 4 (UV): Mice exposed daily to UV radiation during 3 months.
-Group 5 (UV+CT7): Mice exposed daily to UV radiation during 2 months further to a treatment by the extract of cactus cladodes (50 mg / kg) during a week.
-Group 6 (UV+CT15): Mice exposed daily to UV radiation during 2 months further to a treatment by the extract of cactus cladodes (50 mg/kg) during 2 weeks.
-Group 7 (UV+CT30):Mice exposed daily to UV radiation during 2 months further to a treatment by the extract of cactus cladodes (50 mg / kg) during 2 weeks.
-Group 8 (UV+MTX): Mice exposed daily to UV radiation during 2 months further to a treatment (by the MTX (0.5 mg / kg) during a month because of an injection a week.

- The injections were made by intraperitoneal way. The sampling of blood and organs were made 24 hours after the last injection.
- Allowing that the injections either by the extract of cladodes, or by the MTX were simultaneous with the exhibition in UV (for the groups (UV+CT7J), (UV+CT15J), (UV+CT30J), (UV+MTX)). With an exhibition in UV the morning and the injection after noon.
- The sacrifice of animals was made in the laboratory after decapitating in order to minimize the handling stress. The blood serum was obtained by centrifugation (1.500 rpm, 15 min, and 4°C) and stored at -80°C until use for biochemical determination.

Biochemical assays

The level of glucose, cholesterol, triglycerides and the activity of lactate dehydrogenase (LDH), aspartate amino transferase (ASAT), alanine amino transferase (ALT),

creatinine and urea in serum were determined by kit methods (Spinreact).

Histological examination in UVC-irradiated mice

For light microscopic observation, dorsal skin samples were immersed for 48h at 4°C in a fixative solution (10% formaldehyde, in phosphate buffer, pH 7.6), dehydrated in ethanol, and embedded in paraffin. Paraffin sections, 5 µm thick, were made and stained with hematoxylin – eosin solutions (HE) using the standard techniques.[28] Tissue preparations were observed and microphotographed under a light BH2 Olympus microscope (Olympus, Tokyo, Japan).

Statistical analysis

Two independent experiments were performed. Data were expressed as means ± standard deviation (SD). Statistical significance was assessed by Student'*st* test. $P<0.05$ was considered statistically significant.

RESULTS

Blood glucose, cholesterol and triglycerides levels

The exhibition of mice in the UV irradiations induced a significant increase of glucose and a significant decrease of triglycerides and total cholesterol as compared to controls. Supplementation with either MTX or the extract of cactus restored these levels to almost control values after 3 months of treatment (Table 1).

Serum markers of liver and kidney damages

Lactate dehydrogenase (LDH), Aspartate aminotransferase (AST) and Alanine aminotransferase (ALT) are released into the blood when certain organs or tissues are injured. As shown in table 2, these activities were significantly higher in UV treated mice than in controls. Supplementation with either extract of *Opuntia streptacantha* or the MTX restored these levels to almost control values after a week, 2 weeks and a month of treatment.

UV treatment also induced severe kidney damages evidenced in serum by significant increase of creatinine and urea. When UV treated mice were also treated with the extract of cactus or MTX, all theses biomarkers were restored to almost normal values as compared to mice treated by UV only (Table 3).

Curative effects of the extract of cactus and the MTX on the cutaneous cover: (Fig.1)

-For control mice (Fig. 1A), those treated by the cactus (Fig. 1B) and those treated by the MTX (Fig. 1C), the skin seems unhurt.

- The exhibition of the group of mouse in the UV radiations during variable periods ends in several types of pathologies affecting the skin. The clinical observation of the treated mice shows:

- An appearance of an erythemic patch at the level of ears from the first week of irradiation (Fig. 1D). After 15 days of irradiation, the erythemic patch extends towards the back (Fig. 1E).

- After a month of exhibition, we attend an accentuation of erythemic patches with partial regrowth of hairs accompanied in defective hurts of ears (Fig. 1F).

- After 2 months of irradiation, appearance of the more or less necrotic lesions of the back and the ear (Fig. 1G and H). While after 3 months of exhibition, an appearance of the necrotic and crusted lesions sometimes on infected (Fig. 1I and J).

-After 2 months of irradiation with a treatment of 7 and 15 days by the extract of cactus: a light improvement which shows itself by a decrease of the size of the erythemic patches (Fig. 1K and L).

- After 2 months of irradiation with a treatment of month by the extract of cladodes of *Opuntia*, we note a clear improvement marked by the regrowth of hairs to certain mice, partial disappearance of the erythemic patches and the necrotic hurts (Fig. 1M) .Same observations for mice irradiated then treated by the MTX during a month (Fig. 1N).

Curative effects of the extract of cactus and the MTX: Cutaneous Biopsy (Fig.2)

-The examination of the histological sections of the skin of control mice (Fig. 2A), those treated by the cactus (Fig. 2B) and those treated by the MTX (Fig. 2C) showed normal architecture: a thin skin and a normal dermis.

-To irradiated mice (Fig. 2D), we note at the level of the skin an accomplished hyperkeratosis of acanthosis, a basal cell vacuolization with cytonuclear anomalies. An inflammatory infiltrate at the level of the dermis.

- To mice treated by the extract of cactus for a week (Fig. 2E), we note a light decrease of the hyperkeratosis and the persistence of inflammatory infiltrate at the level of the dermis.

- To mice treated by the extract of cactus for two weeks (Fig. 2F), we note a remarkable decrease of the hyperkeratosis and the acanthosis.

-To mice receiving a double treatment (irradiation followed by a treatment by the extract of cactus for a month) (Fig. 2G) we note a restoring of the tissular architecture of the skin: absence completes of hyperkeratosis, decrease of acanthosis, improvement of the cytonuclear anomalies and a reduction in inflammatory infiltrate.

-To mice receiving a double treatment (irradiation followed by a treatment by the MTX (Fig. 2H) we note a restoring of the tissular architecture of the skin: remarkable reduction in hyperkeratosis, decrease of acanthosis, and a remarkable reduction in inflammatory infiltrate.

Table 1: Effects of irradiation UV, extract of cactus and MTX on the activities (I.U/ L) of Lactate Dehydrogenase (LDH), Aspartate Aminotransferase (AST), Alanine Aminotransferase (ALT) in serum.

Group	LDH	ASAT	ALAT
T	750 ± 1.31	245 ± 1.60	223 ± 8.07
C	719 ± 2.10	239.66 ± 3.14	225 ± 9.27
MTX	1081±2.11*	299.66±24.99*	268±34.34*
UV	1841 ± 3.28**	338 ± 22.5**	300.4 ± 20.15**
UVC7	1228.33 ± 1.24*	318.33 ± 33.87*	287.83 ± 25.48*
UVC15	914.66 ± 2.05*	258.66 ± 31.18	257 ± 40.2
UVC30	892.2 ± 4.21	245 ± 17.81	230 ± 19.11
UVMTX	725.5 ± 2.25	251.33 ± 12.12	232 ± 21.17

Values are the mean of 6 measurements ± SD.
* $p \leq 0.05$, compared to control group (C).
** $p \leq 0.01$, compared to control group (C).

Table 2: Effects of irradiation UV, extract of cactus and MTX on blood glucose (mmol/l), cholesterol (mmol/l), and triglycerides (mmol/l) levels.

Group	Glucose (mmol/l)	Cholesterol (mmol/l)	Triglycerides (mmol/l)
T	9.9 ± 0.21	3.2 ± 0.16	2 ± 0.13
C	10 ± 1.19	3.15 ± 0.39	1.9 ± 0.3
MTX	10.25±0.85	3.8±0.46*	2.3±0.33
UV	11.4 ± 0.41**	1.86 ± 0.44**	0.82 ± 0.22**
UVC7	11.15 ± 1.66*	2.5 ± 0.5*	1.3 ± 0.48*
UVC15	10.83 ± 1.21*	2.82 ± 0.36	1.72 ± 0.46
UVC21	9.75 ± 0.32	2.9 ± 0.36	1.68 ± 0.36
UVMTX	10.04 ± 0.16	2.55 ± 0.36*	1.4 ± 0.38*

Values are the mean of 6 measurements ± SD.
* $p \leq 0.05$, compared to control group (C).
** $p \leq 0.01$, compared to control group (C).

Table 3: Effects of irradiation UV, extract of cactus and MTX on the activities ofthe creatinine (µmol/l) and the urea (mmol/l) in serum.

Group	Creatinine	Urea
T	72 ± 2.16	8 ± 1.29
C	70 ± 1.41	7.8 ± 1.04
MTX	89±5.97*	9±1.07*
UV	109 ± 9.57**	9.64 ± 1.08**
UVC7	86.33 ± 11.68*	9.25 ± 0.42*
UVC15	80.66 ± 9.36	8.7 ± 0.8
UVC21	77± 8.6	8.3 ± 0.71
UVMTX	72.66 ± 6.1	8.5 ± 0.45

Values are the mean of 6 measurements ± SD.
* $p \leq 0.05$, compared to control group (C).
** $p \leq 0.01$, compared to control

Fig1: Modifications of cutaneous cover: before, after irradiation and under treatment by the extract of cactus and by the MTX.

Legend: 1-Erythemic patch; 2- Erythemic accented patches; 3- Defective lesion of ears; 4-Necrotic lesions; 5-Necrotic and crusted lesions on infected.

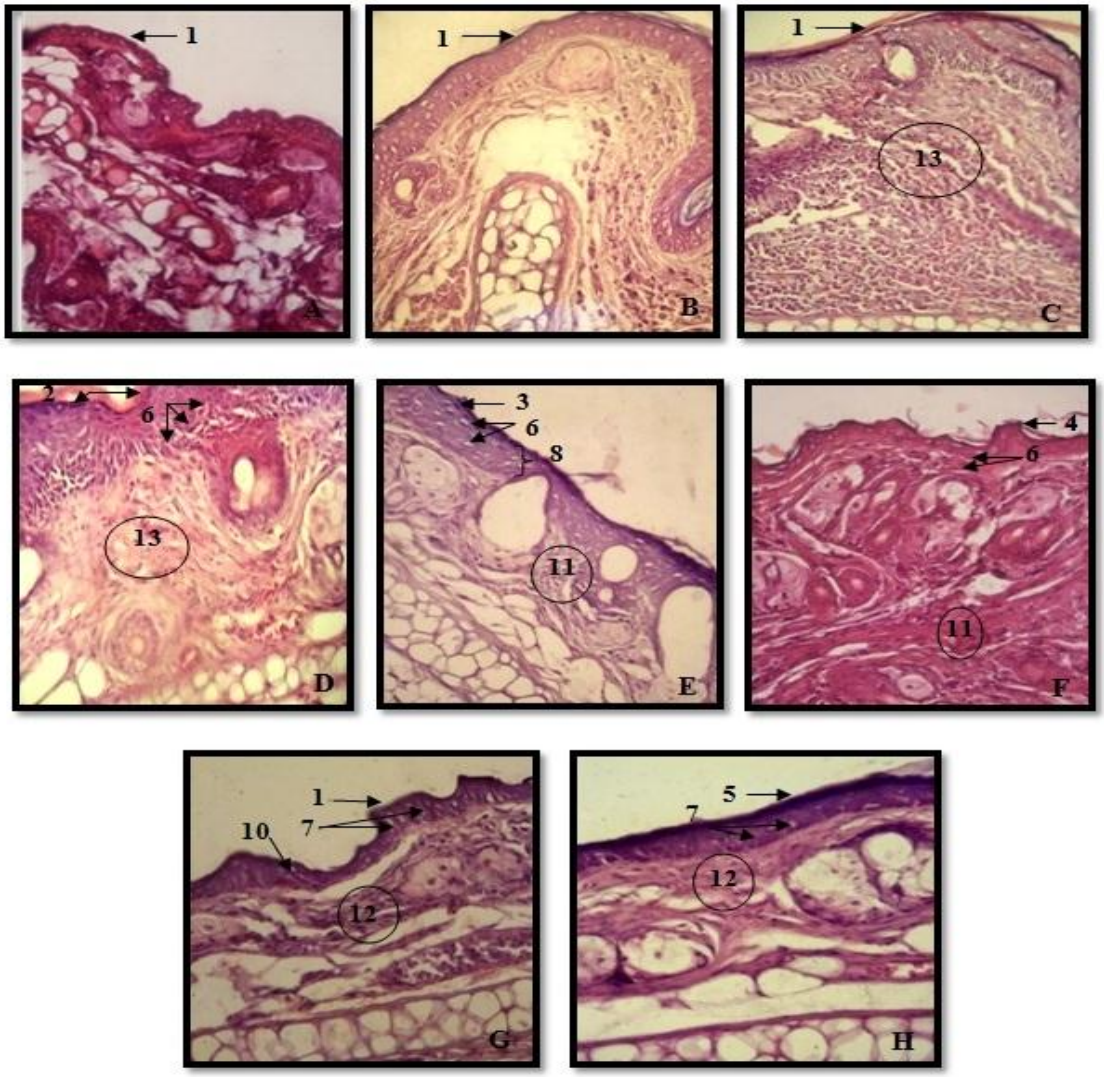

Fig 2: Histological sections of the skin of control mice (A), mice treated by the cactus (B), mice treated by the MTX (C), irradiated mice (D), mice treated with UV+CT7(E), mice treated with UV+CT15(F), mice treated with UV+CT30(G), and mice treated with UV+MTX (H).

Coloring: Hematoxylin-eosin (HE) (G x 40)

Legend: 1- Superficial cell with normal production of keratosis; 2- Hyperkeratosis; 3- Light decrease of hyperkeratosis; 4- Moderated hyperkeratosis; 5- Light hyperkeratosis; 6- Cytonuclear anomalies; 7- Moderate improvement of the cytonuclear abnormalities; 8- Acanthosis; 9- Important decrease of acanthosis; 10- Absence of acanthosis; 11- Moderate inflammatory infiltrate; 12- Light inflammatory infiltrate; 13- Inflammatory infiltrate important.

DISCUSSION

Increasing attention is paid to the study of plant and natural products, which can neutralize the harmful effects of ultraviolet rays and prevent multiple cutaneous diseases. To this end, different types of herbal plants have been re-evaluated and recognized as valuable sources of nutraceutials.[29,30] In this line, our investigation was carried out to explore the curative effect of the extract of cactus *"Opuntia streptacantha »* to limit dermatosis photo-induced by comparing it with the curative effect of a pharmaceutical product: the methotrexate (MTX) in female mice of *"Mus musculus"*.

The daily exhibition of mice in the UV radiations led modifications at the level of some analyzed hepatic parameters. So our results show a significant rise of the activity of ALAT and ASAT to mice exposed 90 days to UV radiation with regard to controls (C). On the other hand, the ultraviolet irradiation also increased the plasmatic value of the LDH. This increase is highly significant at mice (UV) can be probably explained by a cellular lysis which diverse their contents in the blood.

To mice treated only in the cactus (CT); the plasmatic values in ASAT, ALAT and LDH is approaching to those obtained for controls (C), this confirms our previous results that the cactus has no unwanted effects. While the MTX administered only causes a remarkable increase of these three parameters.

Our results also agree with other works[27] which showed that the injection of the MTX to mice led a rise of the flight of enzymes LDH, ASAT and ALAT. On the contrary, the injection of the extract of cactus cladodes in mice exposed to UV (UVCT7, UVCT 15 and UVCT 30) shows significant variations for these three analyzed parameters, what confirms the beneficial and corrective aspect of a co-administration of the extract of this plant. We note well that more the duration of treatment by the extract of the cactus is long more the corrective effect is important.

These three parameters (LDH, ASAT and ALAT) register an approaching value to the normal for the group UVCT30 more than those obtained for the groups UVCT7 and UVCT15. Also to mice irradiated then treated by the MTX (UV MTX), our results show a decrease of the plasmatic rates of these parameters with regard to those irradiated (UV). Thus the MTX has a corrective effect of the damages led by the UV irradiations.

To complete our studies, we analyzed the impact of UV radiation on the serum glucose, cholesterol and triglycerides after 90 days of treatment. Indeed, the ultraviolet irradiation led an increase of the serum glucose and in parallel a decrease of the serum cholesterol and triglycerides.

According to our results, these plasmatic rates normalize with the co-administration of the extract of the cladodes of *Opuntia* especially for the group UVCT30 and for the group UVMTX by the co-administration of the MTX. While the MTX administered only led a significant increase of these three parameters (glucose, cholesterol and triglycerides).

We conclude that the modifications led by the irradiation on the hepatic and renal functions are notable and the most important damages are located at the level of the skin and more exactly at the level of ear.

Indeed, the cutaneous biopsy of the ears of mice irradiated (UV) highlighted anomalies in the various coats (layers) of the skin: At the level of the skin, the microscopic observation reveals a hyperkeratosis accompanied by an acanthosis, a vacuolization of the basal coat and a disorganization of cells with a cytonuclear anomalies: Pits are big sizes, deformed, atypical, and hyper chromatic. So, at the level of the dermis, we observe an important inflammatory infiltrate. These observations are in agreement with the results reported by some researches.[31,32,33] It has been reported that the chronic exposure of mice in the UVB radiations induced an increase of the thickness of the skin, and a reduction of their elasticity with damage of the fibers of keratin. Other studies also found that further to a chronic exposure of male mousse in the UVB radiations during 19 weeks with increasing frequencies every 3 weeks that the thickness of the skin and the extracellular matrix were appreciably increased.[22]

In the case of our studies, where the irradiation is associated with a treatment by the extract of cladodes of *Opuntia* by intraperitonial injection, the modifications reported at the level of the skincare reduced or even absent. The extract of the cactus administered during three weeks restored the normal tissular architecture of the skin of ear represented by a complete absence of hyperkeratosis, a decrease of acanthosis with absence of vacuolization of the basal coat, an improvement of the cytonuclear anomalies and a remarkable reduction in inflammatory infiltrate at the level of the dermis.

A works showed that further to a standard wound at the level of the backs of rats, the extract of *Opuntia ficus indica* applied to this place restored the organization of all the coats in the fifth day of the treatment.[34] So other works in this context showed that the topical application of extract of cladodes increases the cutaneous corrective effect which seemed accomplished at the end of week.[20] These results agree well with our and confirm that the extract of cladodes of *Opuntia* has a corrective effect of the cutaneous wounds.

Besides, other works showed that the exhibition of male mouses in the UV radiations led an increase of the thickness of the skin with a significant increase of the expression of the granules of melanin of the basal coat and that the extract of the medicinal plant « *Curcuma longa* » known under the name of 'saffron of India' reduced significantly these modifications.[22] We can conclude that the extract of this plant has a comparable effect to that of our plant on the harmful effects of the UV radiations.

On the other hand in our experimental conditions, we compared the curative effect of the extract of the cactus by the curative effect of the medicine: The methotrexate (MTX) to mice irradiated and treated by the MTX, the histology of the skin of ear showed a reduction in hyperkeratosis but less important than that obtained by

the treatment by the cactus, with decrease of the cytonuclear modifications and the decrease of acanthosis. These results confirm the corrective effect of the MTX of the photo-led hurts.

Conflict of interest

The authors declare that there is no conflict of interest.

ACKNOWLEDGMENTS

This research was funded by the Tunisian Ministry for Education, Scientific Research through the research of "Valorization of Active Biomolecules", Higher Institute of Applied Biology Medenine, Gabes University Tunisia.

REFERENCES

1. Yano K, Kajiya K, Ishikawa M, HongYK, Miyakawa T, Detmar M. Ultraviolet B-induced skin angiogenesis is associated with switch in the balance of vascular endothelial growth factor and thrombospondin-1 expression. J.Invest. Dermatol., 2004; (122): 201-208.
2. Boulais N, Misery L. The epidermis: a sensory tissue. Eur J Dermatol., 2008; (18): 119-127.
3. Ichihashi M, Ueda M, Budyanto A, Bito T, Oka, FukunagaM,Tsuru, Horikawa T. UV induced skin damage.Toxicolog., 2003; (189): 21-39.
4. Gibbons L, Anderson L. Actes du colloque sur les maladies associées aux rayons ultraviolets. Chronic Dis Can., 1992; (13): 11-13.
5. Kripke M. Ultraviolet radiation and immunology: something new under the sun. Cancer Res., 1994; (54): 6102-6105.
6. Saliou C, Rimbach G , Moini H, McLaughlin L , Hosseini S, Lee J, Watson R R, Packer L.Solar ultraviolet-induced erythema in human skin and nuclear factor-k-B-dependent gene expression in keratinocytes are modulated by a French maritime pine bark extract. Free Radic. Biol.Med., 2001; (30): 154-160.
7. Agar NS and Coll .The basal layer in human squamous tumor harbars more UVA than UVB mutation. A role for UVA in human skin carcinogenesis. Proc.Nat.Acad SCI. USA., 2004; (101): 49-59.
8. Bataille V, de Vries E .Melanoma--Part 1: Epidemiology, risk factors, and prevention.BMJ, 2008; (337): 22-49.
9. Thaipong K, Boonprakob U, Crosby K, Cisneros – Zevallos L, Byrne DH. Comparison of ABTS, DPPH, FRAP and ORAC assays for estimating antioxidant activity from guava fruits extracts. J Food Compos Anal., 2006; (19): 669-675.
10. El Kossori RL, Villaume C, El Boustani E, Sauvaire Y, Mejean L. Composition of pulp, skin and seeds of prickly pears fruit (*Opuntia ficus indica* sp.).Plant Foods Hum Nutr., 1998; (52): 263-270.
11. Lee J C, Lim KT, Jang YS. Identification of *Rhusverniciflua* stokes compounds that exhibit free radical scavenging and anti-apoptotic properties. BiochimBiophysActa., 2002; (1570): 181-191.
12. Reyes-Reyes M, Salazar-Montoya JA, Rodríguez-Páez LI, Ramos-Ramírez EG.In vitro fermentation of oligosaccharides obtained from enzymatic hydrolysis of Opuntia streptacantha mucilage. J Sci Food Agric., 2019 Apr; 99(6): 2883-2891. doi: 0.1002/jsfa.9501. Epub 2019 Jan 31.
13. Butera D, Tesoriere L, Gaudio DF, Bongiorno A, Allegra M, Pintaudi AM. Antioxidant activities of Sicilian prickly pear *(Opuntia ficus indica)* fruit extracts and reducing properties of its betalains: betanin and indicaxanthin. J Agric Food Chem., 2002; (50): 6895-6901.
14. Felker P, Del S, Rodriguez C. Comparison of *Opuntia ficus indica* varieties of Mexican and Argentine origin for fruit yield and quality in Argentina. J. Arid Environ., 2005; (60): 405-422.
15. Tesoriere L, Fazzari M, Allegra M, Livrea MA. Biothiols, taurine and lipid soluble antioxidants in the edible pulp of Sicilian cactus pear *(Opuntia ficus indica)* fruits and changes of bioactive juice components upon industrial processing. J Agric Food Chem., 2005; (53): 7851-7855.
16. González-Ponce HA, Martínez-Saldaña MC, Rincón-Sánchez AR, Sumaya-Martínez MT, Buist-Homan M, Faber KN, Moshage H, Jaramillo-Juárez F.Hepatoprotective Effect of Opuntia robusta and Opuntia streptacantha Fruits against Acetaminophen-Induced Acute Liver Damage. Nutrients. 2016 Oct 4; 8(10).
17. Bedi MK, Shenefelt PD. Herbal therapy in dermatology. Arch Dermatol., 2002; (138): 232-242.
18. Galati EM, Monforte MT, Tripodo MM , D'Aquino A, Mondello MR .Antiulcer activity of *Opuntia ficus indica* (L.) Mill. (Cactaceae):Ultrastructural study. J Ethnopharmacol., 2001; (76): 1-9.
19. Park EH., Chun MJ .Wound healing of *Opuntia ficus indica*. Fitoterapia., 2001; (72): 165-167.
20. Trombetta D, Puglia C, Perri D, Licata A, Pergolizzi S, Lauriano E R, De Pasquale A, Saija A, Bonina F P. Effect of polysaccharides from *Opuntia ficus indica* (L.) cladodes on the healing of dermal wounds in the rat. Phytomedecine, 2006; (13): 352-358.
21. Cho HS, Lee MH, Lee JW, No KO, Park SK, Lee HS, Kang S, Cho WG, Park HJ, Oh KW, Hong JT. Anti wrinkling effects of the mixture of vitamin C, vitamin E, pycnogenol and evening primrose oil, and molecular mechanisms on hairless mouse skin causes by chronic ultraviolet B irradiation. Photodermatol. Photoimmunol. Photomed., 2007; (23): 155-162.
22. Maho Sumiyoshi, Yoshiyuki Kimura. Effects of a turmeric extract (*Curcuma longa*) on chronic ultraviolet B irradiation-induced skin damage in melanin-possessing hairless mice. Phytomedecine, 2009; (16): 1137-1143.
23. Strickland F M. Immune regulation by polysaccharides: implications for skin cancer. J Photochem Photobiol B: Biol., 2001; (63): 132-140.

24. Zou DM, Brewer M, Garcia F, Feugang JM , Wang J, Zang R, Lieu H, Zou CP. Cactus cladodes pear- a natural product in cancer chemoprotection. Nutrition 2005; J4.
25. Kuti J O. Antioxidant compounds from four *Opuntia* cactus pear fruit varieties. Food Chem., 2004; (85): 527-533.
26. Park SH, Kim H, Rhyu DY. Flavonoids from the stems of eastern prickly pear *Opuntia humifusa*, Cactaceae. J Biol Chem., 2007; (50): 254-258.
27. Walker TM, Rhodes P C, West morelandC. The differential cytotoxicity of MTX in rat hepatocyte monolayer and spheroid cultures. Photochem Photobiol., 2000; (63): 406-410.
28. Clayden EC. Practical section cutting and staining. Churchill Livingstone, Edinburgh 1971.
29. Zourgui L, Ayed-Boussema I, Ayed Y, Bacha H, HassenW. The antigenotoxic activities of cactus (*Opuntia ficus indica)* cladodes against the mycotoxin zearalenone in Balb/c mice: prevention of micronuclei, chromosome aberrations and DNA fragmentation. Food ChemToxicol., 2009; (47): 662-667.
30. Salama SM, Abdulla MA, AlRashdi AS, Ismael S, Alkiyumi SS, GolbabapourS. Hepatoprotective effect of ethanolic extract of *Curcuma longa* onthioacetamide induced liver cirrhosis in rats. BMC Complement Altern Med., 2013; (13): 5-6.
31. Sams WM, Smith J. The histochemistry of chronically sun damaged skin.J.Invest.Dermatol., 1961; (37): 447-452.
32. Smith J, Daridson E A, Sams WM, Clark RD. Alterations in human dermatol connective tissue with age and chronic sun damage. J. Invest. Dermatol., 1962; (39): 345-350.
33. Uitto J, Fazio MJ, Olsen DR. Molecular mechanisms of cutaneous aging. Age-associated connective tissue alterations in the dermis. J. An.Acad. Dermatol., 1989; (21): 614-622.
34. Enza Maria Galati, Maria Rita Mondello, Maria Teresa Monforte, Mariangela Galluzzo, NataliziaMiceli, Maria Marcella Tripodo. Effect of Opuntiaficus-indica (L.) Mill. Cladodes in the Wound-Healing Process, 2003; 5: 1-16.